

# Vitality of the slipped capital femoral epiphysis

## Preoperative evaluation by tetracycline labeling

In 25 cases with 29 slipped capital femoral epiphyses, treated with bilateral pinning, tetracycline was administrated preoperatively. Biopsies from the femoral head and the trochanteric region were analyzed by fluorescence microscopy. All had normal tetracycline labeling except the only patient with an acute severe slip.

**Gunnar Hägglund**  
**Lars Ingvar Hansson<sup>1</sup>**  
**Gunnar Ordeberg**

Departments of Orthopaedics, Lund University Hospital, S-221 85 Lund, and <sup>1</sup>Umeå University Hospital, Umeå, Sweden

Vascular disturbance of the slipped capital femoral epiphysis (physiolysis colli femoris – PCF) is a considerable factor predisposing to arthrosis (Jerre 1950, Hägglund et al. 1985). This impairment is generally regarded as a complication of the treatment procedure (Hall 1957, Lowe 1961, Hägglund et al. 1985), but there is also evidence that the slipping itself can influence the vascular supply to the bony epiphysis (Moore 1945).

We administered tetracycline preoperatively, and analyzed biopsies in a consecutive series of PCF operated with bilateral pinning.

### Patients and methods

The material consisted of 25 cases (19 boys and 6 girls) with PCF, treated at the Orthopaedic Department in Lund in 1977-1982. The mean age at operation was 13 (7.5-15) years in boys and 12 (11-13) years in girls. Four cases had bilateral slipping; consequently, 29 slipped hips were evaluated. The de-

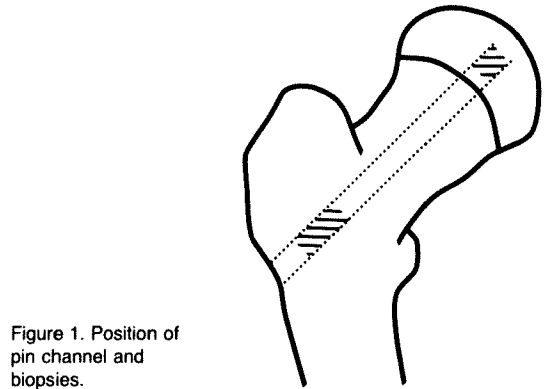


Figure 1. Position of pin channel and biopsies.

gree of slipping was classified according to Bianco (1966), (Table 1). In two hips the slipping was asymptomatic, and three hips had acute slipping.

The patients received 500-1000 mg Tetracycline® (one patient 400 mg Vibramycin®) orally in two equal doses with a 6-12 h interval, 1-19 days before the operation. All were operated bilaterally with the Hansson (1982) hook-pin. Biopsies were taken from the pin-channel centrally in the femoral epiphysis (Figure 1); the tetracycline labeling in these biopsies has earlier been shown to correspond well to the labeling of the entire femoral head (Strömqvist et al. 1981). Biopsies were also, when possible, taken from the trochanteric region.

The biopsy specimens were fixed and dehydrated in ethyl alcohol (Hansson 1967) and embedded undecalcified in methyl-methacrylate (Ahlgren 1968). They were sectioned (Isomet®) into 3-5 sections of about 75 µm thickness. The sections were examined under reflected light with a Leitz Orthoplan fluorescence microscope. The occurrence of yellow tetra-

Table 1. Length of anamnesis related to degree of slipping according to Bianco (1966)

Time (months)	Slipping (no. of hips)		
	Mild	Moderate	Severe
Asymptomatic	2		
<1	2		1
1-3	7	1	
3-6	5	1	
>6	1	5	4

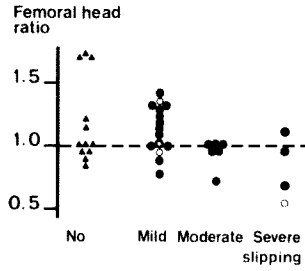
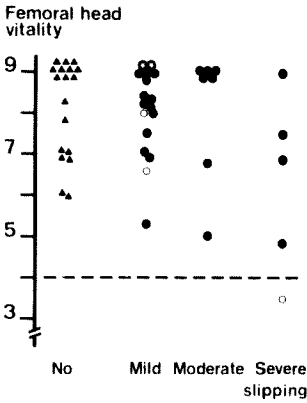


Figure 2. Vitality in 29 slipped capital femoral epiphyses in relation to degree of slipping. For comparison, to the left, vitality in 18 unslipped capital femoral epiphyses.  $\blacktriangle$  = no slipping;  $\bullet$  = asymptomatic slipping;  $\odot$  =  $< 1$ ,  $\bullet$  =  $> 1$  month between onset of symptoms and diagnosis.

Figure 3. Femoral head ratio. Tetracycline uptake ratio slipped epiphysis/trochanteric region or slipped epiphysis/contralateral unslipped epiphysis in 25 hips in relation to degree of slipping. For comparison, to the left, femoral head ratio in 12 unslipped epiphyses. Same symbols as in Figure 2.

cycline on the bony trabecular surface was analyzed. The distribution and intensity in each section was recorded, and a mean value was calculated for each specimen. The distribution was classified into one of the following categories: 3 = tetracycline labeling throughout the sections, 2 = tetracycline labeling on multiple locations in the sections, 1 = tetracycline labeling locally in the sections, 0 = absent or doubtful tetracycline labeling in the sections. The fluorescence intensity was then classified into one of the following categories: 3 = intensive, 2 = moderate, 1 = poor, 0 = none. The vitality was defined as the distribution multiplied by the intensity.

The fluorescence was analyzed in all 29 slipped epiphyses, and in 18 unslipped epiphyses. In three unslipped hips, no epiphyseal biopsy was available.

In four cases out of 25, fluorescence from previous deposition of tetracycline was noted. This deposition was located underneath the bony trabecular surface, with normal and autofluorescent bone between the previous and the new tetracycline deposition.

The ratios of the epiphysis/trochanteric or (when no trochanteric biopsy was available) slipped epiphysis/contralateral intact epiphysis was calculated in 25 slipped hips, and in 12 unslipped hips. In two boys with bilateral slipping no trochanteric biopsy was available. In nine unslipped hips there was a lack of either epiphyseal or trochanteric biopsy due to technical difficulties.

**Results**

In the unslipped hips the distribution and intensity in the biopsies from the femoral head was above 4.0 (Figure 2) and very similar to the fluorescence in the trochanteric area (Figure 3). In 28 of the 29 slipped hips the distribu-

tion and the intensity of tetracycline fluorescence in all biopsies from the femoral head exceeded 4.0 (Figure 2), indicating satisfactory preoperative vitality of the bony epiphysis. In all cases with normal tetracycline fluorescence, there was also a normal development of the femoral epiphysis.

Though all but one biopsy had a normal fluorescence, there was a slight drop in the ratio between slipped epiphysis and trochanteric region or contralateral unslipped epiphysis with degree of slipping (Figure 3).

In all biopsies the tetracycline fluorescence was very regular on the bony trabecular surface. No biopsy had an irregular fluorescence in patches, as seen during revascularization secondary to avascularity (Strömqvist et al. 1984).

In the only case with acute severe slipping, there was a reduced fluorescence in the femoral head (Figure 2), suggesting vascular disturbance. This boy, aged 7 years, fell from a horse and immediately suffered from severe pain in his left hip. However, during the preceding week he had complained of mild pain in the same hip. He was treated with tibial pin traction according to Casey et al. (1972), without significant reduction. At operation under general anesthesia 3 days later, there was a spontaneous reduction on the operating table. At reexaminations 2-4 years after the operation, there was a minor flattening of the femoral head, indicating an impairment in the growth of the bony epiphysis.

## Discussion

During adolescence, the bony epiphysis receives its blood supply mainly from vessels in the capsula reflexa (Trueta 1957, Hulth 1958), but also from the ligamentum teres. Damage to the capsular vessels, resulting in osteonecrosis, could theoretically occur during slipping, during reduction and/or during surgery. Earlier investigations have demonstrated an increased risk of segmental collapse after closed reduction, compared with no or unsuccessful reduction (Jerre 1950, Lowe 1961). There is also a higher frequency of segmental collapse after femoral neck osteotomy compared with osteotomy at the trochanteric/subtrochanteric level (Southwick 1973) or at the basis of the femoral neck (Kramer et al. 1976).

Cases treated with osteotomy or closed reduction generally have severe slipping. Irrespective of etiology, segmental collapse is highly correlated to early development of arthrosis (Jerre 1950, Hägglund et al. 1985).

In this investigation, the vitality of the capital femoral epiphysis was investigated before reduction and before pinning. The preoperative vitality was found normal in all but one case, the only patient in the material with acute severe slipping.

This investigation demonstrates that in most cases of PCF, the vascular supply to the bony epiphysis is normal preoperatively. This confirms that necrosis of the bony epiphysis is probably mostly caused by vascular injuries during reduction or surgery, as previously mentioned by Jerre (1950), Hall (1957), Lowe (1961) and Hansson (1982).

## References

- Ahlgren, S.-A. (1968) Rate of apposition of dentine in upper incisors in normal and hormone-treated rats. *Acta Orthop. Scand.* Suppl. 116.
- Bianco, A. J., Jr. (1966) Treatment of slipping of the capital femoral epiphysis. *Clin. Orthop.* **48**, 103–110.
- Casey, B. H., Hamilton, H. W. & Bobechko, W. P. (1972) Reduction of acutely slipped upper femoral epiphysis. *J. Bone Joint Surg.* **54-B**, 607–614.
- Hägglund, G., Hansson, L. I., Ordeberg, G. & Sandström, S. (1985) Slipped capital femoral epiphysis in southern Sweden. Long-term results after femoral neck osteotomy. *Clin. Orthop.* (in press).
- Hall, J. E. (1957) The results of treatment of slipped femoral epiphysis. *J. Bone Joint Surg.* **39-B**, 659–673.
- Hansson, L. I. (1967) Daily growth in length of diaphysis measured by oxytetracycline in rabbit normally and after medullary plugging. *Acta Orthop. Scand.* Suppl. 101.
- Hansson, L. I. (1982) Osteosynthesis with the hook-pin in slipped capital femoral epiphysis. *Acta Orthop. Scand.* **53**, 87–96.
- Hulth, A. (1958) The vessel anatomy of the upper femur end with special regard to the mechanism of origin of different vascular disorders. *Acta Orthop. Scand.* **27**, 192–209.
- Jerre, T. (1950) A study in slipped capital femoral epiphysis. *Acta Orthop. Scand.* Suppl. 6.
- Kramer, W. G., Craig, W. A. & Noel, S. (1976) Compensating osteotomy at the base of the femoral neck for slipped capital femoral epiphysis. *J. Bone Joint Surg.* **58-A**, 796–800.
- Lowe, H. G. (1961) Avascular necrosis after slipping of the upper femoral epiphysis. *J. Bone Joint Surg.* **43-B**, 688–699.
- Moore, R. D. (1945) Conservative management of adolescent slipping of the capital femoral epiphysis. *Surg. Gynecol. Obstet.* **80**, 324–332.
- Southwick, W. O. (1973) Compression fixation after biplane intertrochanteric osteotomy for slipped capital femoral epiphysis. *J. Bone Joint Surg.* **55-A**, 1218–1224.
- Strömquist, B., Ceder, L., Hansson, L. I. & Thorngren, K. G. (1981) Vitality of the femoral head after femoral neck fracture evaluated by tetracycline labeling. *Arch. Orthop. Traumat. Surg.* **99**, 1–6.
- Strömquist, B., Hansson, L. I., Palmer, J. & Thorngren, K. G. (1984) Femoral head vitality at reoperation for femoral neck fracture complications. *Arch. Orthop. Traumat. Surg.* **103**, 235–240.
- Trueta, J. (1957) The normal vascular anatomy of the human femoral head during growth. *J. Bone Joint Surg.* **39-B**, 358–394.