

Radiographic diagnosis of biceps tendinitis

The radiographic findings and arthrographic image of the intertubercular groove and the biceps tendon were analysed in 143 patients with chronic shoulder pain. Forty-eight patients had been operated on, and of these 33 had tendinitis, caused by attrition in a narrow intertubercular groove in 17 cases, by medial dislocation of the biceps tendon in 11 cases, and by impingement associated with rupture of the rotator cuff in five cases.

Plain radiographs revealed degenerative changes in the walls of the groove in half of the patients with biceps tendinitis. A shallow groove was seen in cases of medial dislocation of the biceps tendon, but also in many with a normal tendon. The arthrogram, however, showed whether a shallow groove was associated with dislocation of the tendon. In patients with attrition tendinitis the groove had a depth of 4.8 mm or more or an inclination of the medial wall of 58° or more.

Radiographic measurements of the dimensions of the intertubercular groove may provide valuable information on the state of the biceps tendon.

Chronic shoulder pain may be attributable to disorders of the biceps tendon (Meyer 1926, Abbott & Saunders 1939, Hitchcock & Bechtol 1948, Slätis & Aalto 1979). However, there have been few reports on the radiographic appearance of the intertubercular groove of the humerus in different pathological conditions. In anatomical specimens, Hitchcock & Bechtol (1948) found that in almost all cases the inclination of the medial wall exceeded 45°. Cone et al. (1983) made corresponding measurements on radiographs of anatomical specimens, and found a mean inclination of the medial wall of 56° (25°-90°).

DePalma (1973) and Neviasser (1980) considered a slanting medial wall associated with a shallow intertubercular groove to be a factor predisposing to medial dislocation of the biceps tendon. There are no accurate data, however, on the dimensions of the intertubercular groove in dislocation of the biceps tendon or in other pathological conditions of the groove and the tendon.

Shoulder arthrography, although not infallible, can provide some information on the state of the biceps tendon. First, dislocation of the tendon may be seen in the groove view if the sheath of the tendon is accurately filled with contrast medium (Goldman & Ghelman 1978, Neviasser 1980, Resnick 1981). Second, in bi-

ceps tendinitis there may be loss of sharp delineation of the tendon (Goldman & Ghelman 1978). Third, in rheumatoid arthritis irregularities in the sheath of the biceps tendon may have been caused by synovitis (Ennevaara 1967).

The aim of our study was to measure the dimensions of the intertubercular groove in plain radiographs and to assess the radiographic features of the biceps tendon in arthrograms of patients with chronic shoulder pain. The radiographic features were compared with the surgical observations in the patients subsequently operated on.

Patients and methods

The study included 143 patients from the Shoulder Service and the Department of Radiology of the Surgical Hospital of Helsinki. There were 89 men and 54 women with mean age 47 (17-78) years.

Plain radiography included 40° posterior oblique views of the shoulder joint in standing patients with the humerus rotated inwards and outwards; the central beam was 15° (Goldman & Ghelman 1978) above the horizontal. Axillary films (Clark 1973) and groove radiographs (Ahovuo 1983) were taken with the patients in the supine position.

For arthrography the glenohumeral joint was punctured anteriorly (Killoran et al. 1968). In single-contrast arthrograms sodium meglumine with an io-

Juhani Ahovuo
Pekka Paavolainen¹
Pär Slätis¹

Department of Radiology,
and ¹Division of Orthopaedic
Surgery and Traumatology,
Surgical Hospital, Helsinki
University Central Hospital,
Kasarmikatu 11-13, 00130
Helsinki 13, Finland

dine concentration of 200 mg/ml was injected until the patient felt a sensation of maximum fullness in the joint. There were also 41 double-contrast arthrograms in this study, and the liquid contrast medium was injected until the patient felt the first sensation of joint filling, followed by inflation of oxygen with a syringe until the patient reported a sensation of maximum fullness in the joint. The projections were the same as in the plain radiographs. The shoulder joint was not exercised after the injection.

The depth and width of the groove and the inclination of its medial wall were measured from the plain radiographs as described by Ahovuo (1983).

Forty-eight patients were operated on. The diagnosis of biceps tendinitis at surgery was based on one or several of the following criteria: synovial thickening with granulation tissue and oedema of the tendon, wear and fraying of the tendon, medial dislocation of the tendon, and complete rupture of the tendon.

The radiographic findings were analysed and correlated with the observations made at surgery. The significance of the differences in results was determined by t- and chi-square tests. A significance level of 5 per cent was chosen.

Results

At surgery the diagnosis of biceps tendinitis was confirmed in 33 of the 48 patients. In 17 of these the tendon lay in its groove, but there was a discrepancy between the thickness of the tendon and the width of the groove, which was too narrow (attrition tendinitis). In a further 11 patients the rotator cuff was ruptured through the medial portion of the coracohu-

meral ligament, and the biceps tendon was displaced medially, so that it was riding on the lesser tuberosity (dislocation tendinitis). Finally, in five patients the rotator cuff was torn, causing compression of the intra-articular portion of the biceps tendon against the coracoacromial roof above (impingement tendinitis). In 15 of the patients operated on, both the intertubercular groove and the biceps tendon were normal.

The results of the radiographic analysis of the intertubercular groove and the biceps tendon in patients with chronic shoulder pain are compiled in Table 1. Degenerative changes in the walls of the groove were visible in 18 of the 33 patients with surgically verified biceps tendinitis. Every intertubercular groove judged to be normal at surgery had a normal appearance in the radiographs also.

Parameters of the radiographic image of the intertubercular groove in the 48 patients operated on are summarized in Table 2 and in Figures 1 and 2. The findings were statistically abnormal only in patients with attrition tendinitis.

Table 1. Radiographic appearance of the intertubercular groove of the humerus in 140 patients with chronic shoulder pain

	Measured value mean (range) SD
Depth of the groove (mm)	4.1 (2.0– 6.6) 1.0
Width of the groove (mm)	13.0 (7.4–22.2) 2.4
Width-to-depth ratio	3.4 (1.7–11.1) 1.4
Inclination of the medial wall (°)	43.3 (13–78) 14.1

Table 2. Radiographic measurements of the intertubercular groove in 48 cases operated for chronic shoulder pain. Mean (range) SD.

	Surgical observation			
	Attrition tendinitis N=17	Biceps tendon dislocation N=11	Impingement on biceps tendon N=5	Normal biceps tendon ^a N=15
Depth (mm)	4.8 (2.4– 6.6) 1.0*	3.3 (2.6– 4.2) 0.5	4.2 (3.4– 5.6) 0.8	3.9 (2.0– 5.2) 0.9
Width (mm)	12.7 (10.0–15.4) 1.7***	13.5 (8.2–17.8) 2.3	12.6 (10.2–15.0) 1.8	15.0 (11.0–18.0) 2.0
Width-to-depth ratio	2.8 (2.1– 6.3) 1.0**	4.1 (3.2– 5.0) 0.6	3.0 (2.1– 3.9) 0.8	4.2 (2.3– 9.0) 1.7
Inclination of the medial wall (°)	58.5 (34 –70) 10.8***	35.6 (15–52) 11.1	50.8 (42 –66) 11.5	43.0 (20 –66) 13.1

Statistical difference compared with normal surgical observations: * P < 0.02, ** P < 0.01, *** P < 0.005

^a In symptom-free control shoulder joints, the depth of the groove was 4.5, SD 0.8 mm, width 12.0, SD 2.1 mm, and the inclination of the medial wall 48.1, SD 10.7° (Ahovuo 1983).

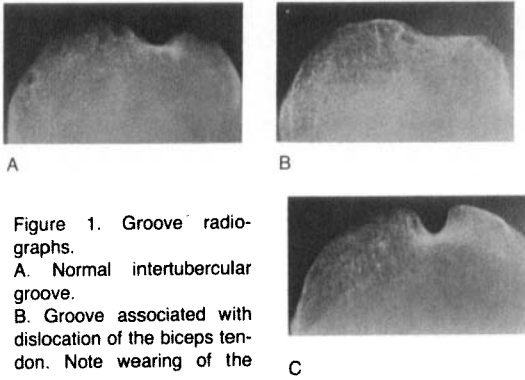


Figure 1. Groove radiographs.

A. Normal intertubercular groove.

B. Groove associated with dislocation of the biceps tendon. Note wearing of the groove.

C. Groove in attrition tendinitis. The groove is deep and narrow. All these findings were confirmed at surgery.

The depth, width and inclination of the medial wall of the groove did not differ between patients operated and not operated.

In only 97 arthrograms was the biceps tendon visible in the groove view. The arthrograms showed no difference in the filling of the tendon sheath between the patients with surgically verified biceps tendinitis and those with a normal tendon.

In 9 of the 11 patients with a dislocated biceps tendon arthrography revealed the medial displacement of the tendon. In arthrography of the patients with attrition tendinitis the groove view gave the impression that the biceps tendon was located deep in the groove, surrounded by bony excrescences (Figure 3).

Discussion

Attempts to discover the source of intractable shoulder pain through surgery have been ham-

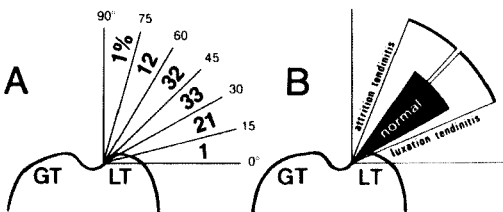


Figure 2. Schematic representation of measurements of the inclination of the medial wall of the groove.

A. Frequency distribution of the results obtained from 140 radiographs.

B. Range of degree of the inclination of the medial wall (mean \pm SD) measured from the patients operated on. Note overlapping of the values for the normal groove with those for attrition and luxation or dislocation tendinitis.

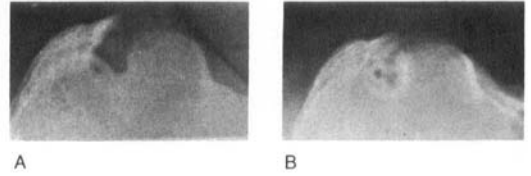


Figure 3. Arthrogram of attrition tendinitis of the biceps. A. Plain groove film with a large lateral osteophyte. B. Groove arthrogram with the tendon sheath filled with contrast medium.

pered by lack of information on the pathology of the shoulder joint and by inconclusive pre-operative methods of examination. For anatomical reasons shoulder pain may often be connected with pathological changes in the tendon of the long head of the biceps brachii (Slätis & Aalto 1979, Paavolainen et al. 1984).

Three pathological conditions have been found associated with biceps tendinitis. First, in tears of the anterior part of the rotator cuff the biceps tendon may be compressed against the coracoacromial roof above (Neer 1972). Second, the tendon may become worn and frayed in a narrow, or even tunnel-shaped, intertubercular groove (Paavolainen et al. 1984). Third, the biceps tendon may be displaced medially owing to a tear in the stabilizing coracohumeral ligament (Slätis & Aalto 1979).

Our present knowledge of the pathological conditions of the biceps tendon and the intertubercular groove are based on anatomical or surgical observations (Hitchcock & Bechtol 1948, Slätis & Aalto 1979). There are few diagnostic tools for the pre-operative verification of such changes.

In the pre-operative radiographic diagnosis of biceps tendinitis attention has been paid to the presence of osteophytes and irregularities in the walls of the intertubercular groove (Hitchcock & Bechtol 1948). However, the absence of these changes does not rule out tendinitis (Hitchcock & Bechtol 1948, Simon 1975), as was confirmed in the present study. Although radiographs revealed degenerative changes in the walls of the groove in half of the patients with tendinitis, these changes were not specific for any type of tendinitis. No such alterations were to be seen, however, in groove films of the patients in whom a normal intertubercular groove was verified at surgery.

In their radiographic measurements of the intertubercular groove on anatomical specimens and on patients, Cone et al. (1983) found that the mean inclination of the medial wall was 56° and 48°, respectively. Correspondingly, Ahovuo (1983) obtained a mean inclination of 52° in six anatomical specimens and of 48° in 30 symptom-free people. In their measurements on anatomical specimens, Hitchcock & Bechtol (1948) found that in almost all cases the inclination exceeded 45°. Taken with the mean inclination of 43° obtained from measurements on the radiographs of our patients with chronic shoulder pain, these figures allow two conclusions: first, the inclination of the medial wall does not differ between symptom-free and painful joints, and second, Hitchcock & Bechtol (1948) apparently made their measurements with a technique different from that used by Ahovuo (1983) or Cone et al. (1983).

In the present series, radiographic measurements of the groove showed that in the patients with surgically verified dislocation of the biceps tendon the inclination of the medial wall did not differ from that of the patients with a normal tendon. Similarly, measurements of the depth of the groove from the radiographs did not reveal any differences between patients with a normal and with a dislocated tendon. At surgery dislocation of the biceps tendon could be observed only in patients with a rupture of the medial portion of the coracohumeral ligament (Slätis & Aalto 1979, Paavolainen et al. 1984). Whether or not a shallow groove seen in plain films was associated with dislocation of the biceps tendon, could be seen from the preoperative arthrograms.

In the patients with surgically verified attrition tendinitis of the biceps, the intertubercular groove was deeper (mean 4.8 mm) and the medial wall steeper (mean 58°) than in the patients with a normal tendon. Such values obtained from radiographic measurements of the groove associated with the typical arthrographic appearance of a biceps tendon tightly enclosed in its groove may be a valuable diagnostic sign of attrition tendinitis.

References

- Abbott, L. C. & Saunders, J. B. de CM. (1939) Acute traumatic dislocation of the biceps tendon of the long head of the biceps brachii. A report of six cases with operative findings. *Surgery* **6**, 817–840.
- Ahovuo, J. (1983) The radiographic anatomy of the intertubercular groove of the humerus. *Eur. J. Radiol.*, In press.
- Clark, K. C. (1973) *Positioning in radiography*, Vol. 1, 9th ed., p. 51. Illford Limited William Heinemann Medical Books Ltd., London.
- Cone, R. O., Danzig, L., Resnick, D. & Goldman, A. B. (1983) The bicipital groove: radiographic, anatomic, and pathologic study. *Am. J. Roentgenol.* **41**, 781–788.
- DePalma, A. F. (1973) *Surgery of the shoulder*. 2nd ed., pp. 450–453. J. B. Lippincott Company, Philadelphia, Toronto.
- Ennevaara, K. (1967) Painful shoulder joint in rheumatoid arthritis: Clinical and radiologic study of 200 cases with special reference to arthrography of the glenohumeral joint. *Acta Rheumatol. Scand. Suppl.* **2**, 11–116.
- Goldman, A. B. & Ghelman, B. (1978) The double-contrast shoulder arthrogram. A review of 158 studies. *Radiology* **127**, 658–663.
- Hitchcock, H. H. & Bechtol, C. O. (1948) Painful shoulder. Observation on the role of the tendon of the long head of the biceps brachii in its causation. *J. Bone Joint Surg.* **30-A**, 263–273.
- Killoran, P. J., Marcove, R. L. & Freiburger, R. H. (1968) Shoulder arthrography. *Am. J. Roentgenol.* **103**, 658–668.
- Meyer, A. W. (1926) Spontaneous dislocation of the tendon of the long head of the biceps brachii. Report of four cases. *Arch. Surg.* **13**, 109–119.
- Neer, C. S. II (1972) Anterior acromioplasty for the chronic impingement syndrome in the shoulder. A preliminary report. *J. Bone Joint Surg.* **54-A**, 41–50.
- Neviaser, R. J. (1980) Lesions of the biceps and tendinitis of the shoulder. *Orthop. Clin. North Am.* **11**, 343–348.
- Paavolainen, P., Slätis, P. & Aalto, K. (1984) Surgical pathology in chronic shoulder pain. *Surgery of the shoulder*, (Eds. Bateman, J. E. & Welsh, R. P.) B. C. Decker, Philadelphia, Toronto. In press.
- Resnick, D. (1981) Shoulder arthrography. *Radiol. Clin. North Am.* **19**, 243–253.
- Simon, W. H. (1975) Soft tissue disorders of the shoulder. Frozen shoulder, calcific tendinitis, and bicipital tendinitis. *Orthop. Clin. North Am.* **6**, 521–538.
- Slätis, P. & Aalto, K. (1979) Medial dislocation of the tendon of the long head of the biceps brachii. *Acta Orthop. Scand.* **50**, 73–77.