

Resection for macrodactylism of toes

Report of three cases

Three cases of macrodactylism of toes were operated on with a V-shaped resection: the toe, approximately two thirds of the metatarsals, and part of the adjacent interosseous muscles were resected. The cosmetic and functional results were good.

Lars G. Danielsson

University of Lund, Department of Orthopedics at Malmö General Hospital, S-214 01 Malmö, Sweden

True macrodactylism with disproportional growth of all elements of the affected toe is extremely rare (Barsky 1967, Dennyson et al. 1977) and less common than in fingers. The second toe is most commonly affected, sometimes in combination with the third or first toe, and associated syndactylism or polydactylism may occur. Most reports indicate a slight male preponderance, and racial differences have been reported (Ofodile 1980).

Surgery is indicated for cosmetic reasons, to make fitting of shoes easier, or to relieve pain. Amputation or exarticulation (Du Vries 1973, Dennyson et al. 1977), soft-tissue exarticulation, and excision of the proximal part of the middle phalanx in combination with syndactylizing the deformed toe to the adjacent toes

(Kelikian 1965) have been recommended; further, phalangeal or metatarsal growth arrest or osteotomy (Jahss 1982), and two-stage resection (Tsuge 1967).

Unfortunately, the final appearance after these operations is not cosmetically satisfactory. The defatted syndactylized toe residua are frequently bulky and ugly, and amputation may give rise to varus or valgus deformity of the adjacent toes. Also pain secondary to residual macrodactylism of the toe or the metatarsal or shoe problems due to the hypertrophy of the forefoot may be problematic.

In an attempt to diminish the above-mentioned problems, we used a V-shaped resection, including most of the metatarsal.

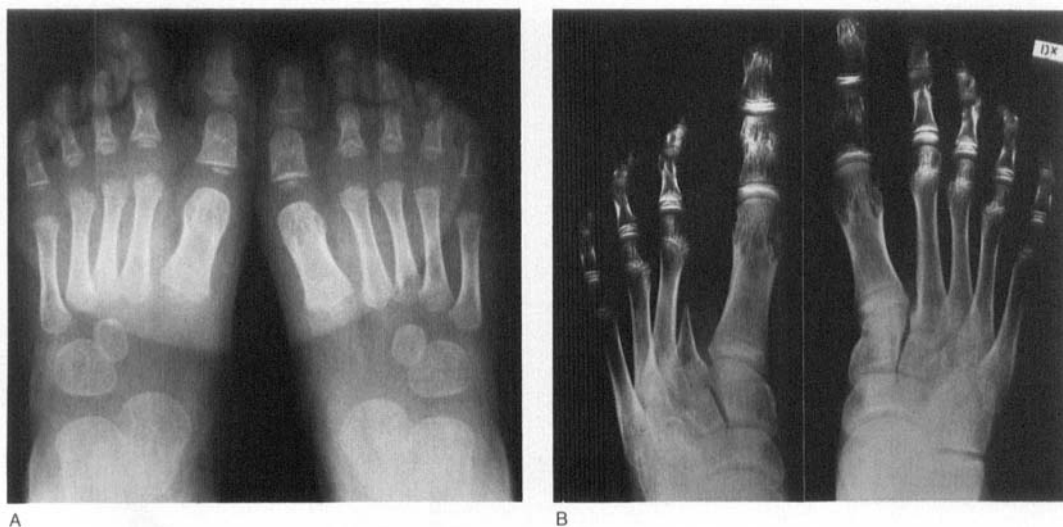

Figure 1. Girl with macrodactyly of the second toe. A. Preoperatively at age 1 year and 8 months. B. Seven years after the operation.

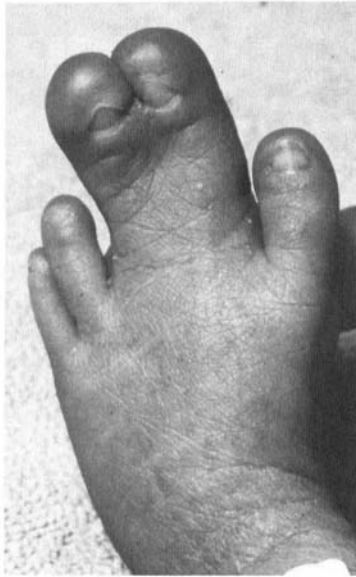
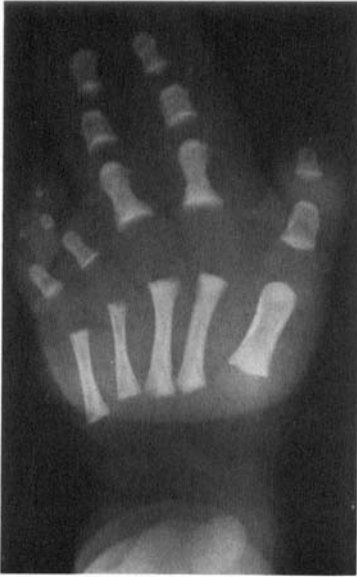

Figure 2. Boy with macroductylism of the second and third toes, hypertrophy of the second and third metatarsals and forefoot involvement.

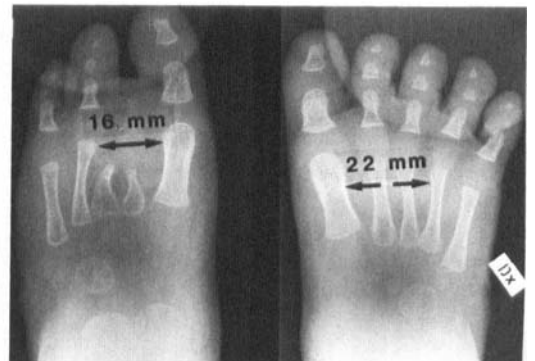
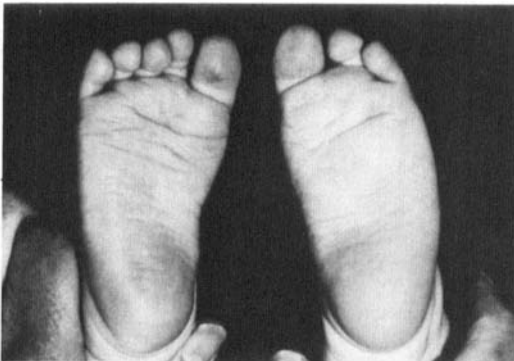
A. Preoperatively at age one month.

Cases

Three children, aged 1 month to 3 years, were treated for macroductylism of toes. The second toe was affected in all cases. In one child the third toe was also involved, and there was remarkable hypertrophy of the second and third metatarsals and an excessive accumulation of fibrofatty tissue, especially on the plantar part of the forefoot. All 3 children were operated on with the same V-shaped resection. The observation times were 7 and 2 years, and 8 months.

Under general anesthesia, using a tourniquet, a V-shaped dorsal and a V-shaped plantar incision were connected interdigitally. The anatomic structures were carefully identified, after which the vessels

were ligated and sectioned and the nerves and tendons to the toe were sectioned as proximately as possible. The toe and approximately two thirds of the metatarsal and part of the adjacent interosseous muscles were resected. The adductor hallucis tendon, if sectioned, and the transverse metatarsal ligament and the skin were then sutured. Pieces of fine-mesh nonadhesive gauze were applied between all the toes. The forefoot was then enclosed in fluffed porous gauze and an elastic bandage. Two weeks later, the stitches were removed and the parents of the children were advised about the use of an elastic forefoot bandage for 1 month. The elastic forefoot bandage was then to be used as a night bandage for at least 6 months.



B. Eight months after the operation. The distance between the first and fourth metatarsal has narrowed on the operated side when compared with the non operated side.

Results

The cosmetic and functional results were good (Figures 1 and 2). The distance between the first and the adjacent metatarsal was narrowed after the metatarsal resection.

Discussion

A V-shaped resection appears to give a better cosmetic and functional result than previously recommended methods. A supplementary syndactylizing operation was not required. If necessary, further reduction of plantar fibrofatty tissue can be performed. The operation is recommended in cases of macrodactylism of one or two of the middle toes. Two adjacent central toes can be resected simultaneously.

References

- Barsky, A. J. (1967) Macrodactyly. *J. Bone Joint Surg.* **49-A**, 1255–1266.
- Dennyson, W. G., Bear, J. N. & Bhoola, K. D. (1977) Macrodactyly in the foot. *J. Bone Joint Surg.* **59-B**, 355–359.
- Du Vries, H. L. (1973) *Surgery of the foot*. C. V. Mosby Company, St. Louis.
- Jahss, M. H. (1982) *Disorders of the foot*. W. B. Saunders Company, London.
- Kelikian, H. (1965) Hallux valgus, allied deformities of the forefoot and metatarsalgia. W. B. Saunders Company, London.
- Ofodile, F. A. (1980) Racial differences in macrodactyly. *Plast. Reconstr. Surgery* **66**, 792–793.
- Tsuge, K. (1967) Treatment of macrodactyly. *Plast. Reconstr. Surg.* **39**, 590–599.