

Improved operations for femoral neck fracture

A radiographic evaluation

A radiographic investigation was undertaken to determine whether an increased interest in femoral neck fractures improved the operative result. In 1977, all femoral neck fractures were operated on by any of 30 surgeons of the orthopedic department, but in 1981 all fractures were operated on by one of six specially devoted surgeons. Preoperative fracture classification was performed with three parameters and proved equal in the 1977 and 1981 groups of 105 and 114 fractures, respectively. The quality of fracture reduction, determined with four parameters, was improved somewhat. The position of the nail(s), also determined with four parameters, improved considerably. The technical result was better in Garden IV fractures than in Garden III fractures.

An increased interest in femoral neck fracture treatment improved reduction and fixation.

Åke Johansson
Björn Strömqvist¹
Göran Bauer¹
Lars Ingvar Hansson²
Holger Pettersson

Departments of Diagnostic Radiology and ¹Orthopedics, Lunds University Hospital, S-221 85 Lund, and ²Department of Orthopedics, Umeå University Hospital, Umeå, Sweden

Correspondence: Dr. Strömqvist

Among factors affecting the healing prognosis after femoral neck fracture, some, such as age, sex, and fracture displacement, are beyond our influence, whereas others, such as the choice of fixation device (Frandsen & Andersen 1981, Strömqvist et al. 1984), the quality of fracture reduction and fixation (von Bahr et al. 1974, Frandsen & Andersen 1981, Linton 1944), and the postoperative vitality of the femoral head (Strömqvist et al. 1983, Strömqvist 1983), are, to a varying extent, possible to improve.

Radiographic classification systems have been developed regarding preoperative fracture displacement (Garden 1961, Pauwels 1935), as well as postoperative reduction quality and osteosynthesis placement (Frandsen & Andersen 1981), although important factors are not taken into account in these systems. Fracture displacement and reduction accuracy according to Garden (1961, 1971) are the systems most commonly used.

We have developed a radiographic scoring system for evaluation of femoral neck fracture operations and have attempted to demonstrate improved results by particularly devoted surgeons.

Patients and methods

The preoperative, peroperative, and 1-week postoperative radiographs of femoral neck fractures

treated in Lund in 1977 and 1981, respectively, were studied. In 1977, the fractures were operated on by any one of 30 surgeons at the department. The four-flanged Rydell nail was used for internal fixation. In 1981, all fractures were operated on by one of six surgeons in a prospective, randomized investigation (Strömqvist et al. 1984), designed to compare the four-flanged nail (patients born in an even year) with two hook-pins (patients born in an odd year). In 1977, 135 fractures were operated on; complete radiographs were obtained in 105 of these. In 1981, 138 fractures were operated on, and complete radiographs were obtained in 114.

All radiographs were scrutinized by one of us (ÅJ). An objective protocol regarding preoperative fracture parameters and postoperative fracture and osteosynthesis parameters was recorded. The factors considered favorable were given a higher score (see below). In undisplaced Stage I-II fractures, reduction was not attempted.

Preoperative fracture parameters. Three characteristics of the fracture were recorded and evaluated:

1. Preoperative fracture displacement was classified as minor (Garden's Stage I-II) 3 p (points), or major (Garden's Stage III-IV), 0 p.
2. The slope of the fracture line was determined according to Pauwels and classified as less than (2 p) or exceeding 55° (0 p).
3. Posterior and/or medial fracture fragments were recorded as absent (1 p) or present (0 p).

Postoperative fracture parameters. The following factors were regarded as indicators of good reduction:

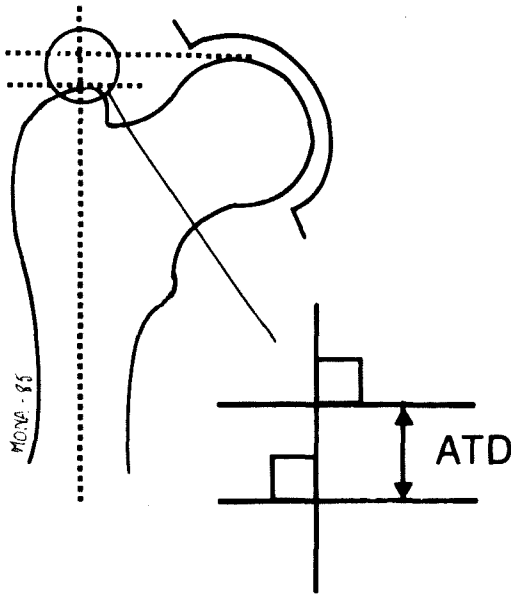


Figure 1. Measurement of articular-trochanteric distance (ATD).

1. Garden's angle 160–185° in the AP projection (2 p).
2. Angulation $\leq 5^\circ$ in the lateral projection (1 p).

Osteosynthesis parameters. The distal of the two hook pins was aimed at the same position as the nail; in hook-pinned fractures, the evaluation refers to this pin, although penetration of any of the pins was noted.

As indicators of adequate osteosynthesis, the following were regarded:

1. Medial cortical support for the nail/pin (2 p).
2. End of nail/pin 0–10 mm from the joint line (1 p).
3. Absence of nail/pin penetration (2 p).
4. End of nail/pin in the central one third of the femoral head (1 p).

Combined parameters. Two parameters were considered to be influenced by the quality of fracture reduction, as well as osteosynthesis position:

1. Fracture diastasis < 5 mm (1 p).
2. A decrease ≤ 10 mm in articular-trochanteric dis-

Table 1. Postoperative fracture position and position of osteosynthesis in the '77 and '81 groups. The results are mean points for each group.

	Garden I-II		Garden III		Garden IV	
	1977	1981	1977	1981	1977	1981
Number of cases	32	38	48	49	25	32
Fracture						
APview, Garden's angle 160–185°	1.76	1.90	1.46	1.64	1.76	2.00
Lateral view, angle $\leq 5^\circ$	0.94	0.92	0.75	0.67	0.80	0.89
Reduction, m \pm SD	2.71 \pm 0.40	2.82 \pm 0.39	2.22 \pm 0.89	2.31 \pm 0.72	2.56 \pm 0.63	2.90 \pm 0.49
Statistical difference		-		-		-
Osteosynthesis						
Medial support	0.56	1.90	0.76	1.54	1.28	1.78
Nail's/pin's end <10 mm from cortex	0.75	0.95	0.79	0.88	0.68	0.96
No penetration	1.76	1.94	1.64	1.84	1.52	1.94
Nail's/pin's end centrally	0.53	0.58	0.54	0.52	0.48	0.58
Osteosynth. m \pm SD	3.59 \pm 1.56	5.39 \pm 0.67	3.75 \pm 1.72	4.84 \pm 1.40	3.96 \pm 2.03	5.22 \pm 0.91
Statistical difference		***		***		.
Combined						
Diastasis <5 mm	0.88	0.95	0.63	0.73	0.60	0.81
ATD decrease ≤ 10 mm	2.00	1.90	1.68	1.88	1.44	1.80
Combined, m \pm SD	2.88 \pm 0.48	2.86 \pm 0.41	2.31 \pm 0.90	2.62 \pm 0.75	2.02 \pm 0.66	2.62 \pm 0.51
Statistical difference		-		-		**
Fracture + osteosynthesis						
m \pm SD	9.16 \pm 1.89	11.05 \pm 1.11	8.25 \pm 2.37	9.76 \pm 2.11	8.56 \pm 2.50	10.70 \pm 1.46
Statistical difference		***		**		***

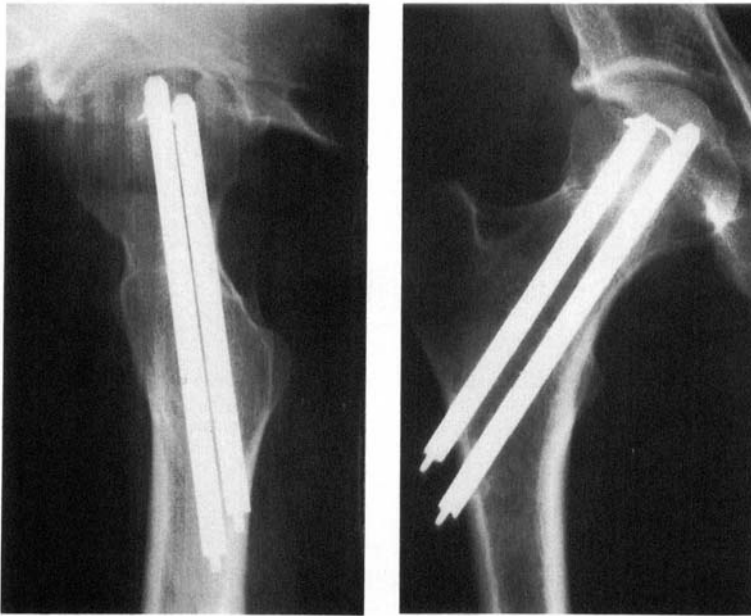


Figure 2. Postoperative AP (left) and lateral (right) view of a patient with maximum score for fracture, osteosynthesis, and combined parameters.

tance (Figure 1) from the preoperative to the postoperative radiograph (2 p).

The artculo-trochanteric distance was defined and measured as described by Edgren (1965), i.e., the vertical distance from the top of the greater trochanter to the most proximal point of the femoral head as measured on a line parallel to the long axis of the femur (Figure 1).

Figure 2 shows the postoperative radiographs of a patient with a maximum postoperative score.

Statistics. The Student's *t* test was used; the levels of significance are indicated in the text by superscripts – $P > 0.05$; $*0.05 > P > 0.01$; $**0.01 > P > 0.001$; $***0.001 > P$.

Results

Preoperative fracture classification. No difference was seen between the 1977 and the 1981 groups in Garden I-II (5.64 and 5.46 p, respectively), III (2.04 p for both years), or IV (1.92 and 1.98 p, respectively) fractures. Posterior comminution and a vertical fracture line was equally common in Garden III and IV fractures.

Postoperative radiographic evaluation (Table 1).

Fracture position. For Garden I-II fractures, the results were equivalent (no reduction at-

tempted); the diastasis seen in operation with a flanged nail but not with hook pins was the probable reason for the slight difference in results (Table 1). In Garden III and IV fractures the reduction results were better in the 1981 group, though not on a significant level. It is also notable that while the results for Garden III and IV fractures were equal in the 1977 group, the reduction results were considerably better for Garden IV fractures in the 1981 group.

Position of osteosynthesis. The position of osteosynthesis was superior in the 1981 group in almost every respect when compared with the 1977 group. Mean results were better in the 1981 group (Garden I-III^{***}, Garden IV^{*}). Medial support seemed especially difficult to achieve in 1977 (Figure 3), whereas in all groups only half of the cases had a nail ending centrally. The figures representing position of osteosynthesis were rather similar in the different Garden groups.

In the 1981 group the results were equivalent for nailed and hook-pinned fractures totally and when different degrees of fracture displacement were considered. For Garden I-II and IV fractures, the results were identical, whereas for Garden III fractures, somewhat

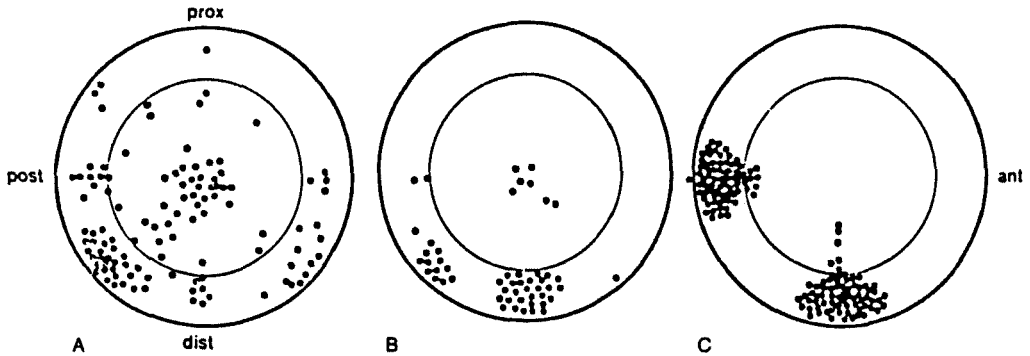


Figure 3. Sagittal section through the femoral neck showing the position of nails or pins. The area between the thin and the thick circles marks the zone where cortical support is achieved. A. The 102 nails of the 1977 group. B. The 52 nails of the 1981 group. C. The 70 pairs of hook-pins in the 1981 group; the distal pin is aimed at medial support (bottom) and the proximal at posterior support (left).

higher figures were seen in hook-pinned fractures, though not on a significant level.

Combined factors. For Garden IV fractures, the presence of a fracture diastasis > 5 mm and an ATD decrease > 10 mm was more common in the 1977 than the 1981 group**.

Over-all results. Adding reduction and osteosynthesis scores, the following results were obtained (Table I): for Garden I-II fractures 9.16 in the 1977 group and 11.1 in the 1981 group***. Among Garden III fractures the result in the 1977 group was 8.25 and in the 1981 group 9.76**. Among Garden IV fractures, the 1977 group had 8.56 and the 1981 group 10.7***.

Discussion

To determine radiographic displacement in femoral neck fractures, the systems of Pauwels (1935) and Garden (1961) are the only ones that have gained wide acceptance. A disadvantage that they have in common is that only the the AP view is taken into consideration. Garden III and IV fractures have an inferior prognosis when compared with Garden I and II fractures (Barnes et al. 1976, Linton 1944, Strömqvist et al. 1984). Whether the prognosis differs in Stage III fractures from Stage IV has been debated; some authors have found the prognosis comparable (Barnes 1976, Högh et

al. 1982, Strömqvist 1983), but others have noted a higher incidence of radiographic complications among Stage IV fractures (Brown & Abrami 1964, Kofoed & Alberts 1980). The contradictory results may be because the classification is uncertain in borderline cases, and often Garden I and II fractures are grouped together as undisplaced and Garden III and IV fractures as displaced. In the classification of Pauwels, the fractures with the most vertical slope have an inferior prognosis. Another unfavorable preoperative prognostic indicator is the existence of posterior comminution (Scheck 1980). We have included the three factors of Pauwels (1935) and Garden (1961) in our preoperative evaluation; displacement in the Garden classification was judged more ominous than Pauwels' vertical fracture line, which in turn was judged more important than posterior comminution.

A method for assessing the accuracy of fracture reduction was presented by Garden (1971) and consists of determining the angular deformity in the frontal as well as the lateral plane. We recorded these two factors as parameters of reduction quality. The ideal position of osteosynthesis may vary with different types, but medial cortical support is mechanically preferable because it yields 3-point fixation (Frankel 1960). Penetration of the nail into the joint is an obvious technical failure, and may fracture the femoral head (Kalén 1968). Previous investigations have underlined the advantage of the nail ending centrally in the head of the femur

and less than 10 mm from the joint line (Frandsen & Andersen 1981).

Two factors recorded probably reflect the quality of both reduction and osteosynthesis: the diastasis and the decreased articulo-trochanteric distance, a measure mainly of femoral neck shortening. Diastasis may indicate fracture instability, possibly associated with capsular vessel injury. We recorded a decrease of 10 mm or more in articulo-trochanteric distance between the preoperative and 1-week postoperative radiographs as a parameter of insufficient fracture reduction, but, undoubtedly, this distance also reflects the quality of osteosynthesis. This measure is influenced by rotation and flexion of the hip (Edgren 1965); extension and neutral rotation with the foot pointing towards the camera were aimed at in the radiographs of this study.

In almost all aspects, the results in 1981 were superior to those in 1977, notably the position of osteosynthesis and more pronounced with greater primary dislocation. It is remarkable that the technical handling of Garden IV fractures in 1981 was superior to that of Garden III fractures. This may possibly be interpreted as an effect of the surgeons' increased skill in handling the most difficult fractures. Radiographically, the result of the two methods of osteosynthesis used in 1981 did not differ.

In the 1981 series, every femoral neck fracture admitted was reduced and nailed; primary arthroplasty because of technical failure was never required. We feel that this supports our policy of primary nailing of all cervical hip fractures except displaced fractures in rheumatoids (Strömquist 1984).

Four parameters were used for determining the postoperative fracture position and four for determining the position of osteosynthesis. This proved sufficient to allow a comparison between operations in 1977 and 1981; with increased interest focused on femoral-neck fracture fixation, the technical skill improved. In a future study, comparing the parameters chosen for the radiographic end result in terms of healing complications, multivariate analysis may show which factors are the most discriminant ones.

References

- von Bahr, V., Syk, B. & Walheim, G. (1974) Osteosynthesis of femoral neck fracture using screws. *Acta Chir. Scand.* **140**, 277-282.
- Barnes, R., Brown, J. T., Garden, R. S. & Nicoll, E. A. (1976) Subcapital fractures of the femur. *J. Bone Joint Surg.* **58-B**, 2-24.
- Brown, J. T. & Abrami G. (1964) Transcervical femoral fracture. *J. Bone Joint Surg.* **46-B**, 648-663.
- Edgren, W. (1965) Coxa plana. *Acta Orthop. Scand.* Suppl. 84.
- Frandsen, P. A. & Andersen, P. E. (1981) Treatment of displaced fractures of the femoral neck. *Acta Orthop. Scand.* **52**, 547-552.
- Frankel, V. H. (1960) *The femoral neck: function, fracture mechanism, internal fixation; An experimental study.* Charles Thomas, Springfield, Ill.
- Garden, R. S. (1961) Low-angle fixation in fractures of the femoral neck. *J. Bone Joint Surg.* **43-B**, 647-663.
- Garden, R. S. (1971) Malreduction and avascular necrosis in subcapital fractures of the femur. *J. Bone Joint Surg.* **53-B**, 183-197.
- Högh, J., Jensen, J. & Lauritzen, J. (1982) Dislocated femoral neck fractures. *Acta Orthop. Scand.* **53**, 245-249.
- Kalén, R. (1968) Internal fixation in hip joint arthrodesis. *Acta Orthop. Scand.* Suppl. 112.
- Kofoed, H. & Alberts, A. (1980) Femoral neck fractures. 165 cases treated by multiple percutaneous pinning. *Acta Orthop. Scand.* **51**, 127-136.
- Linton, P. (1944) On the different types of intracapsular fractures of the femoral neck. *Acta Chir. Scand.* Suppl. 86.
- Pauwels, F. (1935) *Der Schenkelhalsbruch, ein mechanisches Problem.* Stuttgart.
- Scheck, M. (1980) The significance of posterior comminution in femoral neck fractures. *Clin. Orthop.* **152**, 138-142.
- Strömquist, B., Hansson, L. I., Palmer, J., Ceder, L. & Thorngren, K. G. (1983) Scintimetric evaluation of nailed femoral neck fractures with special reference to type of osteosynthesis. *Acta Orthop. Scand.* **54**, 340-347.
- Strömquist, B. (1983) Femoral head vitality after intracapsular hip fracture. *Acta Orthop. Scand.* **54**, Suppl. 200.
- Strömquist, B., Hansson, L. I., Nilsson, L. T. & Thorngren, K. G. (1984) Two-year follow-up of femoral neck fractures. Comparison of osteosynthesis methods. *Acta Orthop. Scand.* **55**, 521-525.
- Strömquist, B. (1984) Hip fracture in rheumatoid arthritis. *Acta Orthop. Scand.* **55**, 624-628.