

From the Children's Hospital Medical Center and University of Cincinnati
College of Medicine, Cincinnati, Ohio, USA

Neurofibromatosis in children

Alvin H. Crawford

ACTA ORTHOPAEDICA SCANDINAVICA SUPPLEMENTUM NO. 218, VOL. 57. 1986

MUNKSGAARD · COPENHAGEN

Historical review

Neurofibromatosis is a multisystemic disease that may manifest itself as abnormalities of the skin, nervous tissue, bones, and soft tissues, and is often hereditary. It is believed to be a hamartomatous disorder of neural crest derivation. Akenside in 1768 first recorded a description of a patient with multiple neurofibromatoses (90). However, credit is most frequently given to Wilhelm G. Telesius von Telaneau for contributing one of the earliest clinical descriptions of a patient with neurofibromatosis in 1793 (126). In 1882, Frederick Daniel von Recklinghausen published his book, "Über die Multiplen Fibrome der Haut und ihre Beziehung zur den Multiplen Neuomen", dedicated to the pathologist Rudolf Virchow in honor of the twenty-fifth anniversary of the Foundation of the Pathological Institute of Berlin (99, 132). In his book, von Recklinghausen coined the term "neurofibroma" and he was able to demonstrate that a small cutaneous nerve was to be found to be connected to every one of the cutaneous and subcutaneous tumors. Prior to this, the term "dermal fibroma" or "false neuroma" had been applied to the nodules. Thus von Recklinghausen was the first to demonstrate the origin to tumors from nerve sheaths, and his clinical and pathological descriptions of the disease were epoch-making (90).

R. W. Smith, first Professor of Surgery at the Dublin Medical School and better known for his work on forearm fractures (reverse Colles') published a remarkable volume in 1849 in which he reported in great detail two cases of generalized neurofibromatosis with necropsy and completed the first review of the literature with 75 references (90).

Further contribution to our knowledge of neurofibromatosis can be chronicled as follows. Chauffard, Marre, and Bernard identified pigmentary changes as a primary aspect of the disease in 1896 (90). Thompson first pointed out clearly that neurofibromatosis was hereditary in 1900 (90). In 1901, Adrian noted the high incidence of skeletal changes such as atrophy, hypertrophy, and scoliosis. In 1909, Suzuki first reported a patient with neurofibromatosis and pheochromocytoma. In 1910 Verocay found that the nerve sheath cell proliferated and postulated that it was this cell that produced the tumors of neurofibromatosis (90). In 1916, Henschen identified the high incidence of bilateral acoustic neuromata associated with neurofibromatosis. In 1918 Preiser & Davenport established that neurofibromatosis was not sex-linked and that it followed the Mendelian Law as an autosomal dominant trait. In 1924, Brooks & Lehmann comprehensively classified skeletal changes of neurofibromatosis for the first time in the American literature. In 1924, Harrison identified the neural crest

origin of Schwann cells (90). Hosoi in 1935 first identified the association of malignant nerve sheath tumors with neurofibromatosis. Lisch in 1937 substantiated the importance of iris nodules first seen in patients with neurofibromatosis by Goldstein & Wexler to be associated with most patients with neurofibromatosis (90). In 1940, Davis firmly established the association of optic glioma as a part of neurofibromatosis (90). In 1945, Reubi identified the large and the small arteriovascular lesions associated with neurofibromatosis (90). In 1956, Crowe et al. in their now classic monograph, described the diagnostic significance of multiple café-au-lait spots in reference to neurofibromatosis. The clinical spectrum of neurofibromatosis was completely elucidated in their monograph.

Table I. Common findings in pediatric neurofibromatosis.

	Per cent
Café-au-lait and cutaneous tumors by adolescent years	72-90
Positive family history	45-48
CNS lesions	16-26
Scoliosis (as high as 60% of orthopaedic literature)	20-26
Skull and facial deformities	20
Significant CAL alone (not a true diagnosis of neurofibromatosis)	17
Failure to thrive in infancy	16
Aqueductal stenosis	16
Breast enlargement	13
Seizures	13
Hemihypertrophy	13
Tibial pseudarthrosis	12
Benign tumors alone	11
Extracranial malignancy (dramatic increase with age)	11-20
Vascular disease (dramatic increase with age)	10
Mediastinal tumors	8

Modified from: Fienman, N. L. (41)

The manifestations of neurofibromatosis in children have been reviewed by Chao in 1959, Suzuki and associates in 1963, Fienman & Yakovac in 1970, Pollnitz in 1976, Cole & Meyers in 1978, Holt in 1978, Crawford in 1978, Crawford in 1978, Fienman in 1981, and Crawford in 1981. These papers have, by and large, represented a comprehensive view of the manifestations of the disease in children (Table I). Except for the papers of Moore (86), Miller et al. (85), and McCarroll (80), most of the information regarding the osseous manifestations of neurofibromatosis has appeared in the radiologic literature. Reports in the orthopaedic literature have dealt primarily with specific entities such as spinal deformity, pseudoarthrosis of the tibia, paraplegia, hemihypertrophy, and neoplasia.

Material and methods

At the Alfred I. Dupont Institute a study was undertaken in 1974 of all patients with the diagnosis of neurofibromatosis. Eighty-two patients were conclusively diagnosed. The criteria for diagnosis required at least 2 of the most commonly found entities: multiple cafe-au-lait spots, a known family history, definitive lesional biopsy, or one of the characteristic bony lesions (such as pseudarthrosis tibiae, hemihypertrophy, or spinal deformity). All patients were under 12 years of age at the time of diagnosis and, when reported, represented the largest group of children with neurofibromatosis ever reported from one institution (31). The author has now increased his experience with the addition of 34 patients (from the San Diego Naval Hospital, Henry Ford Hospital, and Cincinnati Children's Hospital Medical Center) to 116 patients under 12 years of age conclusively diagnosed as having neurofibromatosis and followed for an average of 5 years. Sixteen additional patients have presented over the past year through the local chapter of the National Neurofibromatosis Foundation but are not included in this work.

This study group represents the largest number of patients conclusively diagnosed as having neurofibromatosis as a child and followed by one individual for this length of time.

Of the combined study group, 101 are white, 15 are black, with 68 females and 48 males. The presenting complaints represent a myriad of entities heavily weighed towards spinal deformity (Tables II & III). These findings may possibly be prejudicial because of the author's interest in that field. The series is also biased towards complex orthopaedic problems because of the medical community's awareness of the author's interest in the disease.

Table II. Presenting complaints in 116 children with neurofibromatosis.

	No
Curved spine	56
1 noted coincident to intravenous pyelogram	
2 post operative excision of intrathoracic ganglio-neurofibroma	
Neurofibromatosis	24
Limb length discrepancy	13
Tibial pseudarthrosis	10
4 Tibial fractures	
4 Pseudarthroses	
2 Bowing	
Family study	6
Abnormal neurologic defects	6
Pain	3
2 Hip (1 pathologic fracture)	
1 Knee	
Café-au-lait spots	4
Foot swelling	2
Facial enlargement	1
Digital enlargement	1
Limb enlargement	1
Visual problem	1
Foot turning in	1
Cervical spine tumor	1
Nodules	1

Table III. Manifestations of neurofibromatosis in children.

	Per cent
Café-au-lait	89
Scoliosis:	64
Positive fam hx	41
Nodules	18
Disorders of bone growth	16
Pseudarthrosis	13
Elephantiasis	9
Nevus	8
Mediastinal tumors	3
Intracranial tumors	2
Aplasia lesser wing of sphenoid bone*	
Ambiguous genitalia*	
Vertical talus*	
Subluxed and dislocated hips*	
Rhabdomyosarcoma*	
Left foot drop*	

* Less than 1 per cent

Genetics

Neurofibromatosis is the most common single gene disorder found in humans. Down's syndrome is the most common chromosomal disorder. The disorder has been virtually unknown to the general public until the recent popularity of Bernhard Pomerance's play, *The Elephant Man*, about Joseph Carey MacDonald ("John") Merrick. It is much more common than other conditions well known to the general public such as muscular dystrophy, cystic fibrosis, and Down's syndrome. The occurrence of this disease in multiple family members was reported in Europe as early as 1847 by Virchow. In 1901 Adrian reported that 20% of 447 cases reviewed exhibited direct transmission. Preiser & Davenport first described the condition as an autosomal dominant in 1918. It is now considered to be an autosomal dominant trait with variable penetrance and a very high rate of spontaneous mutation; however, the recent realization of alternative forms of the disease which may propagate through several generations severely challenges the spontaneous mutation theory. Genetic heterogeneity is a key element in neurofibromatosis. There are likely to be multiple forms of the disorder, probably involving multiple alleles at a single locus and possibly several gene loci. The disorder has tremendous clinical variability, an aspect that must be taken into account in any discussion of pathogenesis (102). It has been documented to have a frequency of 1 per 2500 to 3000 live births. Spontaneous abortion in patients with neurofibromatosis has not been studied to date. A family history was obtained in 47 of our 116 patients.

Discussion

Having accepted the autosomal dominant theory of inheritance in neurofibromatosis, one has to be concerned about the high number of mutations (50%) occurring with the disorder (31). This spontaneous mutation rate has been challenged by Steg and coworkers with dermatoglyphic analysis utilizing a computerized pattern analysis and classification system (122). Abnormal congenital dermatoglyphic patterns have been found in many parents of patients formerly classified as spontaneous mutations. When one considers the many clinical presentations of the disease, one can more easily accept the autosomal dominant concept and appreciate the varying penetrance and expressivity. It also allows that, rather than assuming a skip of a generation, there was a different mode of expression with the dominant gene present.

Contrast those patients with multiple café-au-lait spots versus those presenting with bilateral acoustic neuromata versus those with axillary freckling only.

Young et al. classified neurofibromatosis into three hereditary forms: Peripheral form with café-au-lait spots and neurofibroma, the central form with multiple tumors in the central nervous system of a type consistent with neurofibromatosis, and a third mixed form with both peripheral signs of neurofibromatosis and tumors in the central nervous system (142). These authors further pointed out that the disease, though not always, is usually inherited in the same form in the next generation. Other authors have considered the penetrance of the disease form to be related to maternal involvement and elderly paternity.

Most authors now accept the 2 clinical forms of neurofibromatosis, i.e., peripheral neurofibromatosis and central neurofibromatosis. The central form consists of those with multiple central nervous system involvement presenting as neoplasia (meningioneuroplasia, cranial Schwannoma, and optic glioma). The exception to this concept is that of a special form of central neurofibromatosis, i.e., bilateral acoustic neuroma occurring as its only sign. The peripheral form includes the more typical presentation, i.e., cutaneous (café-au-lait spots, fibroma molluscum) and bony lesions such as scoliosis, segmental skeletal overgrowth and pseudarthroses.

I feel the diagnosis of neurofibromatosis in children can be conclusively made when 2 of the 4 most commonly occurring criteria are met, i.e., café-au-lait spots (5 or more in number with a diameter of at least .5 cm), positive family history, histologic diagnosis of neurofibroma, and a characteristic osseous lesion (hemihypertrophy, spinal deformity, or congenital tibial pseudarthrosis).

Clinical findings

Soft tissue manifestations

Café-au-lait spots

Café-au-lait spots were present in 103 of our 116 patients, or 89% (Figure 1A). The café-au-lait type of pigmentation is a characteristic lesion of neurofibromatosis; however, von Recklinghausen did not consider them to be a part of the disorder. This pigmentation is tan, macular, and melanotic in origin. It is located in and around the basal layer of the epidermis. The lesions may vary in shape, size, number and location. In neurofibromatosis they are frequently found in areas of the skin not exposed to the sun. The presence of a café-au-lait spot may be normal. McCarroll examined normal nursing students and found that 20% had café-au-lait spots without associated anomalies (80). Crowe et al. concluded that an adult who has more than 6 café-au-lait spots measuring 1.5 cm or more in diameter should be presumed to have neurofibromatosis (32). Whitehouse evaluated 365 children under the age of 5 and stated that 2 or less café-au-lait spots occur in only 0.75% of normal children and that 5 spots, with a diameter of at least 0.5 cm, should be diagnostic of neurofibromatosis until proven otherwise (139). Crawford reported on patients under 12 years of age conclusively diagnosed by his criteria as having neurofibromatosis who, sometimes, did not have any café-au-lait spots on presentation but developed them at a later age (31). His young patients who presented with only a few café-au-lait spots showed an increase in number and size with increasing age. The lesions are usually present by 9 years of age. In boys, the intensity of color of the spots increases up to puberty and then remains stationary. In women, the areas become darker with pregnancy and remain dark throughout their lives. The geometric requirements of the café-au-lait spots for diagnosis, i.e., smooth edges (coast of California) for neurofibromatosis, as contrasted to the jagged edge (coast of Maine) seen in fibrous dysplasia have been questioned. Undue emphasis on the number, size, and shape of café-au-lait spots can lead to under-diagnosis, over-diagnosis or misdiagnosis (102).

Recent authors have attempted to make a qualitative distinction between the café-au-lait spots of neurofibromatosis and those of fibrous dysplasia as opposed to those occurring in normal subjects. Johnson & Charneco described the presence of giant melanosomes in the melanocytes in café-au-lait spots in 6 out of 8 neurofibromatosis patients whom they examined (63). No similar changes were found in the so-called

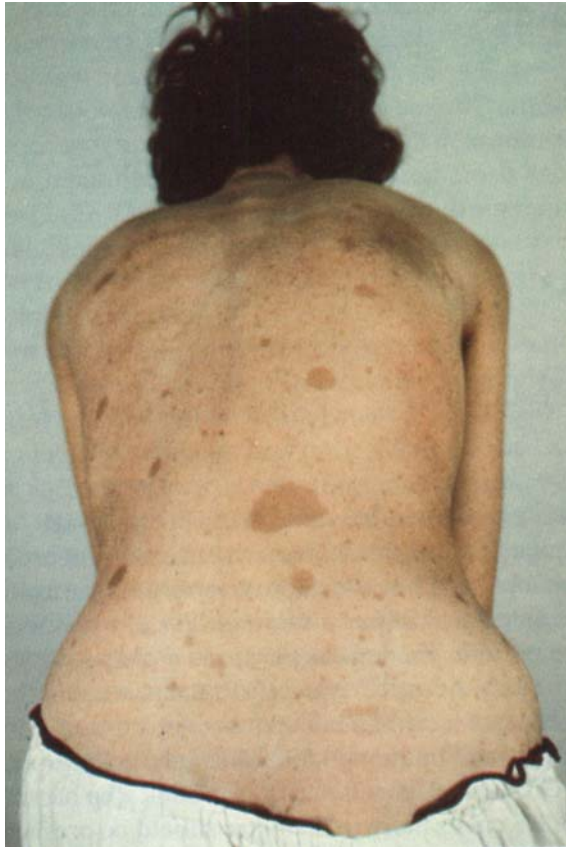
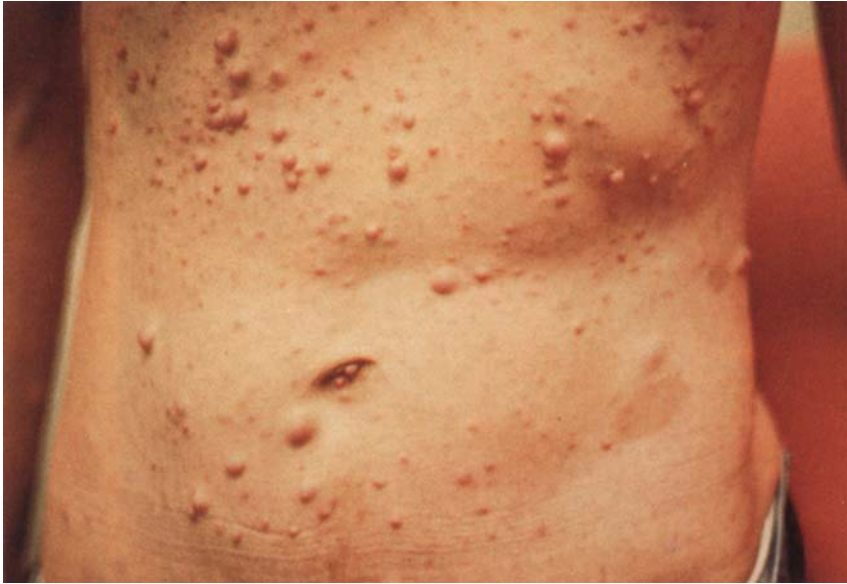

Figure 1. The cutaneous lesion of neurofibromatosis as seen in children.

- A. Multiple café-au-lait spots in a young patient with spinal deformity. Note the variation in size and shape of the lesions. These lesions tend to increase in size and number as the child matures.

normally occurring café-au-lait spots. The café-au-lait spots in neurofibromatosis showed a higher number of melanocytes/sq mm compared with the number of these cells in corresponding parts of skin of healthy persons. Both Johnson and Takahasi (125) have noted an increased activity of melanocytes in neurofibromatosis; however, these findings have been of no pathognomonic value. The café-au-lait spots of children with neurofibromatosis rarely show giant melanosomes as compared to adults with the disease who show large numbers of pigment bodies.

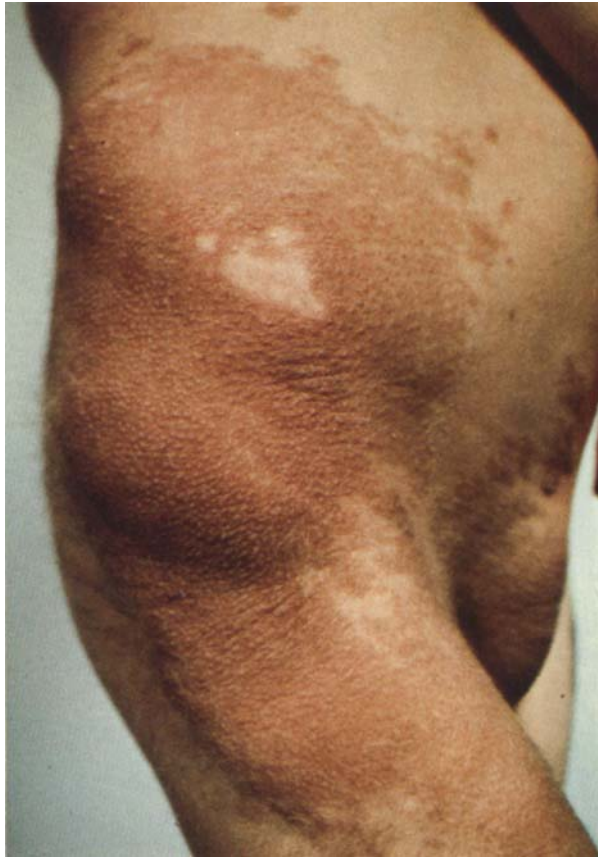Frenk showed that in Albright's disease, café-au-lait spots did not contain giant melanosomes (44). Therefore, some differences, both quantitative and qualitative but not pathognomonic, have thus been recognized and these afford some possibility of distinguishing the café-au-lait spots of neurofibromatosis from those seen in other conditions.



B. Multiple dermal neurofibroma (fibroma molluscum). These pedunculated lesions occur in the post pubescent adolescent. They have no particular distribution and can be seen on the adjacent right forearm. Several subcutaneous neurofibroma and café-au-lait spots are also present on this photograph.

Nodules

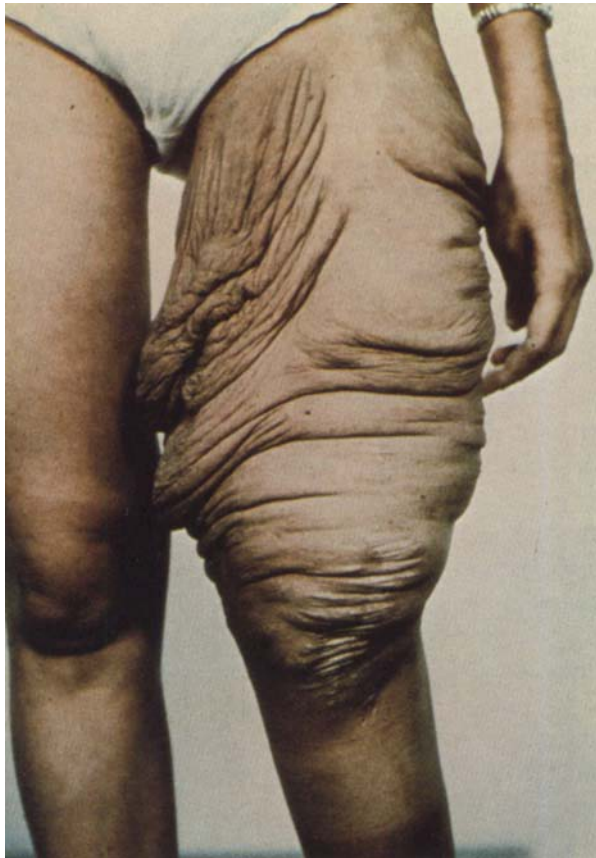Twenty-one of our patients (18%) had cutaneous nodules [fibroma molluscum] (Figure 1B). They were all adolescents. Cutaneous nodules are only found after puberty. They are usually manifestations of long-standing or adult disease, and do not occur with any frequency (12%) in childhood (57). These tumors may grow under, be flush with, or be raised above the level of the skin. Although they are usually the color of normal skin, early lesions may be violaceous. Ormsby & Montgomery interpreted these tumors as true neurofibromas arising from peripheral nerves and their supporting structures, but this conclusion had not been proven (93). Rubenstein shares this theory (107). Stout considered these tumors to be simple proliferation of fibrous tissue (123). Recent electron microscopy studies have demonstrated the axons and the Schwann cells to be present in these tumors; therefore, it is appropriate that they be included under the term “dermal neurofibroma” (51). Dermal neurofibromas are rarely associated with central nervous system lesions and only occasionally does one see skeletal involvement with this peripheral type of neurofibromatosis.



- C. This large nevus overlies a plexiform neurofibroma. The plexiform neurofibroma was directly over the greater trochanter and iliac crest of this patient who had a spinal deformity but could not tolerate a Milwaukee brace over the area because of extreme sensitivity. The lesion only occurred on one side of the body.

Nevus

Nine patients (8%) presented with nevi with descriptions including “nevus lateralis” and “bathing trunk” nevus (Figure 1C). The nevus lateralis can be described as dark brown pigmented skin over one-half of the abdominal wall with an abrupt change of pigmentation occurring along the midline. Nevi, or hyperpigmentation, may be present in up to 6% of children with neurofibromatosis (31). These lesions are dark brown, pigmented areas of the skin which occasionally tend to isolate themselves to one side of the body. Patients may present with large nevi which cover broad areas of the skin, some of which are quite sensitive. The sensitivity is often related to an underlying subcutaneous plexiform neurofibroma. The plexiform neurofibromata have a “ropey”, “bag of worms” feeling and are extremely sensitive. The areas of involvement may also have decreased sensation, causing sores to develop under a brace or cast without the patient’s knowledge, or they may have hypersensitivity.

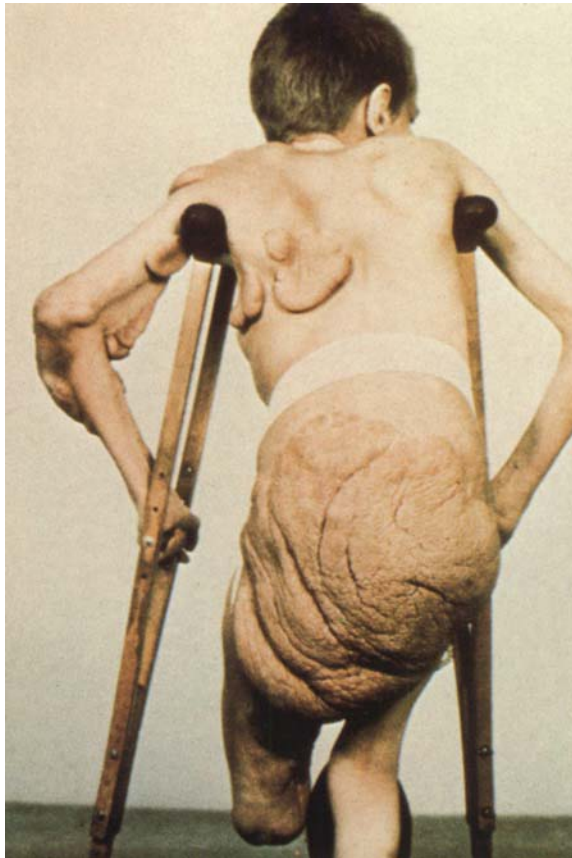


D. Elephantiasis neuromatosis. This thickening of the skin with redundant folds gives a pachydermatocele appearance to this lesion. Several attempts have been made to perform physical arrests of the distal femur and proximal tibia which were unsuccessful. She subsequently succumbed to a retroperitoneal neurofibrosarcoma.

When a plexiform neurofibroma is found underlying an area of cutaneous hyperpigmentation, especially when the tumor approaches or reaches the midline of the body, it appears that the tumor will be aggressive and/or invade the spinal canal. The plexiform neurofibroma is known for harboring the potential for malignant degeneration (103).

Elephantiasis

Frequently large soft tissue masses are seen in neurofibromatosis. These masses have been termed “pachydermatoceles” or “elephantiasis neuromatosa”. They are characterized by a rough raised villous type of skin hypertrophy presenting an unmistakable appearance (Figure 1D). Although more frequently occurring in adult life, we encountered 10 patients (8 %) with varying degrees of involvement. Weiss has de-



- E. Verrucous hyperplasia of the skin over the left buttock. This lesion was associated with elongation of the lower extremity. Note that the child has had a knee disarticulation but the femur extends far below its opposite knee joint. Verrucous hyperplasia represents the most grotesque of all cutaneous lesions of neurofibromatosis. Note that there are no lesions on the right side of the body.

scribed this finding to be characteristic of neurofibromatosis (137). There is usually dysplasia of the underlying bone when the lesion occurs in an extremity (60).

Verrucous hyperplasia

Verrucous hyperplasia is an infrequent but definite cutaneous lesion of neurofibromatosis. There is tremendous overgrowth of the skin with thickening but a velvety-soft papillary quality. Many crevices form in this disorder and tend to break down easily with some weeping occurring in the skin folds. The sites often become superficially infected and give rise to a foul odor. The lesion presents most often unilaterally and can be considered one of the most grotesque lesions of neurofibromatosis. I encountered only one patient with this disorder (Figure 1E).

Axillary freckling

Axillary freckles, which are diffuse small hyperpigmented spots of up to 2–3 mm in diameter found in the armpits, are helpful diagnostic criteria for neurofibromatosis, if present. Axillary freckling and an occasional dermal fibroma may be the only physical finding in the parent of a child who shows all of the criteria required for the diagnosis of neurofibromatosis. Prior to our being aware of this alternative mode of expression, the child would have been considered a spontaneous mutation. Axillary freckling was an inconsistent finding in our study group.

Discussion of cutaneous findings

The cutaneous manifestation of neurofibromatosis is well demonstrated in our series in that café-au-lait spots were present in 103 of the 116 patients. The series confirmed the observation that only a few café-au-lait spots may be present (5 lesions of greater than .5 cm) in children, but they usually increase in number and size with age. Several of the patients who had abnormal biopsy results did not have café-au-lait spots at the time of their initial examination but subsequently developed multiple skin lesions. In fact, most of the children presenting with anterior lateral bowing and tibial pseudarthrosis had few if any café-au-lait spots on initial presentation. All of these patients had multiple café-au-lait spots after 5–6 years of age.

Only those children over 12 years of age demonstrated the dermal neurofibroma (fibroma molluscum) of neurofibromatosis. One patient who had no evidence of cutaneous lesions on initial presentation revealed multiple fibroma molluscum all over her body at follow-up 13 years later.

The author has also noted some patients to have a granular, sandy, slightly pigmented skin texture as the only cutaneous manifestation of the disorder. Others may complain of pruritis or an “itchiness”.

In most cases, neurofibromatosis is typical in its development with multiple café-au-lait spots and neurofibroma, leaving no doubt the diagnosis. However, in certain cases the manifestations of the disease are few and relatively uncommon so that the diagnosis may be greatly in doubt. Difficulties may also arise through the nature of the disease which often shows slow clinical evolution over decades, the typical cutaneous neurofibromata developing at or after puberty or considerably later in life. Sharp and Young (117) pointed out that it was difficult to classify the disease into different clinical forms because of its protean manifestation and also because of the occurrence of alternative presentations, for example, those with nothing more than café-au-lait spots on the skin or axillary freckling.

That neurofibromatosis is probably of multiple cell origin has been substantiated by studies using the X-linked glucose 6 phosphate dehydrogenase mosaicism marker (39). It may well be influenced by increased nerve growth stimulating factor, although current conflicting evidence regarding this theory remains to be resolved (114, 119). The etiology is still unknown.

Skeletal manifestations

Spinal deformities

Scoliosis: Scoliosis is the most common osseous defect associated with neurofibromatosis. Gould (45) and Weiss (137) were the first to point out the high incidence of spinal deformities in this disease. The spinal deformity may vary in severity from mild nonprogressive forms to severe curvatures. Since Weiss', a dermatologist, first description of this lesion associated with neurofibromatosis in 1921, many authors have cited the association of the two conditions (3, 13, 15, 16, 21, 43, 70, 75, 85, 100, 113, 115, 131, 140).

The cause of spinal deformity is unknown, but it has been suggested to be secondary to osteomalacia, a localized neurofibromatous tumor eroding and infiltrating bone, endocrine disturbances, and mesodermal dysplasia (20, 45, 46, 52, 112, 116, 137).

The relative incidence of spinal deformities in neurofibromatosis is unknown. In a general orthopaedic clinic, 2% of the scoliosis population will have neurofibromatosis. In a scoliosis clinic population, approximately 3% will have neurofibromatosis, whereas in a neurofibromatosis population, 60% of patients will have some disorder of the spine (31). Of approximately 10,000 patients seen by Winter et al. with scoliosis, only 102 were found to fit the traditional criteria for diagnosis of neurofibromatosis (140). According to most authors, the scoliosis noted in neurofibromatosis is usually in the thoracic area and tends to produce a short, sharply angulated curvature, including 4 to 6 vertebrae, and is usually progressive. Miller described the curvature of neurofibromatosis as a kyphoscoliosis with the site of predilection in the lower dorsal area, which may be noticed in early childhood (85). The characteristic feature is a sharp angulation at the apex of the gibbus. Scott evaluated the spinal deformities of 81 patients and found no evidence of any consistent pattern of scoliosis in neurofibromatosis. He noted that the severity of some of the curves resemble a congenital scoliosis (115). Veliskakis and associates noted in 43 of 55 patients a characteristic short curve composed of fewer segments with sharp apical wedging and rotation in the lower thoracic area. The wedging was occasionally so severe that it was mistaken for a hemivertebra. They believed that the tendency of this curve to progress rapidly warranted early spine fusion of the involved segments to prevent progression. Recent investigators (21, 48, 115) have suggested that there is no standard pattern of spine deformity in neurofibromatosis and the types of curvature found are quite variable. Cobb was one of the first to recognize the seriousness of the spine deformity and especially the deleterious effect of laminectomy in a patient with neurofibromatosis and scoliosis. He also felt that a high proportion of scoliosis classified as idiopathic was possibly secondary to neurofibromatosis (24, 25).

The consensus is that there are probably 2 patterns of scoliosis found in neurofibromatosis, that is, the characteristic short segmented, dysplastic, sharply angulated curve and curvatures resembling idiopathic scoliosis. Right and left convex thoracic curves occur in about equal numbers. The dysplastic curvature is characterized by severe wedging of the apical vertebral bodies, strong rotation of apical ver-

tebrae, scalloping of the vertebral bodies, spindling of transverse processes, foraminal enlargement, and pencilling of the apical ribs (Figure 2). It is most important to recognize the dysplastic or dystrophic curve and distinguish it from the nondystrophic curve. Winter et al. felt that brace treatment was not effective in the management of the dystrophic curve and recommended an aggressive approach to management: “There is no justification for passively observing the progression of the spine deformity in neurofibromatosis” (140).

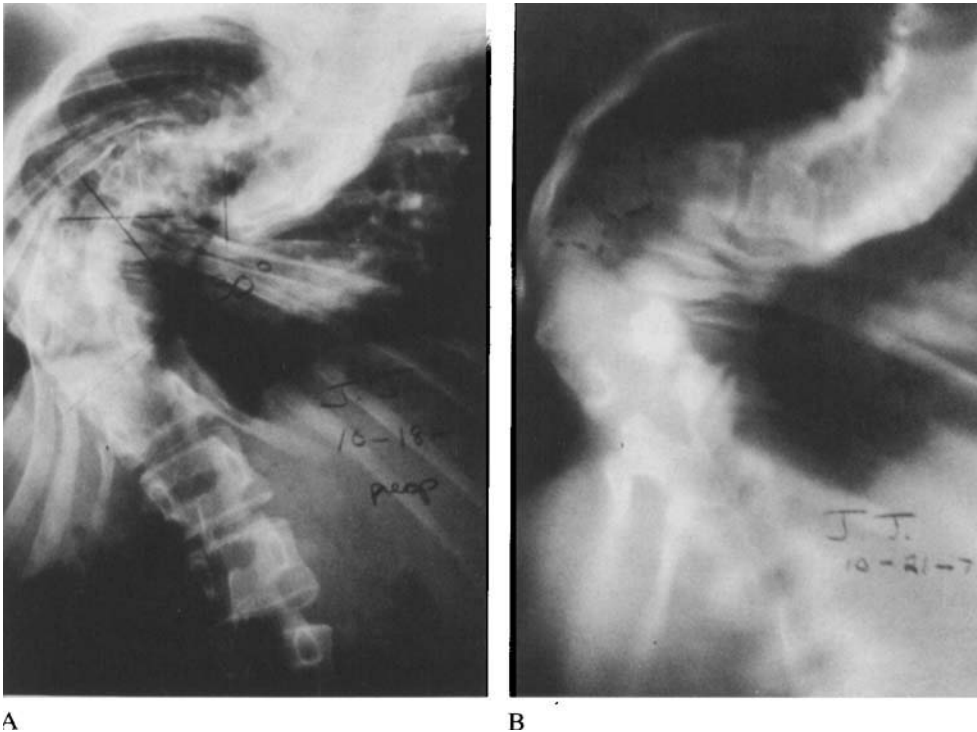


Figure 2. Dystrophic neurofibromatous curvature with short segmented, sharply angulated “kinky” spinal deformity; plain film and plain tomography.

- A. AP radiogram of a child with a spinal deformity associated with neurofibromatosis. There is scalloping of the vertebral margins, gross rotation of the apical vertebrae, relative appearance of a paraspinous mass, pencilling of the ribs and concavity.
- B. Plain polytomography reveals widening of the spinal canal in the upper thoracic region inferring dural ectasia. There appears to be a 180 degree vertebral body rotation between the upper thoracic vertebrae and the apical vertebrae. Note the proximity of the anterior aspect of the apical vertebral bodies to the ribs. (Figures A and B courtesy of Dr. Michael Schafer, Chicago, IL).

Those curvatures resembling idiopathic scoliosis usually demonstrate the same tendency to progress as other idiopathic curvatures that have no dysplastic changes of their vertebral bodies. They can usually be managed in the same manner as other idiopathic curvatures.

Seventy-four of our patients (64%) presented with spinal deformity. Only 18 had the characteristic dysplastic neurofibromatosis curve, and the remainder had curves indistinguishable from the idiopathic type. The radiographic characteristics and response to treatment in the idiopathic appearing curves were similar to those in patients without neurofibromatosis.

Sixty of our 74 patients with spinal deformities (81%) were female. Seven of the Dupont Institute patients were detected because of their ongoing family study to determine the genetic aspect of scoliosis (28). The finding of neurofibromatosis in the family study reconfirms the genetic aspect.

Forty-six of our patients underwent posterior spinal fusion, and of these 10 had re-exploration for possible pseudarthrosis, of which 6 were found to have defects in the fusion mass. One other patient is known to have a pseudarthrosis but has not been explored. This incidence is much higher than that for the idiopathic curve treated during the same period of time. The remainder of the series (40 patients) with non-dystrophic scoliosis were felt to have achieved a stable posterior spinal fusion with an average of 3 years follow-up.

Kyphoscoliosis: The severe kyphoscoliosis seen in neurofibromatosis is distinguished by the predominance of kyphosis over the scoliosis with acute angulation being a typical sign. The vertebral bodies frequently are so deformed and attenuated at the apex that it may be impossible to identify them on routine roentgenograms. Curtis and others believed that the kyphosis contributed more to the production of paraplegia in their patients than did the scoliosis (33). This view is supported by the biomechanical studies of Breig which showed that flexion of the spine caused elongation of the spinal canal and deformation of the spinal cord. Pathologically increased spinal flexion, as by kyphotic deformity, leads to excessive axial tension of the spinal cord parenchyma and may result in neurological impairment (17). Miller found that in 20 patients with paraplegia associated with von Recklinghausen's disease, severe angulation of the spine was responsible for the paraplegia in more than half of the patients (85). Lonstein and coworkers reviewed 45 patients with cord compression due to spinal curvature and found neurofibromatosis to be secondary only to congenital kyphosis as the cause of compression (74).

Of the 74 patients with spinal deformity, 8 presented with more kyphosis than scoliosis. One patient, 6 years of age, underwent a posterior fusion from T4 to T12 but an attempted anterior spinal fusion for progressive kyphosis, could not be carried out because of pronounced local invasion of the soft tissue with neurofibromatous material. The other 7 patients underwent attempts at obtaining surgical stabilization with varying successes. Only 3 patients obtained a primary posterior spinal fusion after multiple surgical procedures. Recently Winter and others have reported a 64% incidence of pseudarthrosis in patients with dysplastic scoliosis with kyphosis of more than 50° (140) (Figure 3).

Cervical spine disorders: Klose recorded the first case of cervical spine abnormality associated with neurofibromatosis. Until recently, only casual references to the cervical spine have been evident in studies of other manifestations of neurofibromatosis (65).

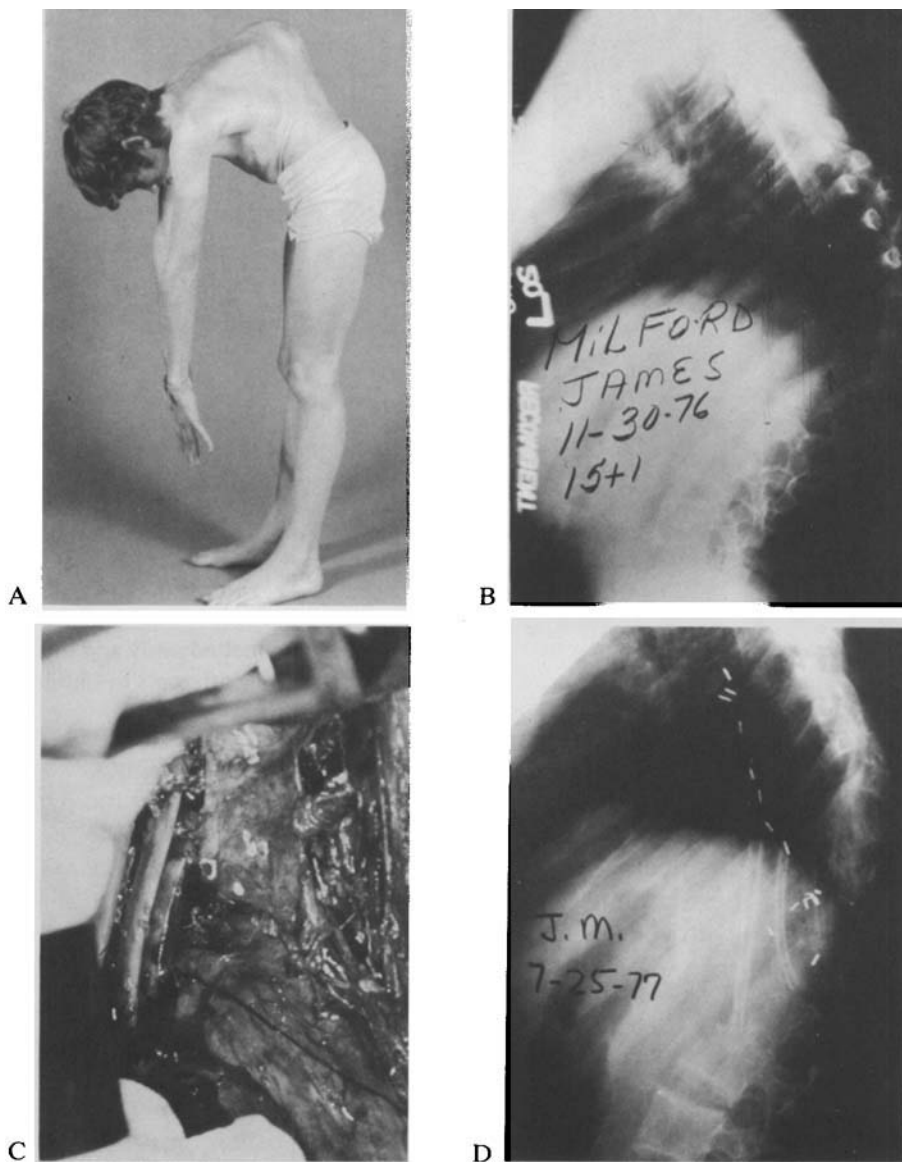
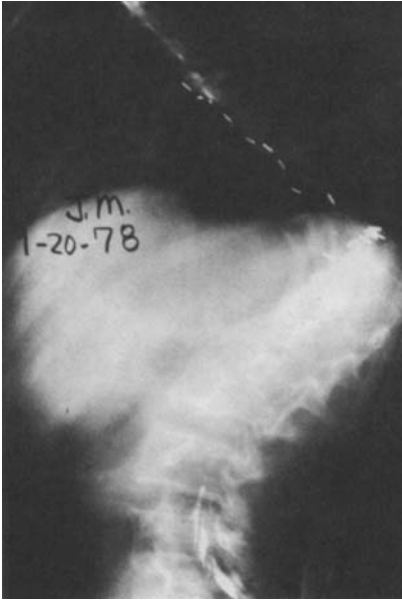


Figure 3. This child presented with a severe kyphoscoliosis after having undergone 3 attempts at posterior spinal fusion. The kyphosis was in excess of 100 degrees. He underwent an anterior spinal fusion with fibular and rib strut grafts. The fusion subsequently failed. It was felt that the cause of failure was resorption of the grafts by neurofibromatous tissue.

- A. Clinical photographs demonstrating the severity of the kyphosis from a lateral view of the bend test.
- B. The preoperative radiographs with line drawing demonstrating the proposed position of the fibular and rib grafts.
- C. An operative photograph at the time of thoracotomy demonstrating the nesting of the fibular and rib graft across the apex of the kyphus.
- D. Six months post-op showing the position of the fibula and rib grafts.

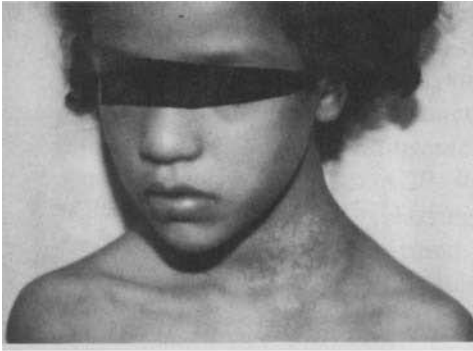

E. At 20 months post-op, the fibular and rib grafts have literally melted away and the initial kyphosis has recurred. This is not an unusual sequelae following attempts to stabilize the severe kyphoscoliosis associated with neurofibromatosis.

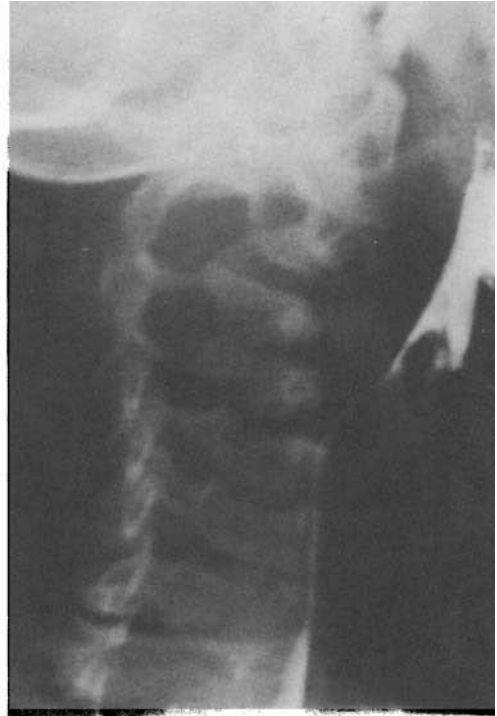Yong-Hing et al. reviewed 56 patients with neurofibromatosis from the Alfred I. Dupont Institute specifically for abnormalities of the cervical spine and found 17 to have lesions. Of 37 patients who had scoliosis or kyphosis, 15 had cervical spine lesions. Many of these patients were asymptomatic (143). Adkins & Ratvich reviewed 85 patients with von Recklinghausen's neurofibromatosis at the Children's Hospital of Pittsburgh and found that head and neck masses constituted 22% of the presenting problems (1).

Most patients with cervical spine anomalies are referred to an orthopaedict secondarily after having undergone excision of a neck mass, the preceding work-up having included an x-ray of the cervical spine showing considerable bony anomalies. Other reasons for presentation include torticollis and dysphagia (Figure 4). Only one of our patients was initially identified as having a cervical spine disorder while under treatment for scoliosis; however, 3 patients presented with neck masses and significant osseous cervical spine abnormalities.

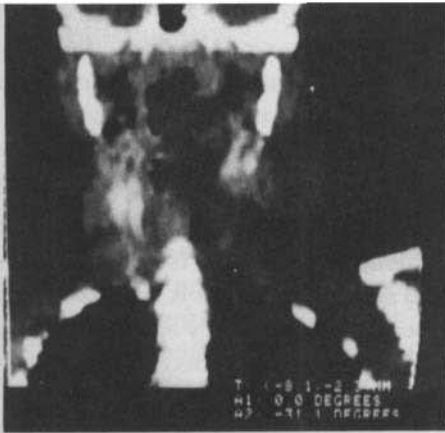Spondylolisthesis: Only 9 cases of spondylolisthesis due to neurofibromatosis have been reported, 2 by Hunt & Pugh (60), one by Mandell (77), one by Winter et al. (140), 4 by McCarroll (80), and one by Crawford (31). Only one of our patients (previously reported) was noted to have spondylolisthesis even though lateral radiographs of the lumbar spine were taken on all in our original A. I. Dupont series. This represents a lower incidence of the disorder than noted in the general population, i.e. less than 1% as opposed to approximately 5% in the average spinal deformity population.



A



B

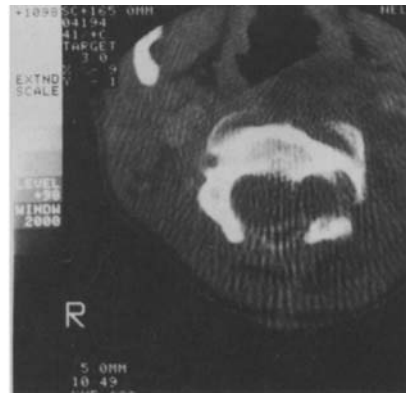
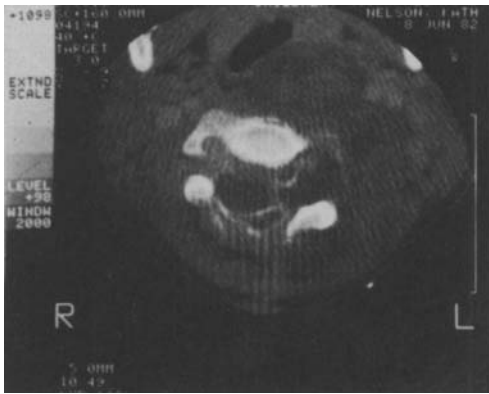


C

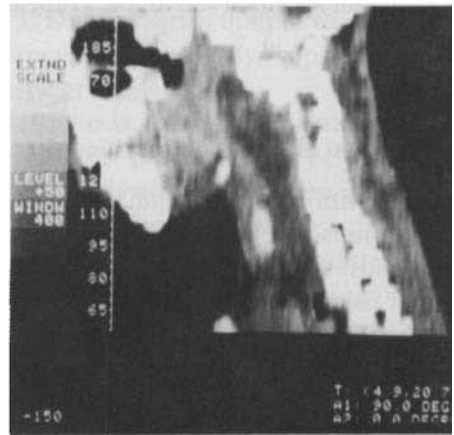

Figure 4. This child presented 3 years following excision of a mass of her left neck. The mass had recurred and she had difficulty swallowing.

- A. Note the fullness in the left anterior cervical triangle.
- B. An esophagogram demonstrated the outline of a prevertebral soft tissue mass. The enlargement of the neural foraminae infers that the mass is exiting from the spinal canal at multiple locations.
- C. Computed AP and sagittal tomography reveals the mass to be fairly extensive and extending from the C1/C2 level down to just beneath the clavicle. The increased density on the AP view impinging on the oropharynx is the mass.



D. A coronal cut through the level of the C2 vertebra. The child had previously undergone a laminectomy of C2 and the posterior elements are absent. Note the large densities in the anterior vertebral canal which represent the intraspinal neurofibroma. The small, flattened, densely outlined area posterior is the spinal cord.

The child had no evidence of neurological deficit. She subsequently underwent excision of the intraspinal neurofibroma by a laser technique and posterior spinal fusion, after which an anterior approach was carried out to remove the tumor that extended anteriorly from the level of C2 to just beneath the left clavicle. An anterior spinal fusion using the fibula was then carried out. The patient tolerated both procedures well. Her only neurologic deficit now is a positive Horner's sign to the left eye which occurred following the anterior approach and fusion. (Patient referred by Dr. Dan Bethem, Akron, OH).

Discussion of spinal deformities

I agree with others that spinal deformities of neurofibromatosis should be divided into 2 groups, i.e. those with dysplastic changes and those with no apparent dysplasia. The most serious spinal deformity complicating neurofibromatosis is severe dysplasia of the vertebral bodies, posterior arches, and spinal canal; this is most common in the thoracic area. These deformities may appear in early infancy and continue to increase into and after puberty. They may cause neurologic problems including paraplegia.

There have been relatively few clinical series discussing the treatment of spinal deformities in patients with neurofibromatosis. Winter et al. (140) reviewed the natural history, associated anomalies and response to open or closed treatment on 102 patients with neurofibromatosis and spine deformity. Eighty patients were found to have curvature associated with dystrophic changes in vertebrae or ribs. The presence of dystrophic changes such as rib pencilling, spindling of the transverse processes, vertebral scalloping, severe apical vertebral rotation, foraminal enlargement and adjacent soft tissue neurofibroma was found to be highly significant in prognosis and management. Brace treatment of dystrophic curves was unsuccessful. Posterior fusion, with or without internal fixation, was the procedure of choice for problems due clearly to scoliosis. Patients with dystrophic kyphoscoliosis required both

anterior and posterior fusion to achieve stability. Sixteen patients had compression of the spinal cord or cauda equina.

To manage those patients with dystrophic scoliosis associated with neurofibromatosis, I have the following recommendations. Those patients with a curvature of less than 20 degrees should be observed for progression at 6 month intervals. For those patients with greater than 20–40 degrees of angulation, a posterior spinal fusion of all articular facets with Harrington rod instrumentation or segmental spinal instrumentation should be performed. The patient should be radiographed at 6 months with oblique views taken to assess the fusion of the facet joints and to rule out a pseudarthrosis. If there is any question of failure of consolidation of fusion mass the patient should be reoperated and bone grafted. Savini et al. have noted the progression of dystrophic scoliosis to kyphoscoliosis and recommend anterior fusion in addition to repeat bone grafting for relapse after posterior fusion (113). Brace treatment has *not* been effective in the management of progressive dystrophic curves and should not be used. Even in young children, early fusion will cause minimal stunting of trunk height because the curves are usually short with very poor growth potential in the involved vertebra so one need not wait for the child to attain a certain physiologic or chronologic age (140).

The second group of scoliosis patients are those with deformity that are, in appearance, identical to idiopathic scoliosis. These curves have the same prognosis and evolution that idiopathic curvatures have, except that they have a higher risk of pseudarthrosis after fusion and possibly a greater progression with or without corrective treatment. It was noted in our original A. I. Dupont series that, as the patients matured, some of these curvatures had a tendency to take on a dystrophic appearance that was more characteristic of the dysplastic group.

My recommendation for managing idiopathic scoliosis accompanying neurofibromatosis is to treat it as an idiopathic curvature, i.e., the patient should be observed for curvatures less than 20 degrees and if there are no dystrophic changes, a brace is recommended for progression of the deformity up to 35 degrees. For those deformities between 35 and 45 degrees and over, I very strongly recommend a posterior spinal fusion of all articular facets using either Harrington instrumentation or segmental spinal instrumentation.

The patient with kyphosis in addition to scoliosis invariably has dysplastic changes. No patient in this series had paraplegia resulting from a kyphosis associated with progressive deformity. An attempt in one patient at anterior and posterior spinal stabilization failed. In this patient the kyphotic deformity had been temporarily stabilized by bracing, but the possibility of progression and paraplegia remains real. Rockower et al. have recently reported 2 patients who, because of loss of vertebral bodies secondary to neurofibromatous tissue encroachment, developed paraplegia (106). Immediate application of traction resulted in a reversal of the paraplegia. Traction should only be used with flexible kyphosis, never if the kyphosis is rigid. It was the conclusion of Winter et al. that dystrophic patients with angular kyphosis responded very poorly to posterior fusion alone and posterior pseudarthrosis repair was not successful in achieving stabilization. Good results were consistently obtained only on those patients who had both anterior and posterior fusion; however, not every

patient obtained solid initial fusion with both anterior and posterior procedures, several required repeat operative procedures. Winter et al. felt that technically inadequate anterior procedures were the usual reason for failure. Most important was the recommendation that the entire structural area of the deformity be fused anteriorly with complete disk excision and strong strut graft, preferably from the fibula as well as rib and iliac crest graft. They recommended no soft tissue be allowed to interpose between the grafts and all grafts should have contact with each other and with the spine. Those grafts surrounded by soft tissue tended to resorb in the midportion. Two of our patients with kyphoscoliosis have undergone a total of 7 procedures each, both anterior and posterior and have not obtained a stable spine at this time. Of 74 patients, 8 presenting with kyphoscoliosis have undergone a total of 24 procedures to date. Only 2 have what appears to be a bona fide fusion and are asymptomatic. Only one has reached skeletal maturity.

Because of the association of paraplegia with kyphoscoliosis there has been a tendency to perform laminectomies. Laminectomy for kyphoscoliosis cord compression is absolutely contraindicated. The inciting lesion is usually anterior and the compression cannot be visualized from behind. Also, the removal of the posterior element predisposes the patient to unstable post-laminectomy kyphosis and removes valuable bone stock required for posterior spinal fusion.

The recommendation for the management of kyphoscoliosis and neurofibromatosis is to initially rule out any evidence of an intraspinal lesion such as a pseudomeningocele with dural ectasia or an intraspinal neurofibroma (dumbbell tumor). These two lesions have been felt to account for the paraplegia encountered following conventional instrumentation. A complete high-volume myelogram in the prone, lateral, and supine position, CT scan or MRI, should be performed prior to surgical treatment. An anterior disc excision and bone graft followed by posterior arthrodesis and instrumentation should be performed if the kyphotic angle is greater than 50 degrees. One should extend the anterior fusion 1–2 levels past both end vertebrae. The patient should be reexplored posteriorly at 6 months with augmentation of the fusion mass if polytomography or bone scan shows any evidence of weakness of the fusion mass.

For those patients presenting with paraplegia and neurofibromatosis one has to first rule out an intraspinal lesion (tumor, meningocele) versus kyphotic angular cord compression (108). A high volume myelogram is done in the prone, lateral and supine positions with assisted axial computerized tomography. If the kyphosis is mobile the patient should be placed in halo-assisted traction. This is to be done with extreme caution and should definitely not be performed if the kyphosis is rigid. If a tumor is anterior, then immediate anterior decompression and fusion should be carried out, whereas if the lesion is posterior, a hemilaminectomy with tumor excision and posterior spinal fusion are to be carried out. The posterior fusion should be performed with addition of Harrington or segmental spinal instrumentation. The patient should be observed very carefully for a pseudarthrosis, and augmentation of the bone graft should be carried out directly if such evidence presents.

The cervical spine disorders are primarily those of kyphosis. Three of our patients presented following excision of a mass in the anterior cervical triangle. We now re-

commend AP and lateral radiographs of the cervical spine with the original evaluation of all spinal deformities in neurofibromatosis. If dysplasia is noted, lateral flexion and extension x-rays should be obtained to rule out instability. One should be extremely concerned of posterior scalloping of the vertebral bodies or increase in the size of the neural foramina, thus indicating the presence of a spinal neurofibroma. These lesions cause significant compression to the spinal cord and their removal has presented considerable technical difficulties to the surgeons. Five cases of atlanto-axial dislocation have been reported in patients with neurofibromatosis, 2 of which were noted to have neurofibromata between the odontoid and anterior arch of C1 (109, 61, 143). With the use of the laser we are now able to remove neurofibromata in this region without compromise to the spinal cord. Because of the amount of bone removal required to completely remove the tumor and the resulting instability, a spinal fusion should always be carried out, oftentimes requiring an occipital cervical fusion. All 4 patients who presented following decompression laminectomy had progressive kyphotic deformities. A halo device may be utilized to stabilize the occipital cervical thoracic area until fusion takes place.

Intrathoracic meningocele, dural ectasia and dumbbell lesions

An intrathoracic meningocele is relatively rare; less than 50 cases are reported in the English literature. Pohl reported the first case of an intrathoracic meningocele associated with neurofibromatosis. Radiographically, with myelography, a soft tissue mass is seen protruding from the spinal canal into the posterior mediastinum (95). Structural defects in the pedicle, enlargements of the intervertebral foramina, and abnormalities of the vertebral bodies may accompany the masses (77).

The scalloping of the vertebral bodies with deformity of the pedicles and widening of the intervertebral foramina could be caused either by the presence of dumbbell tumor (intraspinous neurofibromas) or saccular dilatations of the dura, "dural ectasia". No case of intrathoracic meningocele was noted in our series; however, 2 of the patients seen in consultation had this deformity (Figure 5).

Discussion

When one sees scalloping and indentation of vertebral bodies, a very careful investigation should be carried out for an intrathoracic meningocele or dumbbell lesion. The scalloping has been associated with intraspinal neurofibroma as well as with the expansion of the dural sac suggesting a meningocele. Scalloping can exist without either of the above-mentioned eroding factors. The implication is that this deformity is primarily a vertebral or developmental defect associated with neurofibromatosis and not dependent on pressure erosion. Because some intraspinal studies with myelography have shown the contrast material to not conform to the posterior scalloped surfaces of the vertebra, there is a suggestion of an intervening intradural mass. The vertebral scalloping and hyperplasia may be signs of mesodermal dys-

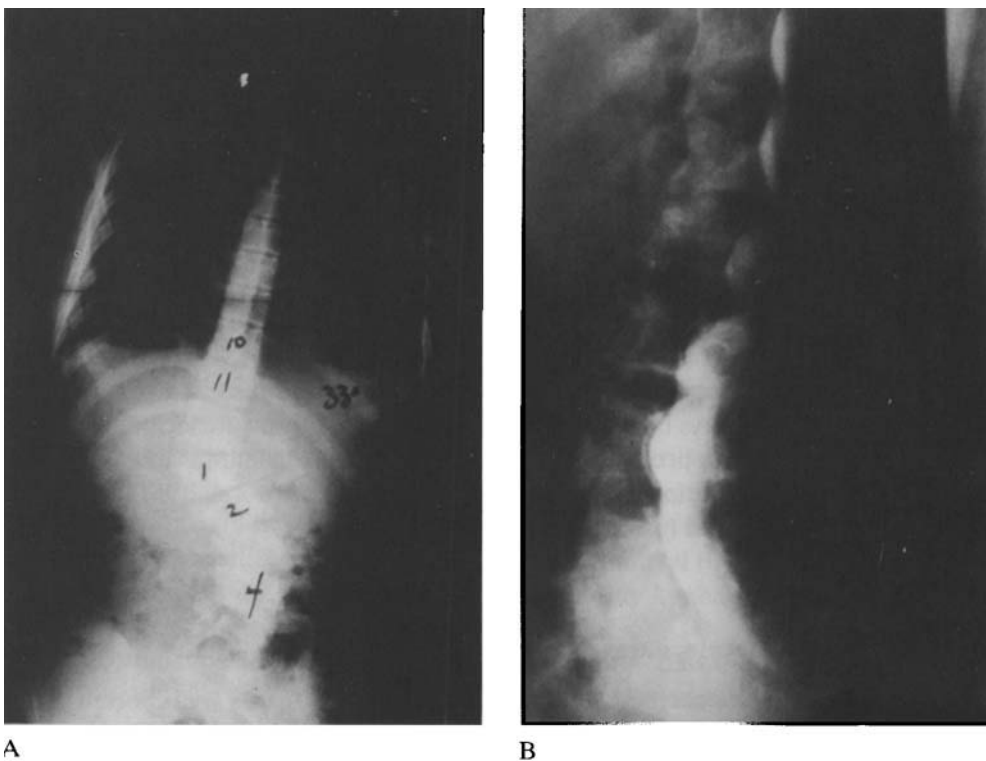


Figure 5. A short segmented double primary scoliosis associated with neurofibromatosis. The lateral view shows significant scalloping of the posterior vertebral bodies and increase in the AP diameter of the neural foramina and spinal canal.

- A. The double primary curvature extending from T11 to L4. Note the sharp wedge-shaped margins of the vertebral bodies suggesting extrinsic pressure.
- B. An oblique view of the myelogram demonstrating the dural ectasia and pressure erosion of the vertebral bodies.

plasia or an indirect manifestation of a proximal tumor. Because of the possibility of an intraspinal tumor or dural ectasia, it is strongly recommended that high volume myelography be performed on those patients with dystrophic curvatures requiring instrumentation and fusion (140).

Angtuaco et al. have recommended CT myelography for patients with neurofibromatosis (8). Myelography alone can help differentiate between a mass lesion and the pseudomeningocele-like pattern of dural ectasia. With CT, additional details such as displacement of the spinal cord and the extent of involvement of the subarachnoid compartment by tumor can be assessed. Klatte et al. have attempted to elucidate the cause of posterior scalloping of the vertebrae in neurofibromatosis by CT. They stated that eccentric unilateral scalloping favors a neurofibroma whereas central scalloping occurs more frequently in dural ectasia (65).

The author recommends CT assessment of any areas demonstrated by myelogram to be suspicious and/or those areas poorly demonstrated on complete myelogram

due to dilution of contrast material. The MRI offers an image technique capable of simultaneous assessment of all elements in a single non-invasive study.

Disorders of bone growth and associated soft tissue changes

The “Elephant Man” was the most publicized patient with neurofibromatosis in medical history. Beginning in 1884, Sir Frederick Treves described this miserable, grotesque creature, repeatedly calling attention to his large, misshapen head. Treves, a British surgeon, is renowned for his kind assistance to the Elephant Man, Joseph Carey MacDonald Merrick (called “John” in the movie). Merrick was afflicted by neurofibromatosis with a profound disorder of facial bone growth, and he traveled with freak shows. Actually, Treves did not realize at the time that his patient had von Recklinghausen’s disease (127, 128, 129, 130). It remained for Weber, the illustrious dermatologist with remarks on the classification of incomplete and anomalous forms of von Recklinghausen’s disease, to point this out later (133). Disorders of bone growth are quite frequently associated with changes in the soft tissue overlying the bony deformity (16, 20, 38, 91, Goel M K, unpublished data). Dermatologists, who often see these patients initially, should be encouraged to look for previously unrecognized bony manifestations of the disease (Figure 6).

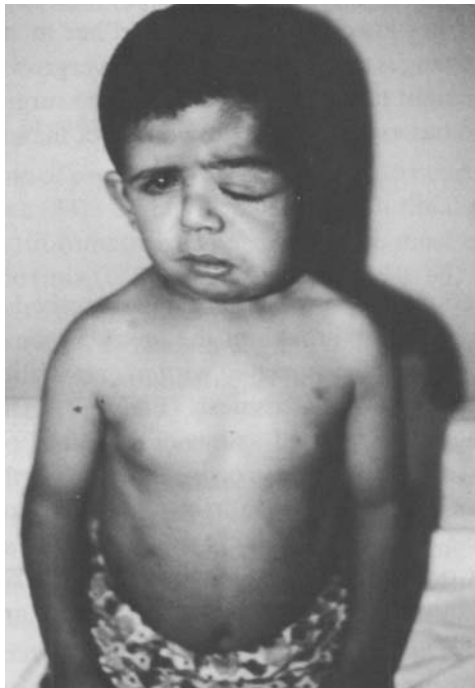


Figure 6. Unilateral facial overgrowth. This very young patient demonstrates the characteristic tremendous overgrowth of one side of his face with distortion of facial features. Except for café-au-lait spots, there were no other manifestations of neurofibromatosis at this time.

The zones of overgrowth in bone and soft tissue are usually unilateral involving the lower extremities or head and neck. Riccardi has described these lesions as a segmental form of neurofibromatosis (104). The osseous changes characteristically cause the bone to be elongated with a wavy irregularity of the cortex, which may be thickened. The diffuse hypertrophy of an extremity may first demand the attention of an orthopaedic surgeon. Eighteen of our patients, or 16%, had limb length discrepancies of which 4 had associated elephantoid changes or dermatological findings.

The changes that can be found in the soft tissues associated with the bony overgrowth are hemangiomatous lesions, lymphangiomatosis, elephantiasis or, occasionally, beaded plexiform neuromas.

Wehbe and Mickelson have reported malignant Schwannomas associated with disordered bone growth (134). The incidence of malignant degeneration cited in the literature varies greatly. Crowe et al. found sarcoma in 2% of 227 cases. The incidence was much higher (16%) when only those lesions associated with plexiform neuromas were considered.

The most impressive disorders of bone growth included patients who had co-existent pachydermatocele or elephantoid skin characteristics. Two of the patients with a combination of bony overgrowth and elephantoid skin changes subsequently developed retroperitoneal sarcomas. One, now only 5 years of age, has had 4 retroperitoneal explorations for recurring neurofibromas. She subsequently required a colostomy and recently underwent a hip disarticulation amputation because the tremendous overgrowth of her lower extremity caused her to stop walking. The one patient not having skin changes associated with bony overgrowth developed progressive enlargement of her right mandible. After 16 plastic surgical procedures, she is still quite disfigured and has asymmetrical growth of her mandible.

Treatment

I strongly recommend epiphyseal arrest as the initial method of treatment of those patients with excessive bony overgrowth of the lower extremities. Attempts at removal of the excessive soft tissue associated with overgrowth of the lower limb has not necessarily resulted in improved cosmesis (Figure 7). The possibility of these children being subsequently diagnosed as having a central or peripheral nervous system neoplasm has led me to a more aggressive approach to their problem, i.e., debulking or amputation procedures in an effort to allow them to function as best they can while young because of the possibility of a significantly shortened life span. I would recommend *not* performing shortening procedures requiring through the bone surgery because of the strong possibility of non-union and pseudarthrosis developing.

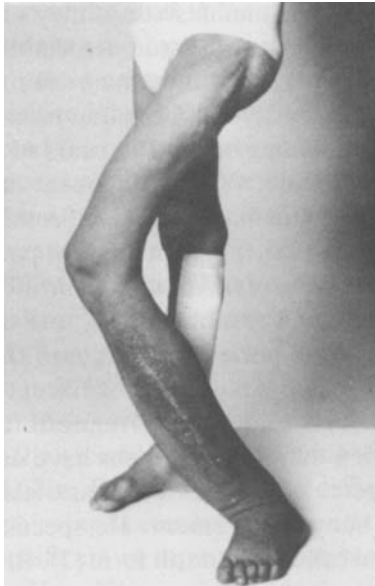

Figure 7. Child with limb overgrowth following a subperiosteal hematoma who underwent a debulking of the soft tissues of his leg in an effort to achieve improvement in appearance. The healing time of the incision was tremendously prolonged with some residual scarring taking place. Needless to say, the cosmesis has not been significantly improved. (Courtesy of Dr. Luis Dias, Chicago, IL)

Congenital bowing and pseudarthrosis

History: The relationship of pseudarthrosis of the tibia to neurofibromatosis was first described by Ducroquet (34). Of his 11 patients with tibial pseudarthrosis, 9 had manifestations of neurofibromatosis. The single bone most commonly affected by neurofibromatosis is the tibia (6, 7, 10, 29, 30, 31, 35, 50, 53, 79, 80, 81, 82, 83, 87). Other affected bones have been reported such as the ulna (4, 25, 76), femur (60, 86), clavicle (5, 70), radius (47, 78, Rankin E, unpublished data) and humerus (86). Pseudarthrosis may develop spontaneously, after fracture or after osteotomy of the involved bone.

Clinical manifestations: The bowing of the tibia in neurofibromatosis is characteristically anterolateral and is usually evident within the first year of life. Holt found congenital pseudarthrosis of the tibia with anterolateral bowing to be ultimately associated with neurofibromatosis in 97% of his cases (58). On the other hand, congenital bowing in a posteromedial direction, "kyphoscoliosis tibia", is a benign condition only occasionally associated with limb length inequality but rarely, if ever at all, associated with pseudarthrosis. Those tibial pseudarthroses associated with skin dimples, those that are bilateral, those that have posterior medial bowing and ring constrictions, have no association with neurofibromatosis. The diagnosis of congenital pseudarthrosis of the tibia is made quite early (under 2 years) with usually no evi-

dence of neurofibromatosis. Other manifestations may subsequently occur, such as café-au-lait spots and other bony or soft tissue deformities. The sex distribution is equal in tibial pseudarthrosis with and without neurofibromatosis. The average age of tibial fracture is approximately 1 year. Only one pseudarthrosis of the tibia has been reported in a patient presenting beyond 11 years of age (12). This was caused by a fracture in a 41 year old male. Fifty-five percent of patients with congenital pseudarthrosis can be diagnosed as having neurofibromatosis. Pseudarthrosis has also been reported as familial (138). Forty percent of patients with neurofibromatosis and tibial pseudarthrosis have relatives with neurofibromatosis (32).

The cause of pseudarthrosis is questionable. At one time it was thought that a neurofibroma growing within the bone cortex, caused the fracture and interfered with union, eventually resulting in pseudarthrosis. Except for the case of Green and Rudo (47) in which the histologic study showed neurofibromatotic tissue growing in a pseudarthrosis segment, few surgical specimens have neurofibromatotic tissue at the pseudarthrosis site. Aegeter believed that the basic lesion was in the surrounding soft tissue with secondary bony involvement. He speculated that if all the tumor tissue were removed, normal callus would still form (3). Bruner and Yunis examined by electron microscopy the soft tissue removed from 3 patients with tibial pseudarthrosis and found fibroblasts rather than Schwann cells or perineural cells. These findings differed from the true neurofibromatosis and neurolemmoma in which both Schwann cells and fibroblasts, as well as occasional unmyelinated axons, are found (19). Tibial pseudarthrosis and neurofibromatosis associated with other skeletal problems are rare, only 5% found to accompany scoliosis.

Treatment principles: Congenital tibial pseudarthrosis presents a difficult problem. The union rate for patients treated surgically for congenital tibial pseudarthrosis has not changed with or without the diagnosis of neurofibromatosis having been made. Many surgical procedures to improve alignment and to internally stabilize the bone fragments have been described. Few satisfy the basic requirements of stability of fixation and promotion of osteogenesis (10, 79, 92). The widely used methods include massive on-lay grafts (53), dual autogenous on-lay (64), trough with chip graft (49), delayed autogenous on-lay (64), bypass (37), fragmentation, and turn-around plasty (120).

Charnley used an intramedullary nail for better fixation (23). Langenskiöld devised a procedure for stabilizing the ankle by fusion of the distal tibial and fibular metaphyses (68). Lloyd-Roberts & Shaw suggested pre-fracture grafting of the kyphotic tibia as a means of preventing pseudarthrosis (72).

Lavine and others have reported on the application of pulsating electromagnetic fields to the pseudarthrosis defect (69). Both internal and external sources of electric current have been utilized recently. The success rates vary with the length of follow-up. The initial successes have not been substantiated (11, 18, 65, 69).

Recent advances in the field of microsurgery have permitted the transfer of massive segments of bone along with accompanying nutrient vessels to a distal recipient site with preservation of the blood supply by microvascular anastomosis to recipient vessels. With the nutrient blood supply provided, osteocytes and osteoblasts in the

graft can survive and healing of the graft in the recipient site will be facilitated without the usual replacement of the graft by creeping substitution (136). The contralateral fibula has been used in most cases with early results being quite encouraging. Most recently, Leung has utilized the vascularized iliac crest as a transplant for small defects of less than 7 cm, and the contralateral fibula for those defects greater than 7 cm. He felt that the technical ability to achieve reimplantation with vascular anastomosis was easier with the pelvis bone because of the size of the vessels (71).

Most of the preliminary reports of microvascular bone transplants are encouraging; however with longer follow-up, there has been a tendency for pseudarthrosis to occur above and/or below the united vascularized segment.

Morrisey et al. reviewed 40 patients who were treated over 25 years by several different surgeons. 162 bone grafting operations were performed on their 40 patients; however, they were not able to recommend one method as being superior to the other. The chief difficulty they found was in achieving union between the graft and the short distal segment of tibia. They found it most difficult to decide when to abandon further attempts at achieving union and to amputate the leg (89). Two factors emerged as statistically significant in separating acceptable from poor results: age and segmental length (88). The older the patient at the time of his last graft, the less likely he was to achieve union, and no patient who was still being grafted at 13 years of age achieved an acceptable result. Other authors have felt that the older the child at the time of bone grafting, the better the chance of success, and the later the fracture occurs the better the results (53, 65). Significant shortening also represented an unacceptable result. The shortening is noted to be associated with abnormal growth of the distal tibial epiphysis. The fact that the graft usually failed distally and there was decreased uptake by bone scan of the distal physis suggested that there was a physiologic disturbance in the physeal region of the distal tibia. The high incidence (25%) of subsequent development of central nervous system gliomas in the Morrisey et al. (89) series caused them to reflect as to whether or not enthusiasm in continued attempts at bone grafting should be carried out as the patient got older. Andersen felt that patients with dysplastic anterolateral bowing and neurofibromatosis who achieved solid bony union had complaints centered around the leg length discrepancy, limitation of ankle motion, pain in the ankle joint, and atrophy of the leg and foot. If union was not achieved after 3 or 4 grafting procedures or before the age of 7 years, the benefit of further procedures should be questioned (6).

Andersen further reviewed 21 cases of congenital pseudarthrosis of the tibia and found all cases of the dysplastic type (Crawford types II-B and II-C) showed evidence of neurofibromatosis. His most significant observation concerned those patients without dysplastic changes (Crawford type I) who had positive diagnosis of neurofibromatosis and underwent corrective osteotomies. The radiographs from before the osteotomy showed typical anterolateral bowing but no obvious dysplasia. Three cases underwent corrective osteotomy, and all resulted in pseudarthrosis (7). One of our cases of anterolateral bowing with no evidence of dysplasia underwent corrective osteotomy only to be followed by pseudarthrosis. It should be emphasized that children with congenital anterolateral bowing of the lower leg *should not* have corrective osteotomy unless the indications are very well substantiated, and the extremely great risk of pseudarthrosis has been seriously considered (Figure 8).

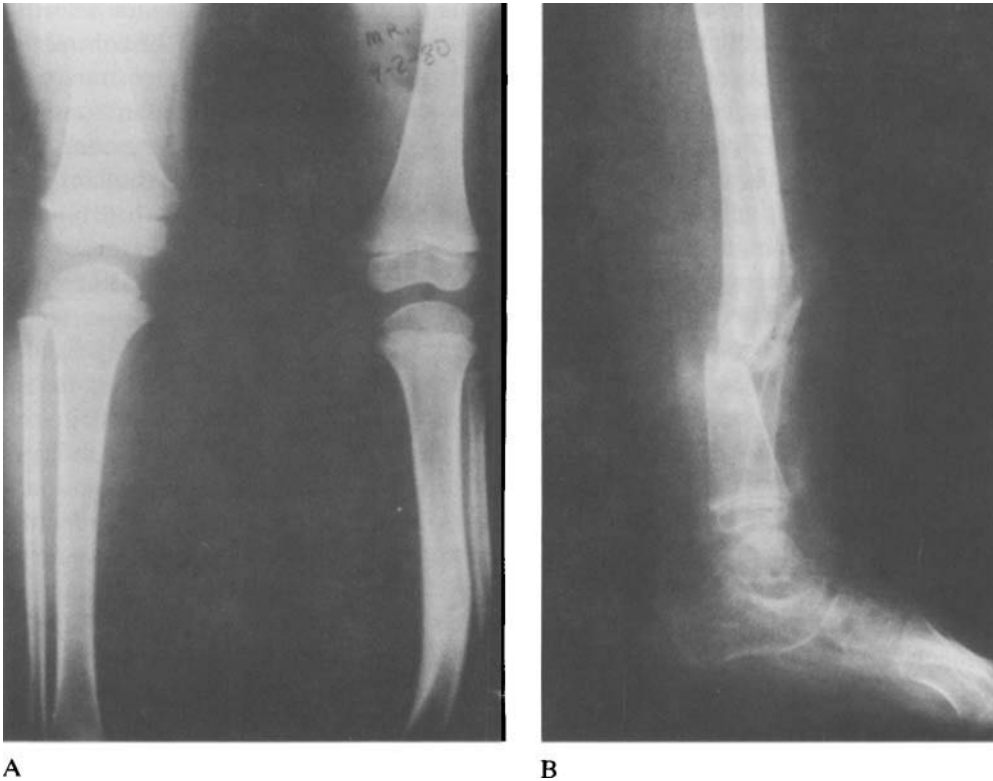


Figure 8. This child was noted to have an anterior lateral bow of the tibia and neurofibromatosis. Because of some concern for the bowing deformity, an osteotomy was performed. A pseudarthrosis developed following the osteotomy and has failed to unite despite prolonged application of pulsating electromagnetic fields.

- A. Anterolateral bowing with increased bone density (Crawford I).
- B. Following corrective osteotomy and bone graft, both the tibia and fibula went on to develop a frank pseudarthrosis. Note the development of sclerosis of the proximal and distal pseudoarthrotic ends of both the tibia and fibula with osteopenia of the inferior tibial/fibular fragments and foot. Osteotomy for the correction of anterior lateral bowing of the tibia when associated with neurofibromatosis is to be strongly condemned.

It has quite often been stated that osteosynthesis could be achieved in those patients with tibial pseudoarthrosis lesions by resection of the pseudoarthrosis, bone grafting, Boyd amputation and immediate weight bearing (36). It was felt that the ability to directly compress the pseudoarthrosis site with direct weight-bearing would lead to early union. Jacobsen and Crawford et al. recently reported on 8 cases treated by through the ankle amputation, bone grafting, and direct weight bearing. None of the patients in their series achieved union by this method (62) (Figure 9).

Patient material and classification: Fifteen patients presented with angular deformities of the tibia under 2 years of age. These included 6 frank tibial fractures, 8 pseudoarthroses, and one with anterolateral bowing (prepseudoarthrosis). The treatment of

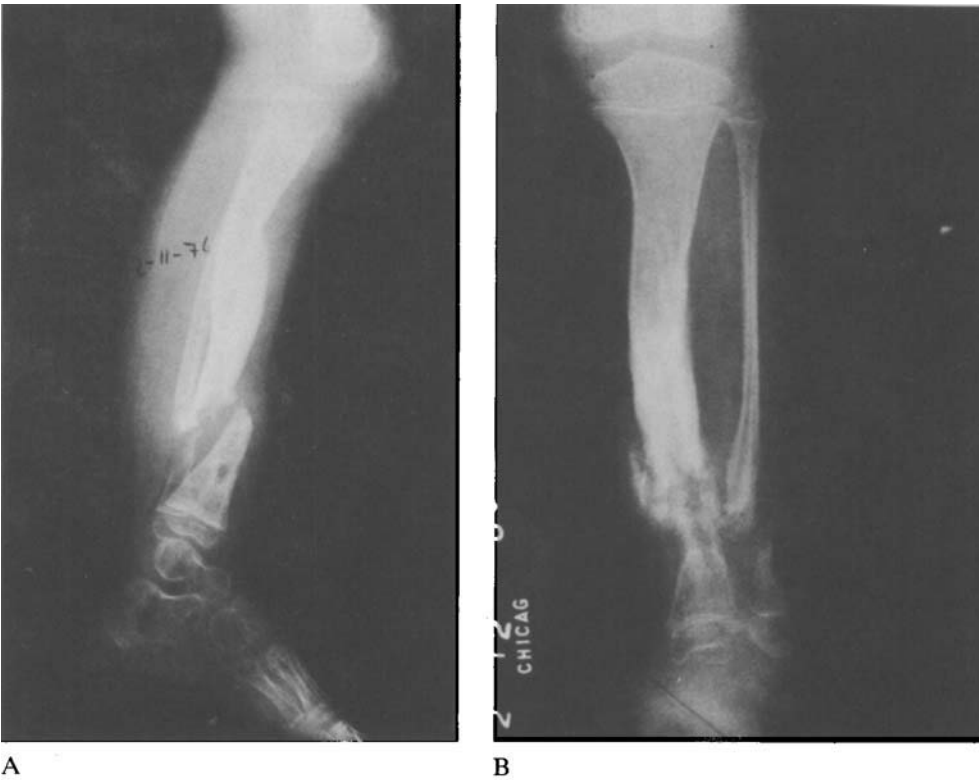

Figure 9. This child presented with a dysplastic anterolateral bowing of the tibia associated with neurofibromatosis and underwent 8 attempts at synostosis. It was felt that if the foot were amputated and bone grafting carried out with immediate weight bearing, the lesion would finally heal. Three and 1/2 years following foot amputation, bone grafting and prosthetic fitting, the pseudarthrosis has shown no evidence of uniting.

- A. A lateral radiograph showing the fixed pseudarthrosis after multiple attempts at bone grafting.
- B. Three and 1/2 years after final bone grafting and Boyd-Symes amputation had been performed. There has been no healing of the bone following the procedures.

7 of these patients has been reported by Rathgeb and others (98). Attempts were made to classify the radiographic appearance of the lesion and prognosticate its response to treatment.

Thirty-one surgical procedures were performed, including on-lay grafting, multiple osteotomies, plate fixation, below knee amputation, application of electric current (Osteostim®), and vascularized fibular transplants. Four radiographic types of pseudarthrosis tibia were identified (Figure 10). These deformities can be separated into dysplastic and non-dysplastic types.

I

II A

II B

II C

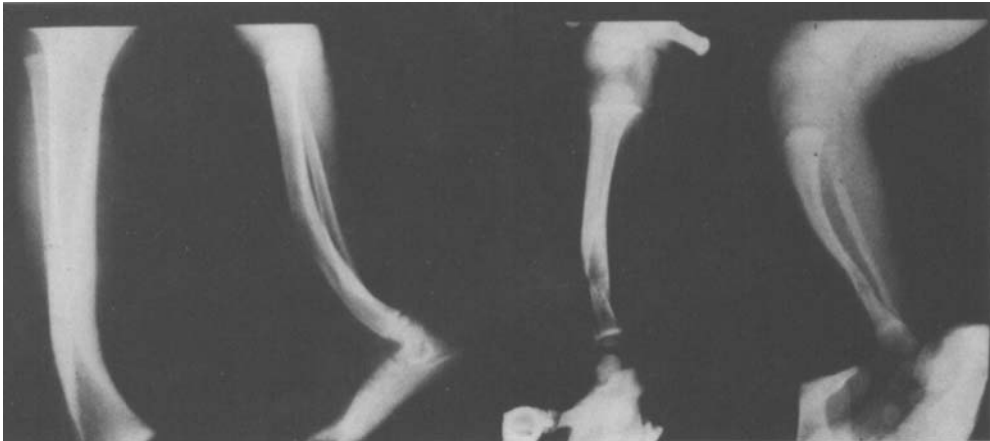


Figure 10. Classification of congenital tibial pseudarthrosis.

- Type I: Anterolateral bowing with increased bone density in area of medullary canal. These patients have the best prognosis, can usually be followed without bracing, and may never have a fracture.
- Type II-A: Anterolateral bowing with failure of tubulation. These patients inevitably have a fracture. They should be protected from the time the diagnosis is made.
- Type II-B: Anterolateral bowing with post fracture cystic lesion.
- Type II-C: Anterolateral bowing with dysplastic constriction or frank pseudarthrosis of both the tibia and fibula.

The types II-B and II-C lesions characterize the dysplastic pseudarthrotic lesion and have been the most difficult ones to obtain a lasting union by any means.

Type I (Non-dysplastic) – Anterolateral bow with dense medullary canal. These patients have the best prognosis, can usually be followed without bracing, and may never have a fracture.

Type II-A (Dysplastic) – Anterolateral bowing with increased medullary canal width and a tubulation defect. These patients should be protected from the time the diagnosis is made, and prepared for surgical intervention, possibly prophylactically.

Type II-B (Dysplastic) – Anterolateral bow with a cystic post fracture lesion. This lesion represents early healing of a previous fracture. These patients should have early bone grafting because of their tendency to early fracture with the resulting dire consequences.

Type II-C (Dysplastic) – Anterolateral bow with fracture, cysts, or frank pseudarthrosis. These patients have the worst possible prognosis. All aspects of the patient must be considered in the eagerness to achieve union. The number of operations and

length of hospitalization must be carefully considered in terms of whether the psychologic costs are a fair price to pay for the anticipated result. Some form of amputation should be considered early in the course of treatment. Some of the happiest patients have had amputations, particularly those who had experienced several operations requiring prolonged confinement. Observation of children with similar problems who have undergone amputation often helps the psychological effect on the patient and the family.

Results: The relationship of tibial pseudarthrosis or congenital anterolateral bowing of the tibia to neurofibromatosis cannot be over-emphasized. Usually the patients with the condition under 2 years of age have no evidence of neurofibromatosis at that time. One of our patients with congenital pseudarthrosis felt not to be associated with neurofibromatosis had undergone 8 procedures before she started to manifest café-au-lait spots at 8 years of age. She subsequently, as a teenager, developed fibroma molluscum. Because of the considerable shortening and disfigurement of her leg, despite obtaining union after the tenth procedure, she elected to have an amputation. Unfortunately, she subsequently presented with a neck mass diagnosed as a neurofibrosarcoma.

We have recently undertaken the treatment of congenital pseudarthrosis tibia associated with neurofibromatosis by external application of pulsating electromagnetic fields using the Electrobiolgy® unit. We followed a child who presented with a dysplastic lesion and treated her by application of a polypropylene ankle-foot-orthosis at 6 months for daily wear, and applying the clamshell Electrobiolgy® by night. She is now 5 years old and has not sustained a fracture.

Two patients have undergone vascularized fibular transplants. Both achieved dramatic initial success only to be followed within a 12 month period by increased areas of radiolucency at the junction of the healing graft requiring repeat bone grafting at the proximal or distal segment of the partial synostosis (Figure 11).

Recommended treatment: I now recommend that all patients presenting with anterior lateral bowing associated with neurofibromatosis be placed in a well-molded polypropylene lower extremity orthosis. If the lesion shows evidence of dysplasia with either the presence of a cyst or a fracture, we then place the Electrobiolgy® clamshell external electromagnetic field unit over the limb at night. For those children over 3 years of age presenting with a frank pseudarthrosis of the tibia and fibula, a vascularized fibular transplant from the opposite limb is recommended. Support is continued in an orthosis following synostosis of the graft until skeletal maturity. I would *strongly recommend* against corrective osteotomy of the anterior lateral bowing deformity under any circumstances because of the high pseudarthrosis rate. When amputation is inevitable or following 3 surgical attempts at pseudarthrosis, I recommend a through the ankle amputation of the Boyd-Syme's type because of its increased length allowing for greater biomechanical advantage for prosthetic wear and the avoidance of stump overgrowth always found in skeletally immature through-the-bone amputees.

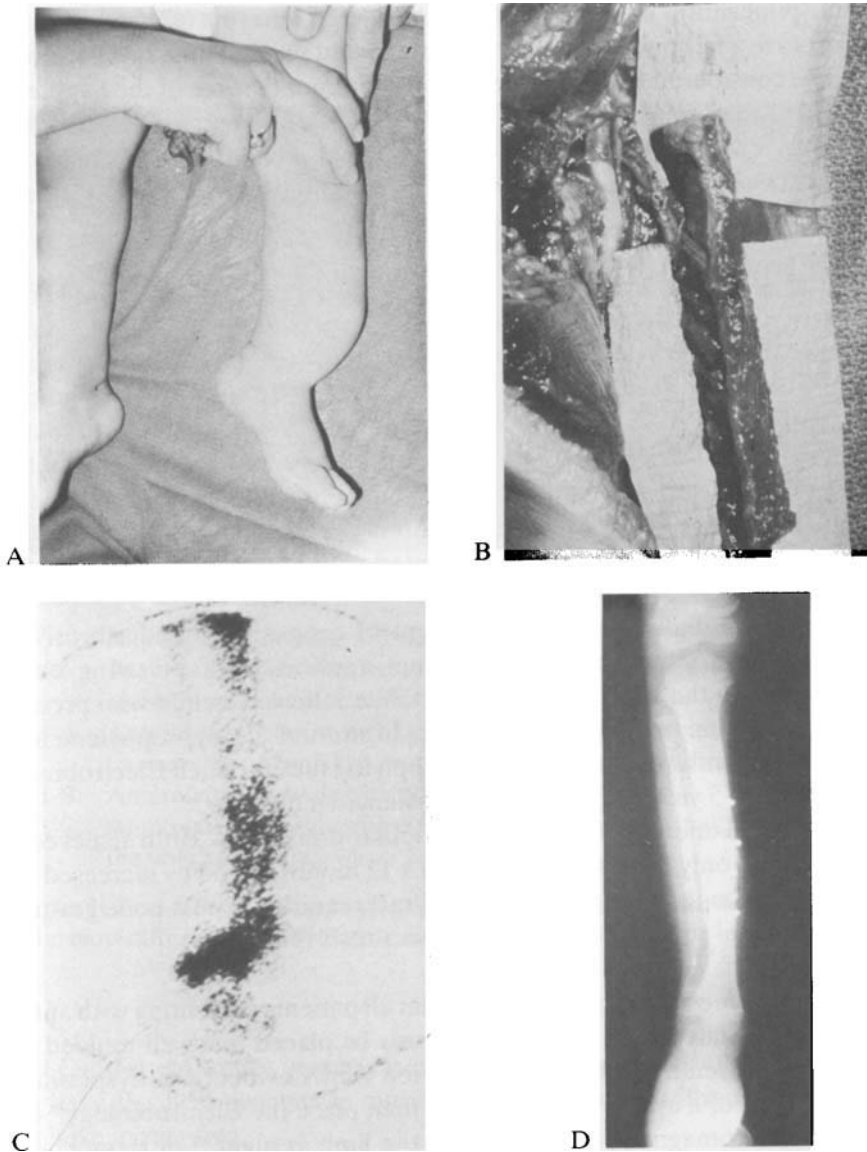


Figure 11. This is a child who presented as an anterolateral bowing with pseudarthrosis of the tibia and fibula and underwent a vascularized fibular transplant.

- A. Anterolateral bowing deformity and shortening of the limb.
- B. The completed anastomosis of the donor fibular nutrient vessel to the recipient peroneal artery.
- C. A bone scan demonstrating perfusion of the free fibular graft. The graft was affixed to the tibia with a compression plate.
- D. Radiograph 18 months post-operatively shows hypertrophy of the transplanted fibular graft. Note the frank pseudarthrosis of the adjacent fibula. A pseudarthrosis developed just below the synostosed graft at 2 years postop. It appears to be responding at this time to a bone grafting procedure. (This case courtesy of Dr. Peter Stern, Cincinnati, OH)

Erosive defects of bone from contiguous neurogenic tumor

Erosive defects are considered by some authors as the most characteristic bone change in neurofibromatosis (20, 43, Goel M K, unpublished data). Nogaard (92) described these lesions as a pit or cave in the bone. There is some controversy as to whether or not they are a true cystic lesion of neurofibromatosis versus an erosion from a contiguous tumor. The problem arises as to whether or not the lesion is an intrinsic cyst, one resulting from pressure erosion from an adjacent peripheral nerve, (a) with neurofibromatotic involvement, (b) secondary overgrowth of the periosteum, and (c) free cyst formation in response to the extensive neurofibromas, or a cyst resulting from direct invasion of the periosteum by plexiform neuroma and infiltration of the cortex and Haversian canals by neurofibromatous tissue. It is now felt that lesions once thought to be cystic are mechanical erosions of directly contiguous tumors. Various radiolucent lesions occurring in conjunction with true neurofibromatosis (e.g. fibroxanthomas) are presently thought to be coincidental (65). As a result of reviewing the radiographic features of neurofibromatosis in more than 500 cases Holt has deleted, at least temporarily, the heading of *intraosseous cystic lesion* from his classification (58).

Only one of our patients presented with a true cyst which happened to be a unicameral bone cyst of the proximal femur. The child underwent curettage and bone grafting. No neurofibromatous tissue was noted in the curettings. Several patients were noted to have radiographic cystic lesions of long bones secondary to pressure from contiguous neurofibroma. These patients have all been treated by observation only and, thus far, the lesions have shown no evidence of enlargement or progression.

Subperiosteal bone proliferation

Among the protean manifestations of multiple neurofibromatosis is the occurrence of the subperiosteal bone proliferation described by Brooks and Lehmann (20). Two cases were described in their original report; others have reported similar lesions (45, 56, 57, 67, 73, 80, 94, 111). Most cases are felt to be initiated by minor fractures with subperiosteal bleeding followed by osseous dysplasia of the subperiosteal hematoma. The lesion is quite rare and its etiology is unknown. Yaghmai and Tafazoli demonstrated angiograms which showed only stretching and displacement of blood vessels (141). This tends to support the Pitt et al. (94) contention that the hemorrhage is due to a mesodermal dysplasia involving the periosteum rather than an intrinsic vascular abnormality. There is no evidence to prove that there is infiltration of the periosteum by plexiform neurofibroma as previously suspected.

Patients:

We have noted a total of 5 such lesions in our series, 3 of which have been previously reported (94). One of these occurred in a boy with scoliosis and bony overgrowth of the left tibia with a subperiosteal cortical cyst; he underwent a spinal fusion and was scheduled for a tibial physodesis; however he never returned for follow-up. An-

other patient was first seen because of enlargement of the right tibia and fibula, café-au-lait spots, and verrucous skin hypertrophy. He was treated at 8 years of age with a physodesis of the right tibia and fibula; however, the bone continued to grow. He subsequently developed a Charcot joint of the right ankle.

All 5 of these patients had elephantoid overgrowth of soft tissue and pachydermatocele formations. They also had persistent continued overgrowth of the bone once cystic subperiosteal involvement occurred.

The recommended treatment for these lesions is supportive, i.e., contralateral shoe lift, etc., and careful observation. AP, lateral and oblique lumbosacral radiographs should be obtained for lower extremity lesions and cervical spine films for upper extremity lesions for evidence of enlargement of the neuroforamina and dumbbell tumor formation. CT and MRI should be used if plain films are positive. The bone proliferation and overgrowth may be associated with Schwannomas or plexiform neuromas. Physical arrest is carried out when overgrowth reaches 10%. The limb may grow beyond bodily proportion and amputation may be necessary.

Neoplasia

Any study of a large series of patients with neurofibromatosis will reveal soft tissue neoplasms. Despite the frequency of café-au-lait spots, the single most common criterion leading to the diagnosis of neurofibromatosis has been parental recognition of a growing mass (1, 41, 57, 84, 118). Most of the neoplasms are neurogenic and are either central or peripheral in location. The tendency for these lesions to undergo malignant change has been cited by others (84, 123).

The list of malignant tumors associated with neurofibromatosis is growing. Added to non-neural crest malignancies known to be associated with neurofibromatosis are rhabdomyosarcoma of the urogenital tract and non-lymphocytic leukemia (9, 82, 121). Wilms' tumor has also been found in patients with neurofibromatosis. It has been suggested that the association of Wilms' tumor in neurofibromatosis reflects the geographic proximity of the metanephric tubule and primitive neural element and that chordoma in neurofibromatosis may reflect the embryonic proximity of the notochord and neural crest (121).

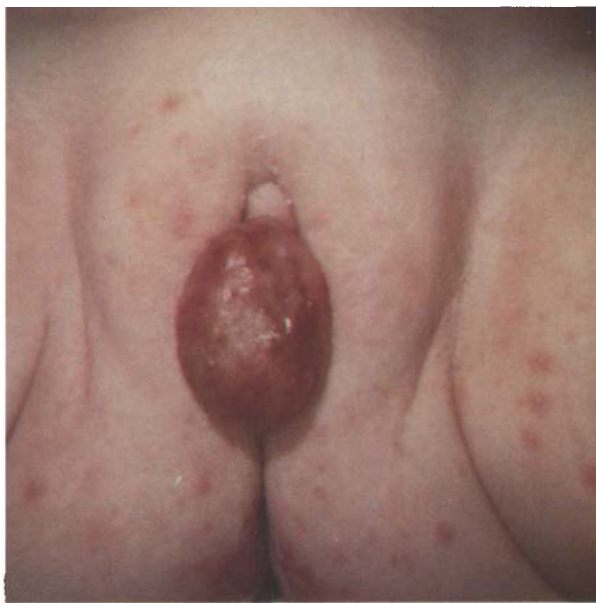Twenty-two of our 116 patients were noted to have neoplastic lesions. These included benign lesions that presented in a malignant fashion, such as an obstructing retroperitoneal mass, a dumbbell tumor extending into the spinal canal or brachial plexus with neurologic compromise, and lesions that recurred after initial excision with overgrowth into vital areas that prevent repeat excision and threaten life (Table IV).

Although all the histologically benign tumors represented neural elements, they cannot be considered completely benign because of the functional impairment of the central nervous system and their target organs. Not only was the target organ intrinsically impaired, but also attempts at resection of the lesion usually resulted in further neurologic loss.

The incidence of neoplasia was quite high for the young population. Most series report a 5% incidence. Of the 22 cases of neoplasia in 116 total cases, there were only 2 frankly malignant lesions, but other lesions involving compromise of the neuraxis led to death in 3 of our patients. The lesions were considered malignant because of their inaccessibility or their compromise to structures essential to the maintenance of life. At least 3 other patients from our series, now being treated at other institutions, have subsequently developed neoplastic lesions. One of our patients, being followed for a rhabdomyosarcoma of the urethra, presented to the orthopaedic clinic as a toe-in deformity which was subsequently diagnosed as a congenital pseudarthrosis of the tibia (Figure 12).



A



B

Figure 12. This child presented to hospital because of the development of a mass on the urethra. During hospitalization it was noted that she toed-in and orthopaedic consultation was requested. A biopsy of the urethral mass revealed a rhabdomyosarcoma. The cause of the toe-in deformity was a pseudarthrosis tibia with anterolateral bowing.

- A. Following lesional biopsy, the child was placed on chemotherapy with resulting alopecia. Note the anterolateral bow of the left tibia and “toe-in” of the left foot.
- B. The rhabdomyosarcomatous lesion projecting from the urethra. Most of the rhabdomyosarcomas associated with neurofibromatosis involve the genitourinary tract.

Table IV Neoplasms.

Patient	Unit number	Lesion	Sequelae
P.K. (A)	11321	Fibrosarcoma	Retroperitoneal mass compressing abdominal contents, leading to anorexia and death
D.P. (A)	11398	Neurofibrosarcoma	Sarcomatous changes in original neurofibromas of cervical area with subsequent involvement of spinal cord, clivus, and brain leading to death
J.O. (A)	13565	Accoustic Neuroma	Neurofibromatous involvement of accoustic nerve, olfactory groove, optic atrophy extension of spinal cord, leading to death
L.S. (A)	7537	Neurogenic sarcoma	Metastatic neurosarcoma to brain with headaches and clonic seizures, leading to death
P.C. (A)	18085	Retrobulbar glioma	Loss of right optic nerve
F.P. (A)	10158	Thalamic glioma	Ptosis of both eyes with subsequent brain involvement, requiring ventriculoperitoneal shunt, followed by abdominal laparotomy and death
M.B.B. (A)	24776	Mediastinal neuroblastoma	Exploratory thoracotomy, radiation therapy and posterior spinal fusion
W.C. (A)	15883	GR III astrocytoma T10-L1	Paraplegia
K.M. (A)	19104	Ganglioneuroblastoma picked up as mediastinal mass on roentgenogram	Anterior and posterior spinal fusion
C.W. (A)	8907	Retroperitoneal Neurofibroma	Palpable abdominal masses with abnormal function
R.S. (A)	10299	Retroperitoneal Neurofibroma	Dumbbell extension of retroperitoneal tumor into thorax and abdomen
E.B. (A)	9447	Sarcomas of paravertebral (neck) soft tissue	Excisional biopsy and irradiation
P.N. (A)	19242	Sarcomatous degeneration of mediastinal mass	Maintenance in external support after unsuccessful attempts at anterior and posterior spinal stabilization

Patient	Unit number	Lesion	Sequelae
S.B. (C)	210157	Bilateral optic glioma	Intracranial surgery
A.S. (C)	271200	Neurofibromata	Attempt to remove Neurofibromata of right posterior fossa, unsuccessful, mass extended too far proximally to be resected
L.B. (C)	245035	Bilateral optic nerve gliomas	Right frontal craniotomy incisional biopsy of right optic nerve
R.A. (C)	429951	Mid-lumbar (neurofibroma)	Excision of mass
T.S. (C)	342773	Plexiform neurofibroma	Excision of sixth intercostal nerve, sixth and seventh rib and 8 × 5 cm area of parietal pleura
W.C. (C)	202708	Intrathoracic ganglioneuroblastoma (mediastinum), plexiform neurofibroma (neck and scalp)	Thoracotomy with excision of ganglioblastoma, excision of plexiform neurofibroma of posterior scalp and neck
T.W. (C)	401999	Rhabdomyosarcoma	Chemotherapy, radiotherapy
B.J. (C)	420127	Plexiform neurofibroma	Radical neck dissection for plexiform neurofibroma
K.M.N. (C)	415368	Intraspinal neurofibroma anterior neck and mediastinum	<ol style="list-style-type: none"> 1. Left supra clavicular excision in neurofibroma 2. Decompressive laminectomy C2–C4 for intraspinal tumor 3. Reexploration of cervical spine, C1–C4 with removal of intraspinal and extra spinal neurofibroma with microscope and laser and occiput to C5, fusion using tibial tone graft

A = Alfred J. Dupont Institute.

C = Children's Hospital Medical Center, Cincinnati.

Discussion

Several questions have to be raised concerning the relationship of malignancies and neurofibromatosis. Is neurofibromatosis simply a neurocristopathy (54)? Is the malignant potential in neurofibromatosis restricted to tissues derived from the neural crest and to tissues which are near it? Or, as suggested by the association of leukemia, does the gene for neurofibromatosis simply increase the risk for a multiplicity of malignancies? Malignancy is a significant risk, and increases with age from about 7% in the preadolescent to greater than 20% in those over 21 years of age (101). Bader and Miller have shown that the overall risk of cancer in patients with neurofibromatosis is unknown at the present time. The risk of cancer in the normal population is 25% whereas the range of those patients being reported with neurofibromatosis who subsequently contract cancer is too wide to be meaningful (3–48%) (9). Furthermore, the data that have thus far been reported is biased and the tumors which will cause problems cannot be readily identified. The data thus far reported were not obtained under appropriate controls for age, sex, race, and location. The current 14% incidence of malignancies in neurofibromatosis possibly represents a stop frame in the life sequence, and does not represent a true incidence. The most common cancers associated with neurofibromatosis in children are optic glioma, brain tumor, rhabdomyosarcoma and non-lymphocytic leukemia.

Our patients (Table III) presented primarily with neoplasms of neurological origin. They were managed by the hematology-oncology and neurosurgical services. The approach has been primarily surgical; however, several have undergone follow-up irradiation. The Mayo Clinic has reported a high risk of cancer in those patients with neurofibromatosis who have undergone irradiation (9).

What product of a single mutant gene could account for the diverse manifestations of neurofibromatosis, from subtle scoliosis or a few café-au-lait spots to grotesque dysplasia or malignancies? About 1% of cancer in the total population occurs under 20 years. An overall frequency of 19% of hospitalized children with neurofibromatosis had malignancy of which optic nerve glioma accounted for 11%, and other brain tumors 3%. Of 4900 consecutive children reported with cancer under 15 years of age at 12 centers in the United States and Europe, neurofibromatosis, the most frequent single gene trait, was recorded in the charts of 38 patients (0.8%) who had 42 malignancies: 25 central nervous system tumors, 10 other neural malignancies, and 7 non-neural ones. Of the isolated cases of 84 consecutive patients with rhabdomyosarcoma at the Children's Hospital of Philadelphia and the National Cancer Institute, 5 had neurofibromatosis (0.03 would be expected by chance).

Astrocytoma is the most common intracranial tumor in children, and the most specific type is optic glioma. Optic gliomas associated with neurofibromatosis seem to have a distinct pattern of progressive proliferation and infiltration in the perineural and subarachnoid spaces. The acoustic neuroma associated with neurofibromatosis is much more common in adults. Tumors arising from within nerve trunks presented an average of 13 years earlier than those arising outside neural sheaths, supporting the idea that a different process leads to the two tumor types.

Maternal transmission of neurofibromatosis has been said to increase the severity of the disease. Children who inherited the disease from their mother, compared to

sporadic cases, or offspring of fathers with neurofibromatosis, seem to have the most severe complications including malignancy. The observations suggest a humoral factor produced by mothers with neurofibromatosis, an idea that deserves further evaluation.

The pheochromocytoma of adult neurofibromatosis is almost unheard of in the preadolescent. It has often been stated that the hypertension in a child with neurofibromatosis is related to renal artery disease, whereas, the hypertension in an adult is most often related to pheochromocytoma (42).

Further discussion of the incidence and management of neoplasms in neurofibromatosis in children exceeds the scope of this presentation.

Associated conditions

Organic manifestations of neurofibromatosis previously reported in children, such as sexual precocity and retarded sexual development, malignant hypertension secondary to renal artery stenosis with small vessel changes, and mental retardation, were not statistically analyzed in this series. Most series show patients with neurofibromatosis to have a definite trend toward learning disability with some 50% having a combination of being slow in comprehension with delayed speech and motor development when compared to their peers. Samuelsson recently concluded a genetic and clinical study of 96 cases of neurofibromatosis in Göteborg, Sweden (110). These patients were all comprehensively reviewed by the Health, Education and National Registration records. She noted significant reduction in the number of older patients which she felt indicated an excess mortality in connection with neurofibromatosis. Mild mental retardation was detected in 45% of the patients, and mental illness in 33%, of whom two thirds had severe forms. No significant correlation was found between physical activity or neurofibromatosis and either mental illness or mental retardation. There were not enough of our patients with intelligence tests available to arrive at a definite conclusion. Our group did reveal a very definite trend toward mental retardation. Macrocrania and short stature have also been noted in series on neurofibromatosis in children (135) but were not investigated in this study.

Summary

The clinical diagnosis of neurofibromatosis in childhood will usually be based on the presence of numerous café-au-lait spots. Early diagnosis allows for continuing follow-up and appropriate counselling. Symptomatic therapy can be provided if necessary. The disorder has a tendency via its mesodermal route to affect almost every system in the body; however, few laymen have even heard of the disorder and, except for the "Elephant Man" notoriety, are totally unaware of it, whereas muscular dystrophy, cystic fibrosis, and Down syndrome although occurring less frequently are well known to the general public (58). The management of neurofibromatosis in children covers an extremely wide spectrum: at times the management appears to be simple, involving little more than clinical evaluation and simple investigations. However, in view of the protean manifestations of the condition, a complete history including family history is obligatory, and investigation must include radiographic studies of the abdomen, chest, spine, and skull, the latter to include special views of the orbits and optic foramina (26).

My investigation of this disorder has been extremely frustrating because of the progressive character of the disease. Nothing seems to alter the natural course of the disease. I cannot say that my investigative efforts have revealed any breakthroughs in treatment. An aggressive surgical approach to the myriad of lesions associated with this disease, especially neuromata or segmental problems, is probably advisable. The early treatment of tibial pseudarthrosis by polypropylene orthotic and pulsating electromagnetic fields shows encouraging results over the short course, although I am not so sure as to whether or not the patients would do as well with the custom fit orthotic with or without the electronics. Early stabilization of spinal deformity has proven to be more than moderately successful and is strongly recommended following appropriate intraspinal evaluation. The management of tumors of the brain and spinal cord, as well as those associated with limb hypertrophy and congenital tibial pseudarthrosis, is undergoing innovations at this time which may result in a better cure rate. Procedures include the use of CT to evaluate tumors [Coleman et al. have attempted to differentiate neurofibromas from neurofibrosarcoma by contrast enhancement methods] (27), the use of CO₂ lasers to remove previously inoperable CNS tumors, microvascular bone transplantation and pulsating electromagnetic field to treat pseudarthrotic bones.

The National Neurofibromatosis Foundation appears well on its way to obtaining recognition for this disorder via the establishment of local as well as national chapters

dedicated to the education of the medical practitioner and the public at large. Genetic counselling is a part of this educational process. The hereditary nature of the disease offers the prospect for prevention through family counselling, a prospect that can only be realized by recognition of its manifold expression in childhood when parenthood or further affected siblings in a family may be avoided (58). In advising parents, the epidemiologic data provided by Crowe et al. (32) are preferable to the data obtained from this study which is biased towards the more serious manifestations, as was the study of Cole and Meyers (26). Crowe et al. in 1956 showed that at least 25 % of affected patients have café-au-lait spots as the only manifestation of the disease throughout their lifetime.

Conclusion

I have presented 116 patients under 12 years of age who were conclusively diagnosed as having neurofibromatosis and followed for an average of 5 years over the past 9 years. The following observations were made.

1. The most common presenting complaint was that of spinal deformity.
2. The spinal deformities were divided into four categories:
 - A. Scoliosis associated with neurofibromatosis in which there were dysplastic vertebral bodies and progressive deformity.
 - B. Scoliosis associated with neurofibromatosis that presented as an idiopathic scoliosis with the same prognosis as other idiopathic scoliosis.
 - C. Kyphoscoliosis with a tendency to rapid progression, severe dysplasia, occasional loss of structure of the vertebral bodies, and a tendency toward pseudarthrosis after spinal fusion.
 - D. Cervical spinal abnormality most often associated with a neck mass.
3. The presence of a café-au-lait spot was the most consistent finding (89%) and the number and size tended to increase with age.
4. The association of congenital tibial pseudarthrosis and neurofibromatosis was confirmed. The lesions were divided into non-dysplastic and dysplastic types. The natural history of the non-dysplastic type offers a better prognosis. Current recommendations for management were extended.
5. The incidence of neoplasia far exceeded that of the average population and some lesions that were not considered frankly malignant resulted in catastrophic consequences because of their anatomic locations.

Acknowledgment

Acknowledgment is given to Ms. Marlena Tyre and Nancy Bagamery, M.D. for their kind assistance in the preparation of this manuscript. My thanks to Drs. Josef Warkany and Peter Dignan for their kind criticism. Appreciation is extended to G. D. MacEwen, M.D. and the staff of the A. I. DuPont Institute. Kind appreciation is also extended to Mrs. Dolores Goldfinger of the Ohio Chapter of the National Neurofibromatosis Association and Ms. Helen Johnson from the Dan Tehan Memorial Golf Tournament 1984 whose proceeds made this effort possible.

References

- (1) **Adkins J C, Ravich M M.** The Operative Management of von Recklinghausen's Neurofibromatosis in Children, with Special Reference to Lesions of the Head and Neck. *Surgery* 82(3): 342-48, 1977.
- (2) **Adrian C.** Über Neurofibromatose und Ihre Komplikationen. *Beitr Klin Chir*, 31: 1-98, 1901.
- (3) **Aegerter E E.** The Possible Relationship of Neurofibromatosis, Congenital Pseudarthrosis and Fibrous Dysplasia. *J Bone Joint Surg* 32A: 618-626, 1950.
- (4) **Ali M S, Hooper G.** Congenital Pseudarthrosis of the Ulna Due to Neurofibromatosis. *J Bone Joint Surg* 64B(5): 600-602, 1982.
- (5) **Aldred A J.** Congenital Pseudarthrosis of the Clavicle. *J Bone Joint Surg*, 45B: 312-319, 1963.
- (6) **Andersen K S.** Congenital Pseudarthrosis of the Leg. (Late Results.) *J Bone Joint Surg* 58A(5): July 657-62, 1976.
- (7) **Andersen K S.** Congenital Pseudarthrosis of the Tibia and Neurofibromatosis. *Acta Orthop Scand*, 47(1): 108-111, 1976.
- (8) **Angtuaco E J, Binet E F, Flanigan S.** Value of Computed Tomographic Myelography in Neurofibromatosis. *Neurosurgery* 1983 Dec. 13(6): 666-71.
- (9) **Bader J L, Miller R W.** Neurofibromatosis and Childhood Leukemia. *J Pediatr*, 92(6): 925-29, 1978.
- (10) **Barber C G.** Congenital Bowing and Pseudarthrosis of the Lower Leg. Manifestations of von Recklinghausen's Neurofibromatosis. *Surg Gynecol Obstet*, 69: 618-26, 1939.
- (11) **Bassett C A L, Caulo N P, Kort J S.** Congenital "Pseudarthrose" of the Tibia: Treatment with Pulsating Electromagnetic Fields. *Clin Orthop* 154: 136-49, 1981.
- (12) **Berk L, Mankin H J.** Spontaneous Pseudoarthrosis of the Tibia Occurring in a Patient with Neurofibromatosis. Report of a Case in a Man Forty-one Years Old. *J Bone Joint Surg*, 46A: 619-624, 1964.
- (13) **Biot B, Fauchet R, Stagnara P.** Les Lésions Vertébrales de la Neurofibromatose. *Rev Chir Orthop*, 60(8): 607-621, 1974.
- (14) **Boyd H B, Sage F P.** Congenital Pseudarthrosis of the Tibia. *J Bone Joint Surg*, 40A: 1245-1270, 1958.
- (15) **Bradford D S.** Neurofibromatosis in Children. *American Academy of Orthopedic Surgeons, Instructional Course Lectures*, Las Vegas, Nevada, 1976.
- (16) **Brasfield R D, Das Gupta T K.** von Recklinghausen's Disease: A Clinicopathological Study. *Ann Surg*, 175(1): 86-104, 1972.

- (17) **Breig A.** Biomechanics of the Central Nervous System: Some Basic Normal and Pathologic Phenomena Concerning Spine, Disk, and Cord. Almqvist & Wiksell Printers & Publishers, Stockholm, 1960.
- (18) **Brighton C T, Friedenberg Z B, Zemsky L M, Pollis P R.** Direct-Current Stimulation of Non-union and Congenital Pseudoarthrosis. Exploration of its Clinical Application. *J Bone Joint Surg*, 57A(3): 368–77, 1975.
- (19) **Briner J, Yunis E.** Ultrastructure of Congenital Pseudoarthrosis of the Tibia. *Arch Pathol*, 95(2): 97–99, 1973.
- (20) **Brooks B, Lehman E P.** The Bone Changes in Recklinghausen's Neurofibromatosis. *Surg Gynecol Obstet*, 38: 587–595, 1924.
- (21) **Chaglassian J H, Riseborough E J, Hall J E.** Neurofibromatous Scoliosis. Natural History and Results of Treatment in Thirty-seven Cases. *J Bone Joint Surg*, 58A: 695–702, 1976.
- (22) **Chao D H.** Congenital Neurocutaneous Syndromes in Childhood. Chapter I, Neurofibromatosis. *J Pediatr*, 55: 189–99, 1959.
- (23) **Charnley J.** Congenital Pseudoarthrosis of the Tibia Treated by Intramedullary Nail. *J Bone Joint Surg*, 38A(2): 283–290, 1956.
- (24) **Cobb J R.** Outline for the Study of Scoliosis. In: Instructional Course Lectures, American Academy of Orthopedic Surgeons. J. W. Edwards, Ann Arbor, Michigan, 5: 261–275, 1948.
- (25) **Cobb N.** Neurofibromatosis and Pseudoarthrosis of the Ulna: A Case Report. *J Bone Joint Surg*, 50B: 146–149, 1968.
- (26) **Cole W G, Myers N A.** Neurofibromatosis in Childhood. *Aust NZ J Surg* 48(4): 360–365, 1978.
- (27) **Coleman B G, Arger P H, Dalinka M K, Obringer A C, Raney B R, Meadows A T.** CT of Sarcomatous Degeneration in Neurofibromatosis. *AJR* 140: 383–387, 1983.
- (28) **Cowell H R, Hall J N, MacEwen G D.** Genetic Aspects of Idiopathic Scoliosis. A Nicholas Andry Award Essay, 1970. *Clin Orthop*, 86: 121–131, 1972.
- (29) **Crawford A H.** Neurofibromatosis in Children. *Am Fam Physician*, 17: 163–170, 1978.
- (30) **Crawford A H.** Neurofibromatosis in the Pediatric Patient. *Orthop Clin North Am*, 9(1): 11–23, 1978.
- (31) **Crawford A H.** Neurofibromatosis in Childhood. *Instr Course Lect* 30:56–74, 1981.
- (32) **Crowe F W, Schull W J, Neil J W.** A Clinical, Pathological and Genetic Study of Multiple Neurofibromatosis. Charles C. Thomas, Springfield, IL, 1956.
- (33) **Curtis B H, Fisher R L, Butterfield W L, Saunders F P.** Neurofibromatosis with Paraplegia: Report of Eight Cases. *J Bone Joint Surg*, 51A: 843–861, 1969.
- (34) **Ducroquet R.** A Propos des Pseudoarthroses et inflexions Congénitales du Tibia. *Mém Acad de Chir*, 63: 863–868, 1937.
- (35) **Dunn A W.** Case of Overgrowth of Leg and Anterolateral Bowing of Tibia in Neurofibromatosis. *Amer J Orthop*, 7: 120–123, 1965.
- (36) **Edvardson P.** Resection Osteosynthesis and Boyd Amputation for Congenital Pseudoarthrosis of the Tibia. *J Bone Joint Surg* 55B(1): 179–182, 1973.
- (37) **Eyre-Brook A L, Baily R A, Price C H.** Infantile Pseudoarthrosis of the Tibia. Three cases treated successfully by delayed autogenous by-pass graft, with some comments on the causative lesion. *J Bone Joint Surg*, 51B: 604–13, 1969.

- (38) **Fairbank H A T.** Neurofibromatosis: Atlas of General Infections of the Skeleton. *J Bone Joint Surg*, 32B(2): 266–270, 1950.
- (39) **Fialkow P J, Sagebiel R W, Gartler S M, Rimoin D L.** Multiple Cell Origin of Hereditary Neurofibromas. *N Engl J Med*, 284: 298–300, 1971.
- (40) **Fienman N L, Yakovac W C.** Neurofibromatosis in Childhood. *J Pediatr*, 76(3): 339–346, 1970.
- (41) **Fienman N L.** Compr Ther. Pediatric Neurofibromatosis: Review. 7(11): 66–72, 1981.
- (42) **Fleming M P, Miller W E.** Renovascular Hypertension due to Neurofibromatosis. Report of a case. *Am J Roentgenol Radium Ther Nucl Med*, 113: 452–454, 1971.
- (43) **Friedman M.** Neurofibromatosis of Bone. *AJR*, 51(5): 623–630, 1944.
- (44) **Frenk E.** Ultrastructural Study of the pigmented spots in Albright's syndrome. *Dermatologica*, 143: 12–20, 1971.
- (45) **Gould E P.** The Bone Changes Occurring in von Recklinghausen's Disease. *Quarterly J Med*, XI: 221–227, 1918.
- (46) **Green W T, Rudo N.** Pseudarthrosis and Neurofibromatosis. *Arch Surg*, 46: 639–651, 1943.
- (47) **Gregg P J, Price B A, Ellis H A, Stevens J.** Pseudarthrosis of the Radius Associated with Neurofibromatosis. *Clinical Orthopedics*, 171: 175–179, 1982.
- (48) **Hagelstam L.** On the Deformities of the Spine in Multiple Neurofibromatosis (von Recklinghausen). *Acta Chir Scand*, 93: 169–193, 1946.
- (49) **Hallock H.** The Use of Multiple Small Bone Transplants in the Treatment of Pseudarthrosis of the Tibia of Congenital Origin or Following Osteotomy for the Correction of Congenital Deformity. *J Bone Joint Surg*, 20: 648–60, 1938.
- (50) **Hardinge K.** Congenital Anterior Bowing of the Tibia. The Significance of the Different Types in Relation to Pseudarthrosis. *Ann R Coll Surg Engl*, 51: 17–30, 1972.
- (51) **Harkin J C, Reed R J.** Tumors of the Peripheral Nervous System. Second Series, Fascicle 3, Washington, D.C., Armed Forces Institute of Pathology, 1969.
- (52) **Heard G E, Holt J F, Naylor B.** Cervical Vertebral Deformity in von Recklinghausen's Disease of the Nervous System. A Review with Necropsy Finding. *J Bone Joint Surg* 44B: 880–5, 1962.
- (53) **Henderson M S.** Congenital Pseudarthrosis of the Tibia. *J Bone Joint Surg*, 10: 483–91, 1928.
- (54) **Hecht F, McCaw B K, Lanzkowsky P, Shanske A, Shende A, Karayalcin G.** Neurofibromatosis and Malignancy. Letter to the Editor. *J Pediatr*, 94(6): 1010, 1979.
- (55) **Henschen F.** Zur Histologie und Pathogenese der Kleinhirnbrückenwinkeltumoren *Arch Psych Nerv* 56: 20–122, 1915.
- (56) **Hensley C D.** The Rapid Development of a "Subperiosteal Bone Cyst" in Multiple Neurofibromatosis. *J Bone Joint Surg*, 35A: 197–203, 1953.
- (57) **Holt J F, Wright E M.** The Radiologic Features of Neurofibromatosis. *Radiology*, 51: 647–64, 1948.
- (58) **Holt J F.** 1977 Edward B D Neuhauser lecture: neurofibromatosis in children. *AJR*, 130: 615–639, 1978.
- (59) **Hosoi K.** Multiple Neurofibromatosis (von Recklinghausen's Disease) with Special Reference to Malignant Transformation. *Arch Surg*, 22: 258–281, 1931.
- (60) **Hunt J C, Pugh D C.** Skeletal Lesions in Neurofibromatosis. *Radiology*, 76(1): 1–20, 1961.

- (61) **Isu T, Miyasaka K, Abe H et al.** Atlantoaxial Dislocation Associated with Neurofibromatosis. Report of three cases. *J Neurosurg* 58: 451–453, 1983.
- (62) **Jacobsen S T, Crawford A H, Millar E A, Steel H H.** The Syme Amputation in Patients with Congenital Pseudarthrosis of the Tibia. *J Bone Joint Surg*, 65A(4): 533–37, 1983.
- (63) **Johnson B L, Charneco D R.** Café-au-lait spot in Neurofibromatosis and in Normal Individuals. *Arch Dermatol* 102: 442–446, 1970.
- (64) **Kite J H.** Congenital Pseudarthrosis of the Tibia and Fibula. Report of Fifteen Cases. *Southern Med J*, 34(10): 1021–32, 1941.
- (65) **Klatte E C, Franken E A, Smith J A.** The Radiographic Spectrum in Neurofibromatosis. *Semin Roentgenol*, 11: 17–33, 1976.
- (66) **Klose J.** Recklinghausensche neurofibromatose mit schwerer deformierung der Halswirbelsäule. *Klin Wochenschr*, 5: 817, 1926.
- (67) **Kullmann L, Wouters H W.** Neurofibromatosis, Gigantism, and Subperiosteal Haematoma: Report of Two Children with Extensive Subperiosteal Bone Formation. *J Bone Joint Surg*, 54B: 130–138, 1972.
- (68) **Langenskiöld A.** Pseudarthrosis of the Fibula and Progressive Valgus Deformity of the Ankle in Children: Treatment by Fusion of the Distal Tibial and Fibular metaphyses: Review of Three Cases. *J Bone Joint Surg*, 49A: 463–470, 1967.
- (69) **Lavine L S, Lustrin I, Shamos M H, Rinaldi R A, Liboff A R.** Electric Enhancement of Bone Healing. *Science*, 175: 118–21, 1972.
- (70) **Laws J W, Pallis C.** Spinal Deformities in Neurofibromatosis. *J Bone Joint Surg*, 45B: 674–682, 1963.
- (71) **Leung P C.** Congenital Pseudarthrosis of the Tibia. Three Cases Treated by Free Vascularized Iliac Crest Graft. *Clin Orthop*, 175: 45–50, 1983.
- (72) **Lloyd-Roberts G C, Shaw N E.** The Prevention of Pseudarthrosis in Congenital Kyphosis of the Tibia. *J Bone Joint Surg* 51B: 100–105, 1969.
- (73) **Locht R C, Huebert H T, McFarland D F.** Subperiosteal Hemorrhage and Cyst Formation in Neurofibromatosis. *Clin Orthop*, 155: 141–146, 1981.
- (74) **Lonstein J E, Winter R B, Moe J H, Bradford D S, Chou S N, Pinto W C.** Neurologic Deficits Secondary to Spinal Deformity. *Spine*, 5(4): 331–355, 1980.
- (75) **Loop J W, Akeson W H, Clawson D K.** Acquired Thoracic Abnormalities in Neurofibromatosis. *AJR*, 93: 416–424, 1965.
- (76) **Manske P R.** Forearm Pseudarthrosis – Neurofibromatosis. *Clin Orthop*, 139: 125–127, 1979.
- (77) **Mandell G A.** The Pedicle in Neurofibromatosis. *AJR*, 130: 675–678, 1978.
- (78) **Masihuz-Zaman.** Pseudarthrosis of the Radius Associated with Neurofibromatosis. *J Bone Joint Surg*, 59A: 977–978, 1977.
- (79) **Masserman R L, Peterson H A, Bianco A J Jr.** Congenital Pseudarthrosis of the Tibia: A Review of the Literature and Fifty-Two Cases from the Mayo Clinic. *Clin Orthop*, 99: 140–145, 1974.
- (80) **McCarroll H R.** Clinical Manifestations of Congenital Neurofibromatosis. *J Bone Joint Surg*, 32A: 601–617, 1950.
- (81) **McFarland B.** Pseudarthrosis of the Tibia in Childhood. *J Bone Joint Surg*, 33B: 36–46, 1951.
- (82) **McKeen E A, Bodurtha J, Meadows A T, Douglass E C, Mulvihill J J.** Rhabdomyosarcoma Complicating Multiple Neurofibromatosis. *J Pediatr*, 93: 992–993, 1978.

- (83) **McKellar C C.** Congenital Pseudarthrosis of the Tibia: Treatment by Tibial Lengthening and Corrective Osteotomy Seven Years After Successful Bone Graft: A Case Report. *J Bone Joint Surg*, 55A: 193–196, 1973.
- (84) **Merten D F, Gooding C A, Newton T H, Malamud N.** Meningiomas of Childhood and Adolescence. *J Pediatr* 84(5): 696–700, 1974.
- (85) **Miller A.** Neurofibromatosis with Reference to Skeletal Changes, Compression Myelitis and Malignant Degeneration. *Arch Surg* 32: 109–122, 1936.
- (86) **Moore J R.** Delayed Autogenous Bone Graft in Treatment of Congenital Pseudarthrosis. *J Bone Joint Surg*, 31A: 23–39, 1949.
- (87) **Moore J R.** Congenital Pseudarthrosis of the Tibia. In: *Instructional Course Lectures, American Academy of Orthopedic Surgeons. Vol 14*, J. W. Edwards Publishers, Ann Arbor, Michigan, PP. 222–237, 1957.
- (88) **Murray H H, Lovell W W.** Congenital Pseudarthrosis of the Tibia. A Long-term Follow-up Study. *Clin Orthop*, 166: 14–20, 1982.
- (89) **Morrissy R T, Riseborough E J, Hall J E.** Congenital Pseudarthrosis of the Tibia. *J Bone Joint Surg*, 63B: 367–375, 1981.
- (90) **National Neurofibromatosis Foundation, Inc.,** Newsletter: Neurofibromatosis: An Historical Perspective. Vol. 6, No. 1, p. 8, 1983.
- (91) **Nes C P van.** Congenital Pseudarthrosis of the Leg. *J Bone Joint Surg*, 48A: 1467–83, 1966.
- (92) **Norgaard F.** Osseous Changes in Recklinghausen Neurofibromatosis. *Acta Radiol*, 18: 460–470, 1937.
- (93) **Ormsby O S, Montgomery H.** *Diseases of the Skin.* 8th Edition, Lea & Febiger, Philadelphia, 1954.
- (94) **Pitt M J, Mosher J F, Edeiken J.** Abnormal Periosteum and Bone in Neurofibromatosis. *Radiology* 103: 143–146, 1972.
- (95) **Pohl R.** Meningokele im Brustraum unter dem Bilde eines Intrathorakalen Rundschattens. *Röntgenpraxis*, 5: 747–749, 1933.
- (96) **Pollnitz R.** Neurofibromatosis in Childhood: A Review of Twenty-five Cases. *Med J Austral*, 2: 49–52, 1976.
- (97) **Preiser S A, Davenport C B.** [Multiple Neurofibromatosis]. *Am J Med Sci*, 156: 507, 1918.
- (98) **Rathgeb J M, Ramsey P L, Cowell H R.** Congenital Kyphoscoliosis of the Tibia. *Clin Orthop*, 103: 178–190, 1974.
- (99) **Recklinghausen F V.** Über die Multiplen Fibrome der Haut und ihre Beziehung zu den Multiplen Neuomen, August Hirschwald, Berlin, 1882.
- (100) **Rezaian S M.** The Incidence of Scoliosis due to Neurofibromatosis. *Acta Orthop Scand*, 47: 534–539, 1976.
- (101) **Riccardi V M, Kleiner B.** Neurofibromatosis: A Neoplastic Birth Defect with Two Age Peaks of Severe Problems. *Birth Defects*, 13(3C): 131–138, 1977.
- (102) **Riccardi V M.** Neurofibromatosis. *Advances in Neurology.* Edited by V. M. Riccardi and J. J. Mulvihill. Vol. 29, Raven Press, New York, 1981. pp. 1–9.
- (103) **Riccardi V M.** Von Recklinghausen Neurofibromatosis. *New Engl J Med* 305: 1617–1627, 1981.
- (104) **Riccardi V M.** Neurofibromatosis: Clinical Heterogeneity. *Current Problems in Cancer.* 1982 (2). pp. 1–34.

- (105) **Robin G C.** Scoliosis and Neurological Disease. *Israeli J Med Sci*, 9: 578–586, 1973.
- (106) **Rockower S, McKay D, Nason S.** Dislocation of the Spine in Neurofibromatosis – A Report of Two Cases. *J Bone Joint Surg* 64A(8): 1240–1242, 1982.
- (107) **Rubenstein A E.** Symposium on Neurofibromatosis for the Health Care Professional. National Neurofibromatosis Foundation, Boston, MA, 1983.
- (108) **Sammons B P, Thomas D F.** Extensive Lumbar Meningocele Associated with Neurofibromatosis. *AJR*, 81(6): 1021–1025, 1959.
- (109) **Samoto T, Watanabe Y, Suda A et al.** Atlantoaxial Dislocation with Neurofibromatosis – A Case Report. *Orthop Traum Surg* 24: 289–293, 1981 (Jpn).
- (110) **Samuelsson B.** Neurofibromatosis (von Recklinghausen's Disease): A Clinical, Psychiatric, and Genetic Study. University Press, Göteborg, Sweden, 1981.
- (111) **Sane S, Yunis E, Greer R.** Subperiosteal or Cortical Cyst and Intramedullary Neurofibromatosis: Uncommon Manifestations of Neurofibromatosis. A Case Report. *J Bone Joint Surg*, 53A: 1194–1200, 1971.
- (112) **Saville et al.** In: von Recklinghausen. Hirschwald, Heard & Holt Publishers, 1882.
- (113) **Savini R, Parisini P, Cervellati S, Gualdrini G.** Surgical Treatment of Vertebral Deformities in Neurofibromatosis. *Ital J Orthop Traumatol* 9(1): 13–24, 1983.
- (114) **Schenkein I, Bueker E D, Helson L, Axelrod F, Dancis J.** Increased Nerve-Growth-Stimulating activity in Disseminated Neurofibromatosis. *New Engl J Med*, 290: 613–614, 1974.
- (115) **Scott J C.** Scoliosis and Neurofibromatosis. *J Bone Joint Surg*, 47B: 240–246, 1965.
- (116) **Saville P D, Nassim J R, Stevenson R H, Mulligan L, Carey M.** Osteomalacia in von Recklinghausen's Neurofibromatosis. Metabolic Study of a Case. *Br Med J*, 1: 1311–1313, 1955.
- (117) **Sharpe J C, Young R H.** Recklinghausen's Neurofibromatosis: Clinical Manifestations in Thirty-one Cases. *Arch Int Med*, 59(1): 299–328, 1937.
- (118) **Sheklakov N D.** A Case of Neurofibromatosis with 9,242 Tumors. *Vestn Venerol Dermatol*, 3: 51–52, 1950.
- (119) **Siggers D C.** Nerve Growth Factor and Some Inherited Neurological Conditions. *Proceedings of the Royal Society of Medicine*, 69: 183–184, 1976.
- (120) **Soffield H A, Millar E A.** Fragmentation, Realignment and Intramedullary Rod Fixation of Deformities of the Long Bones in Children: A Ten Year Appraisal. *J Bone Joint Surg* 41A(8): 1371–91, 1959.
- (121) **Stay E J, Vawter G.** The Relationship Between Nephroblastoma and Neurofibromatosis (von Recklinghausen's disease). *Cancer*, 39: 2550–2555, 1977.
- (122) **Steg N L, Wong A K C, Vogel M A, Wang C C, Casey P A.** The Potential of Computerized Dermatoglyphic Analysis as Demonstrated Through Studies of Patients with Meningomyelocele and Neurofibromatosis. In: Numerical Taxonomy of Birth Defects and Polygenic Disorders. D. Bergsma & R. B. Lawry, Editors. New York: pp. 158–159, 1977.
- (123) **Stout A P.** Tumors of the Peripheral Nervous System. In: Atlas of Tumor Pathology. Section II, Fascicle 6. Armed Forces Institute of Pathology, Washington, D.C., 1949.
- (124) **Suzuki M, Tamura E, Kamoshita S et al.** Clinical Observation of Phacomatosis in Infancy and Childhood. 1. von Recklinghausen's Disease. *Paediat Univ Tokyo*, 9: 23–6, 1963.
- (125) **Takahasi M.** Studies on café-au-lait spots in Neurofibromatosis and Pigmented Macules of Nevus Spilus. *Tohoku J Exp Med*, 118: 255–273, 1976.

- (126) **Tilesius von Tilenau W G.** *Historia Pathologica Singularis Cutis Turpitudinus.* Leipzig, S. L. Crusius, 1793.
- (127) **Treves F.** Congenital Deformity. *Br Med J*, 2: 1140, 1884.
- (128) **Treves F.** Congenital Deformity. *Br Med J*, 1: 595, 1885.
- (129) **Treves F.** A Case of Congenital Deformity. *Trans Pathol Soc London*, 36: 494–498, 1885.
- (130) **Treves F.** *The Elephant Man and Other Reminiscences.* New York, Holt, 1924.
- (131) **Veliskakis K P, Wilson P D Jr, Levine D B.** Neurofibromatosis and Scoliosis. Significance of the Short Angular Spine Curve. *J Bone Joint Surg*, 52A: 833, 1970.
- (132) **Virchow R.** Ueber die reform der pathologischen und therapeutischen Anschauungen durch die mikroskopischen Untersuchungen. *Arch Pathol Anat Phys Klin Med*, 1: 207–255, 1847.
- (133) **Weber F P.** Cutaneous Pigmentation as an Incomplete Form of Recklinghausen's Disease, with Remarks on the Classification of Incomplete and Anomalous Forms of Recklinghausen's Disease. *Br J Derm* 21:49–53, 1909.
- (134) **Wehbé M A, Mickelson M R.** Malignant Schwannoma in Neurofibromatous Elephantiasis on the Upper Extremity. *Clin Orthop*, 167: 164–167, 1982.
- (135) **Weichert K A, Dine M S, Benton C, Silverman F N.** Macrocranium and Neurofibromatosis. *Radiology*, 107: 163–166, 1973.
- (136) **Weiland A J, Daniel R K.** Congenital Pseudarthrosis of the Tibia: Treatment with Vascularized Autogenous Fibular Grafts. A Preliminary Report. *Johns Hopkins Med J*, 147: 89–95, 1980.
- (137) **Weiss R S.** (A) von Recklinghausen's Disease in the Negro; Curvature of the spine in von Recklinghausen's disease. *Arch Dermat & Syph* 3: 144–51, 1921.
- (138) **Wellwood J M, Bulmer J H, Graff D J.** Congenital Defects of the Tibia in Siblings with Neurofibromatosis. *J Bone Joint Surg* 53B: 314–319, 1971.
- (139) **Whitehouse D.** Diagnostic Value of the Café-au-lait Spot in Children. *Arch Dis Child*, 41: 316–319, 1966.
- (140) **Winter R B, Moe J H, Bradford D S, Lonstein J E, Pedras C V, Weber A H.** Spine Deformity in Neurofibromatosis. A review of one hundred and two patients. *J Bone Joint Surg*, 61A: 677–694, 1979.
- (141) **Yaghmai I, Tafazoli M.** Massive Subperiosteal Hemorrhage in Neurofibromatosis. *Radiology*, 122: 439–441, 1977.
- (142) **Young D F, Eldridge R, Gardner W J.** Bilateral Acoustic Neuroma in a Large Kindred. *JAMA*, 214: 347–53, 1970.
- (143) **Yong-Hing K, Kalamchi A, MacEwen G D.** Cervical Spine Abnormalities in Neurofibromatosis. *J Bone Joint Surg*, 61A: 695–699, 1979.