

^{99m}Tc-DPD uptake in juvenile arthritis

Scintimetry and autoradiography of the knee in dogs

Unilateral arthritis of the knee was induced in mongrel puppies by intra-articular injections of 1% Carrageenan. Bone metabolism was studied by a scintimetric technique on static ^{99m}Tc-diphosphonate bone scans every 2nd week during the induction of arthritis for 3 months and monthly in a postarthritic phase of another 3 months. Changes in uptake of radio-nuclide were present after 2 weeks. The induction phase was characterized by a decreased uptake in the calcification layer of the juxta-articular growth plates and a moderately increased epiphyseal uptake. The postarthritic phase was characterized by normalization of growth plate uptake and a marked increase in epiphyseal uptake.

Using contact autoradiography, the epiphyseal uptake was seen mainly in a narrow subchondral and subsynovial bone layer, around bone cysts and osteophytes, whereas central epiphyseal bone was osteopenic with decreased uptake of tracer.

The study suggests that the early scintigraphic appearance of juvenile non-suppurative arthritis may be an overall decrease in uptake of ^{99m}Tc-diphosphonate due to a depression of growth plate metabolism.

Ebbe Stender Hansen^{1,2}
Ida Elisabeth Holm²
Cody Büniger^{1,2}
Ivan Noer³
Steen Bach Christensen⁴
Vibeke Knudsen²

¹The Orthopedic Hospital, Århus; ²Institute of Experimental Clinical Research, University of Århus; ³Department of Clinical Physiology, County Hospital of Randers; ⁴Department of Orthopedics, Rigshospitalet, Copenhagen, Denmark

Correspondence: Dr. Ebbe Stender Hansen, The Orthopedic Hospital, DK-8200 Aarhus N, Denmark

Radionuclide scintimetry of the juvenile hip in transient synovitis suggests a threatened blood supply of the femoral head epiphysis following joint tamponade (Wingstrand et al. 1985). However, the significance of changed uptake of bone seeking isotopes in various arthritic conditions in children remains uncertain. Uptake of ^{99m}Tc-diphosphonates in bone is dependent on the regional blood flow, the product of permeability and surface area in the vascular bed, the amount of interstitial fluid and the metabolic state of the bone (Sagar et al. 1979, Charkes 1980, Hughes 1980). Using a scintimetric technique, a quantitative measure of metabolic changes within circumscribed regions of the juxtaarticular bone can be achieved (Bauer et al. 1980, Wingstrand et al. 1985). Contact autoradiography in animal studies permits precise localization of the ^{99m}Tc-diphosphonate uptake (Christensen and Krogsgård 1981). Repeated application of these methods provides a description of the

combined vascular and metabolic changes in bony structures affected by the arthritic process with respect to both time and anatomical location. Thus we determined the time lapse before changes in uptake of ^{99m}Tc-diphosphonate appeared in nonsuppurative arthritis, followed the uptake pattern throughout the arthritic and postarthritic phases, and located the uptake of tracer by autoradiography.

Material and methods

Fifteen mongrel puppies 8 weeks old and weighing 7.7 (5.0-12) kg, were studied.

In four dogs a unilateral gonarthrosis was induced by weekly injections of 1 ml increasing to 3 ml Carrageenan 1% solution into the right knee joint (Büniger et al. 1984c). The arthritic phase was maintained for 12 weeks, during which scintigraphy and scintimetry were performed every 14 days. At the end of this phase 2 dogs were killed and contact autoradiography of arthritic and control knees was car-

ried out. The remaining 2 dogs were followed with monthly bone scans in a postarthritic phase of another 3 months, after which contact autoradiography was carried out.

Evaluation of the scintimetric method and the biological variation of ^{99m}Tc -diphosphonate uptake in normal immature knees was performed in 11 control dogs.

Bone scanning

Joint scintigraphy was performed 2 hours after intravenous injection of 15–20 mCi ^{99m}Tc -DPD (99m labeled technetium 2,3-dicarboxypropane-1,1 diphosphonate) by means of a large field gamma camera (General Electric Maxi camera 61) equipped with a low energy, ultra high resolution converging collimator. Scanning was carried out under general anesthesia (Immobilon[®]) with the dogs in a supine position. Each examination consisted of an anteroposterior study of the hind legs with the knees in extension and sagittal scanning of each knee in semiflexed position. The camera was placed parallel to the floor and in contact with the patellae for the anteroposterior scans and with the medial femoral condyle for the sagittal scans. After the examination, the dogs were awakened with Revivon[®] i.v.

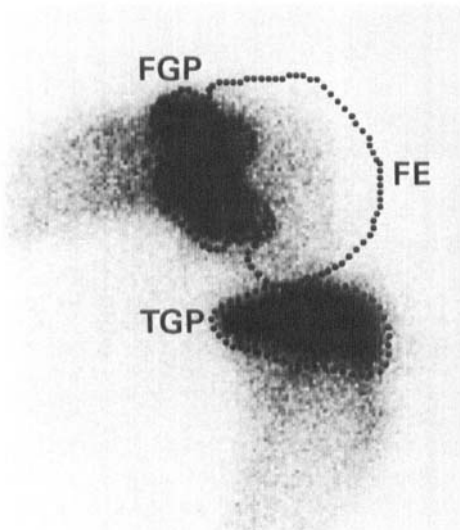


Figure 1. Normal knee. Sagittal ^{99m}Tc -DPD joint scintigraphy with anatomical regions of interest representing the distal femoral growth plate (FGP), the distal femoral epiphysis (FE) and the proximal tibial growth plate (TGP).

Scintimetry

A scintimetric analysis was performed bilaterally on the sagittal scans. Data analysis was carried out on a General Electric Star data processing system interfaced with the gamma camera. Three anatomical regions of interest were created around the activity representing the juxtaarticular femoral and tibial growth plates (FGP and TGP) as well as the distal femoral epiphysis (FE) (Figure 1). In each region of interest, the count ratio (CR) of arthritic versus control limb was calculated. To eliminate the influence of size variation in the anatomical regions, average count ratios (ACR) were calculated as well. For each location, both ratios (e.g. count ratio in femoral epiphysis, CR_{FE}) were plotted against time (Figure 2).

In the controls, intraobserver and interobserver coefficients of variation of the scintimetric method were assessed by a series of double scintimetries of the three regions performed first by the same and later by two different observers.

All counts were corrected for radioactive decay in the time interval between data acquisition of arthritic and control knees.

Contact autoradiography

Two hours after administration of 15–30 mCi ^{99m}Tc -diphosphonate the dogs were killed by an overdose of methohexital and a saturated solution of potassium chloride. Each knee was embedded in an aqueous so-

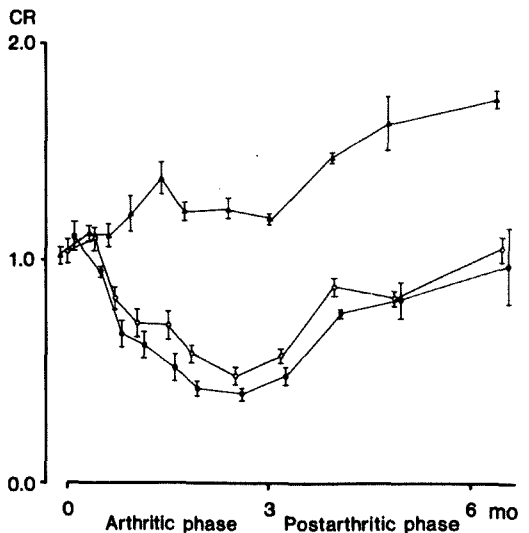


Figure 2. Scintimetry in arthritic and postarthritic phases of juvenile non suppurative arthritis. Count ratio (CR) of arthritic versus control knees \pm standard error of the mean. ● Distal femoral growth plate. ○ Proximal tibial growth plate. ▲ Distal femoral epiphysis.

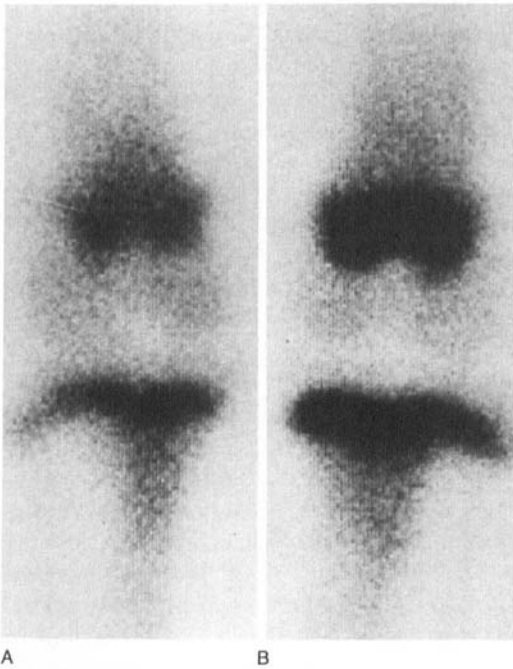

Figure 3. Static ^{99m}Tc -DPD joint scintigraphy in a young dog with Carrageenan arthritis of the right knee for 3 months. A. In the arthritic joint, uptake of radionuclide is depressed in the juxta-articular growth plates in comparison to the contralateral control knee, B.

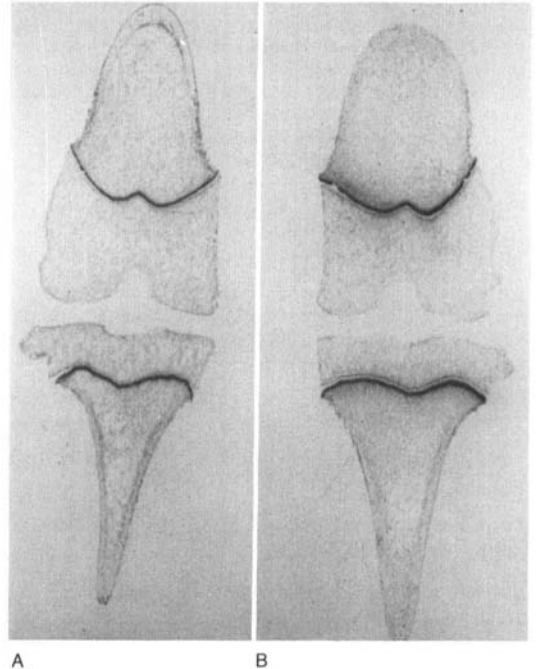


Figure 4. Contact ^{99m}Tc -diphosphonate autoradiography of arthritic knee, A, and control knee, B, after 3 months of unilateral arthritis. Growth plates are narrowed, the uptake of radionuclide in the metaphyseal aspect of the growth plates is decreased, and a discrete increase in activity is found in the subchondral bone at the periphery of the epiphyses.

lution of carboxymethyl cellulose and frozen by immersion in hexane cooled by solid CO_2 at -75°C . In a heavy cryomicrotome, the frozen tissue blocks were sectioned in the coronal plane at progressively deeper levels until the surface was approximately at midarticular level. An X-ray film was then placed in close contact with the cut surface and exposed for 18 hours (Christensen & Krogsgård 1981).

Results

Scanning of the normal immature knee

By direct visual examination of the 11 control joint scintigraphies, no differences between right and left knees could be seen. Nor did the scintimetries reveal any difference. The coefficient of variation was 0.08 between observers and 0.05 for the same observer, which was considered satisfactory.

Scintigraphy in the arthritic phase

Progressive regional differences in uptake of

^{99m}Tc -DPD between arthritic and control knees were encountered during the arthritic phase (Figure 3). By direct visual examination of the joint images, uptake in the juxta-articular growth plates was markedly reduced in the arthritic limb, while uptake in the distal femoral epiphysis tended to increase. Because of the high affinity of tracer for the growth plates, the total uptake in the arthritic joint was decreased. This change could be seen after 14 days of arthritis.

Scintimetry in the arthritic phase

A reduction in count ratio and average count ratio was present in both growth plates from two weeks onwards throughout the arthritic phase (Figure 3, Table 1). At 3 months, CR_{FGP} had decreased to 0.4 and ACR_{FGP} to 0.7 ($p < 0.01$). CR_{TGP} declined to 0.5 and ACR_{TGP} to 0.7 ($p < 0.05$). CR_{FE} , on the other hand, increased to 1.2 after 3 months ($p < 0.01$). ACR_{FE} was above 1.0 throughout the arthritic phase

Table 1. Scintimetric count ratios (CR) and average count ratios (ACR) of arthritic versus control knees in distal femoral growth plate (FGP), distal femoral epiphysis (FE) and proximal tibial growth plate (TGP) before induction of arthritis, after the arthritic phase at 3 months, and after the postarthritic phase at 6 months.

		Controls	3 months	6 months
Counts	CR _{FGP}	1.11±0.07	0.42±0.02	0.97±0.17
Ratio	CR _{FE}	1.02±0.01	1.22±0.04	1.80±0.03
± SEM	CR _{TGP}	1.04±0.04	0.51±0.06	1.05±0.05
Average	ACR _{FGP}	0.96±0.03	0.69±0.03	0.94±0.03
Counts	ACR _{FE}	1.12±0.03	1.14±0.04	1.53±0.10
± SEM	ACR _{TGP}	0.99±0.03	0.71±0.04	0.99±0.01

(NS). Even at the 2 week examination, differences were found between CR_{FE} and CR_{FGP} and between CR_{FE} and CR_{TGP} ($p < 0.01$). Similar changes were observed for the corresponding ACR values ($p < 0.01$). At all times the changes in FGP tended to be more pronounced than in TGP (NS).

Scintigraphy and scintimetry in the postarthritic phase

In the postarthritic phase two patterns of change were prominent: the growth plates returned to a normal scintigraphic appearance and normal scintimetric values, while the uptake of ^{99m}Tc-DPD continued to increase in the articular epiphyses (Figure 3, Table 1). CR_{FE} thus increased to 1.8 ($p < 0.01$), while ACR_{FE} reached 1.5 (NS). At the end of the postarthritic phase, there seemed to be an overall increase in tracer uptake.

Contact autoradiography

By contact autoradiography of the normal immature knee, uptake of radionuclide in the growth plates could be located to a narrow zone at their metaphyseal junction (Figure 4). The epiphyseal uptake took place mainly in a thin rim of subchondral and subsynovial bone, while the uptake of tracer was less in the central epiphyseal bone.

After the arthritic phase, i.e. at 3 months, the growth plates were narrowed. The bone layer at the periphery of the epiphyses showed increased uptake. No change could be seen in the central epiphyseal bone.

In the postarthritic phase at 6 months, the increased subchondral uptake was still present, but in addition increased uptake was located to marginal osteophytes and around bone cysts. The deeper subchondral bone in the epiphyses showed osteopenia with fewer trabeculae and a reduced uptake of diphosphate.

Discussion

Adult arthritis is almost invariably associated with increased articular uptake of bone-seeking radionuclides. The scintigraphic appearance in juvenile arthritis may vary from increased uptake over normal to decreased uptake of tracer (Deutsch et al. 1981, Murray 1982, Wingstrand 1986). In our study, juvenile Carrageenan arthritis, which has been characterized as a reproducible model of human nonspecific juvenile arthritis (Bünger et al. 1984c), resulted in an early onset of progressive reduction in uptake of ^{99m}Tc-DPD in the juxta-articular growth plates. This overshadowed a tendency for increased epiphyseal uptake and gave the joint the appearance of reduced total uptake on scintigraphic images. As inflammation subsided, the growth plates returned to normal, and the increased uptake in the epiphyses dominated the image, probably associated with the onset of osteoarthritis. In clinical disease, these two processes may co-exist in various degrees giving the juvenile arthritis different scintigraphic expressions depending on the duration of synovitis, the balance between inflammation and reparative processes, and the age-influenced metabolic activity of the growth plates.

Other juvenile skeletal or joint diseases may cause decreased tracer uptake, e.g. septic thrombosis and sequestration in acute osteomyelitis or pyogenic arthritis, avascular necrosis as in Calvé-Legg-Perthes disease, or osteolytic processes such as bone cysts or metastases (Stadnik 1979, Murray 1982, Shanahan & Ackroyd 1985). In transient synovitis of the juvenile hip, a reduced uptake of tracer in the proximal femoral epiphysis has been ascribed to reduced blood flow secondary to increased intraarticular pressure (Minikel

et al. 1983, Wingstrand et al. 1985). A significant reduction in blood flow in the femoral head epiphysis following venous tamponade has been demonstrated experimentally (Lucht et al. 1983), but a similar elevation of the intracapsular pressure in the juvenile knee has resulted in an increased blood flow in the distal femoral epiphysis (Bünger et al. 1983). This indicates a difference in the susceptibility of the proximal and distal femoral epiphyses to joint tamponade with respect to avascular necrosis. In earlier studies of the present model, the intraarticular pressure at the arthritic knee was between 5 and 15 mmHg, which posed no threat to the epiphyseal circulation (Bünger et al. 1984a).

In chronic Carrageenan arthritis of the knee, blood flow in the distal femoral epiphysis is increased subchondrally and decreased centrally. The total epiphyseal blood flow is unchanged, but the vascular volume is significantly increased leading to a prolonged transit time of blood. The product of permeability and surface area in the epiphyseal capillaries is increased, thus facilitating the capillary exchange of metabolites in the turnover of arthritic bone (Bünger et al. 1984b, 1986). These findings may partly explain the increased epiphyseal uptake of ^{99m}Tc -DPD and the characteristic distribution of uptake between subchondral and central epiphyseal bone. In microautoradiographic studies in rats, the uptake of diphosphonates paralleled the tetracycline labelling of bone-forming surfaces and areas rich in acid and alkaline phosphatases connected with high rates of bone formation and resorption (Christensen 1985). Thus uptake of tracer essentially reflects remodelling activity. The increased subchondral uptake of tracer seen in the arthritic phase must be an expression of an increased endochondral ossification of the articular cartilage leading to the epiphyseal overgrowth typical of juvenile arthritis (Bünger et al. 1984c, Holm et al. 1985). The reason for this overgrowth is unknown, but the mechanism may be similar to that causing formation of osteophytes in the young cartilage still with growth potentials. In experimental models of arthrosis, the subchondral remodelling is interpreted as an expression of genuine progressive arthrosis underlying areas of car-

tilage destruction (Christensen 1985). Perhaps the changes in the postarthritic phase with a great increase in subchondral uptake and the formation of osteophytes and bone cysts are in fact caused by progressive arthrotic changes in the joint.

In the growth plates, uptake was located to a narrow zone at the junction of the growth plate cartilage and the metaphyseal bone. The uptake target has been identified as the layer of provisional calcification in the cartilage matrix at the ends of vascular loops invading the growth plates. There, ^{99m}Tc -diphosphonate complexes preferentially bind to newly formed bone mineral crystal surfaces not yet covered with collagen fibrils (Christensen 1985). Metaphyseal blood flow in acute Carrageenan arthritis is increased fourfold (Bünger et al. 1984b), whereas flow and vascular volume in the same area decrease to slightly subnormal values in chronic arthritis (Bünger et al. 1985). The thickness of the growth plates was reduced and the uptake of tracer depressed coincident with these changes in chronic arthritis. The increase in flow seen in acute arthritis was not, however, accompanied by an increased uptake of tracer. The reason for this discrepancy between flow and tracer uptake is unclear. Perhaps the increased flow represents extensive metaphyseal bone resorption without any concomitant new bone formation in that area. This would account for the absence of increased tracer uptake and the characteristic hypoplasia of the femoral metaphysis in juvenile chronic arthritis (Bünger et al. 1984c).

Clinically, this investigation implies that the scintigraphic appearance of juvenile arthritis can be a decreased uptake of ^{99m}Tc -DPD due to a depression of growth plate metabolism in spite of active disease. In addition, the regional scintimetry employed in this study has drawn attention to the low uptake of the juxtaarticular epiphyses, where significant scintigraphic changes are easily overlooked due to the intensity of the growth plate uptake. Thus, a radionuclide scanning of a juvenile joint should include a regional scintimetric analysis, and sequential scintimetry may prove valuable in the clinical assessment of juvenile arthritic conditions.

Acknowledgements

This study was supported by the Danish Rheumatism Association grant no. 233-425 and the Danish Medical Research Council grant no. 12-2082.

References

- Bauer, G., Weber, D., Ceder, L., Darte, L., Egund N., Hansson L. I. & Strömkvist, B. (1980) Dynamics of technetium-99m-MDP imaging of the femoral head after hip fracture. *Clin. Orthop. Rel. Res.* **152**: 85-92.
- Bünger, C., Hjermand, J. & Bülow, J. (1983) Haemodynamics of the juvenile knee in relation to increasing intraarticular pressure. *Acta Orthop. Scand.* **54**: 80-87.
- Bünger, C., Bülow, J., Bach, P. & Sølund, K. (1984a) Blood supply of the juvenile knee in arthritis at rest and during exercise. *Trans. Orthop. Res. Soc.* **9**: 44.
- Bünger, C., Hjermand, J., Bach, P., Bünger, E. H. & Myhre-Jensen, O. (1984b) Haemodynamics in acute arthritis of the knee in puppies. *Acta Orthop. Scand.* **55**: 197-202.
- Bünger, C., Bünger, E. H., Harving, S., Djurhuus, J. C. & Myhre-Jensen, O. (1984c) Growth disturbances in experimental juvenile arthritis of the dog knee. *Clin. Rheumatol.* **3**,2: 181-188.
- Bünger, C., Tøndevold, E., Bülow, J. & Hjermand, J. (1986) Microcirculation of the juvenile knee in chronic arthritis. *Clin. Orthop. Rel. Res.* **204**: 294-302.
- Charkes, N. D. (1980) Skeletal blood flow: Implications for bone scan interpretation. *J. Nucl. Med.* **21**: 91-98.
- Christensen, S. B. & Krogsgård, O. W. (1981) Localization of Tc-99m-MDP in epiphyseal growth plates of rats. *J. Nucl. Med.* **22**: 237-245.
- Christensen, S. B. (1985) Osteoarthrosis. Changes of bone, cartilage and reprovial membrane in relation to bone scintigraphy. *Acta Orthop. Scand.* **56**: Suppl. 214.
- Deutsch, S. D., Grandsman, E. J. & Spraragen, S. C. (1981) Quantitative regional blood flow analysis and its clinical application during routine bone scanning. *J. Bone Joint Surg.* **63-A**, 295-305.
- Holm, I. E., Bünger, C. & Melsen, F. (1985) A histomorphometric analysis of subchondral bone in juvenile arthropathy of the dog knee. *Acta Pathol. Microbiol. Immunol. Scand. Sect. A*, **93**: 299-304.
- Hughes, S. (1980) Radionuclides in orthopaedic surgery. *J. Bone Joint Surg.* **69-B**: 141-149.
- Lucht, U., Bünger, C., Krebs, C., Hjermand, J. & Bülow, J. (1983) Blood flow in the juvenile hip in relation to changes of intraarticular pressure. *Acta Orthop. Scand.* **54**: 182-187.
- Minikel, J., Sty, J. & Simons, G. (1983) Sequential radionuclide bone imaging in avascular pediatric hip conditions. *Clin. Orthop. Rel. Res.* **175**: 202-208.
- Murray, I. P. C. (1982) Photopenia in skeletal scintigraphy of suspected bone and joint infection. *Clin. Nucl. Med.* **7**,1: 13-20.
- Sagar, V. V., Piccone, J. M. & Charkes, N. D. (1979) Studies of skeletal tracer kinetics III. Tc-99m (Sn) Methylene Diphosphonate uptake in canine tibia as a function of blood flow. *J. Nucl. Med.* **20**: 1257-1261.
- Shanahan, M. D. G. & Ackroyd, C. E. (1985) Pyogenic infection of the sacroiliac joint. *J. Bone Joint Surg.* **67-B**, 4: 605-607.
- Stadnik, R. C. (1979) "Cold" spot imaging. *Sem. Nucl. Med.* **IX**,1: 2-3.
- Wingstrand, H. (1986) Transient synovitis of the hip in the child. *Acta Orthop. Scand.* **57**: Suppl. 219.
- Wingstrand, H., Bauer, G. C. H., Brismar, J., Carlin, N. O., Petterson, H. & Sundén, G. (1985) Transient ischaemia of the proximal femoral epiphysis in the child. *Acta Orthop. Scand.* **56**: 197-203.