

From the University Departments of Orthopedics in Lund and Umeå, Sweden

# **Slipped capital femoral epiphysis in southern Sweden 1910–1982**

**Lars Ingvar Hansson<sup>†</sup>, Gunnar Häggglund  
and Gunnar Ordeberg**

ACTA ORTHOPAEDICA SCANDINAVICA SUPPLEMENTUM NO. 226, VOL. 58. 1987

---

**MUNKSGAARD · COPENHAGEN**

**ISBN:87-16-06409-7**  
**ISSN:0300-8827**

**Printed in Sweden**  
**Studentlitteratur**  
**Lund 1987**

*Dedicated to  
Gunnar Frising  
Torsten Jerre  
Gunnar Wiberg*



# Contents

<b>Abbreviations</b>	7
<b>Introduction</b>	9
<b>Patients</b>	11
<b>Methods</b>	13
Radiography	13
Epidemiology	14
Heredity	14
Body weight and height	14
Longitudinal bone growth	15
Therapy	16
Statistical methods	18
<b>Results and comments</b>	19
Radiography	19
Epidemiology	22
Sex distribution	22
Age at slipping	23
Delay of diagnosis	25
Side and bilaterality	25
Seasonal variation	27
Incidence	27
Etiology	29
Heredity	29
Body weight and height	32
Longitudinal bone growth	33
Therapy	36
No primary treatment	36
Closed reduction and hip spica	37
Nailing – pinning	39
Femoral neck osteotomy	45
Hook-pinning	48
<b>Discussion and conclusions</b>	51
<b>Summary</b>	55
<b>Acknowledgements</b>	57
<b>References</b>	58
<b>Coded data</b>	65



# Abbreviations

**ICP** Infancy, childhood, puberty  
**M** Mean  
**PCF** Physiolysis colli femoris  
**PHV** Peak height velocity  
**SD** Standard deviation  
**SDS** Standard deviation score



# Introduction

Slipped capital femoral epiphysis, or epiphysiolysis capitis femoris, was first described by Ambroise Paré 1572 (1): “. . . l'épiphyse de la tête de cet os quelquefois se sépare et disjoint, de sorte que le Chirurgien est déçu, estimant qu'il y ait luxation et non disjonction de l'épiphyse dudit os.” The slip occurs through the growth plate (physis) of the femoral neck, not through the growth cartilage of the bony epiphysis. Consequently, in what follows, the denomination physiolysis colli femoris (PCF) will be used.

Until the end of the 19th century, PCF was only sporadically reported and was then associated with trauma. With the advent of radiography, it could be demonstrated that trauma was not the only cause of PCF. During the 20th century, further efforts have been made to determine the etiology of PCF and to improve its treatment. However, despite the fact that several predisposing factors have been identified, the etiology of PCF is still unknown, and there is still no consensus as regards treatment.

Epidemiologic studies have revealed racial, geographic, and sex differences in the incidence of PCF (2, 3). Kelsey et al. (2) made an excellent epidemiologic investigation in New Mexico and Connecticut. However, the population and catchment areas could not be clearly defined, and the incidence values are difficult to compare with those from other populations.

From case reports and investigations based on interviews and clinical reports, a hereditary predisposing factor has been pointed out (4, 5). Because many slippings are asymptomatic (6), the true frequency of PCF among relatives is, however, not known. Animal experiments (7, 8) and case reports on PCF associated with hormonal disorders (9–11) indicate that endocrine disturbances affect the strength of the physis. It is also known from animal experiments that the growth plate is weaker at puberty and at times of rapid growth (8). Additionally, several investigations have shown that PCF children have an abnormal body constitution at the time of diagnosis (12, 13). However, analysis of height and weight in PCF children before, during, and after slipping is lacking.

The recommendations of treatment vary mostly with the degree of slipping. In mild PCF, most authors recommend pinning in situ (12, 14–15) or bone pegging physiodesis (16). In severe PCF, most authors recommend a realignment procedure: osteotomy through the physis or midneck region (17–21), through the base of the femoral neck (21, 22), or at the trochanteric/ subtrochanteric region (23, 24). Most arguments are

based on short-term follow-ups, only concerning the early complications, of which the most serious are osteonecrosis, first described by Axhauser in 1922 (25), and chondrolysis, first described by Waldenström in 1930 (26). However, because the most serious late complication, arthrosis, is not seen until middle life, long-term follow-ups are also required when the different methods of treatment are evaluated (95).

Sometimes there are difficulties in detecting PCF and determining the degree of slipping. Established methods (27–30) are adequate in cases with an open growth plate of the femoral neck. Satisfactory techniques for analyzing the deformity in adults are lacking.

At the Department of Orthopedics in Lund, much interest has been devoted to PCF. Frising (31) studied 32 cases with coxa vara and concluded that PCF can occur without trauma and only secondarily gives rise to coxa vara. Jerre (6), in his classic thesis, analyzed 166 cases of PCF in southern Sweden between 1917 and 1945 and found better results in nontreated cases than in those treated with closed reduction. Wiberg (14, 32) analyzed the short-term results after nailing/pinning and femoral neck osteotomy, and found better results after nailing/pinning than after nonoperative treatment, whereas the results after osteotomy were indecisive.

The national registration of the population and the well-defined catchment areas has made it possible to collect all cases treated for physiolytic of the hip in southern Sweden from 1910 until 1982. The work of Frising, Jerre, and Wiberg has stimulated our investigations; their findings form the basis for comparison of early results with the long-term outcome of PCF. We started our studies in 1978, and we have published most of our findings in several papers (15, 33–46). The present work is an integrated report of our findings, and contains the following subjects:

1. A new radiographic method that is able to determine PCF also after growth-plate closure.
2. An analysis of the incidence and epidemiology of PCF in southern Sweden.
3. An evaluation of the heredity of PCF using radiographic examinations.
4. An evaluation of the growth pattern (a) using roentgen stereophotogrammetric analysis, which, with very high accuracy, reveals small growthrate aberrations, and (b) using the Karlberg (47) ICP (Infancy, Childhood, Puberty) growth model, which is in agreement with what is known about hormonal regulation of growth.
5. The long-term natural history of PCF, and the long-term results after different methods of treatment.
6. The short-term results after hook-pinning; a new device.

# Patients

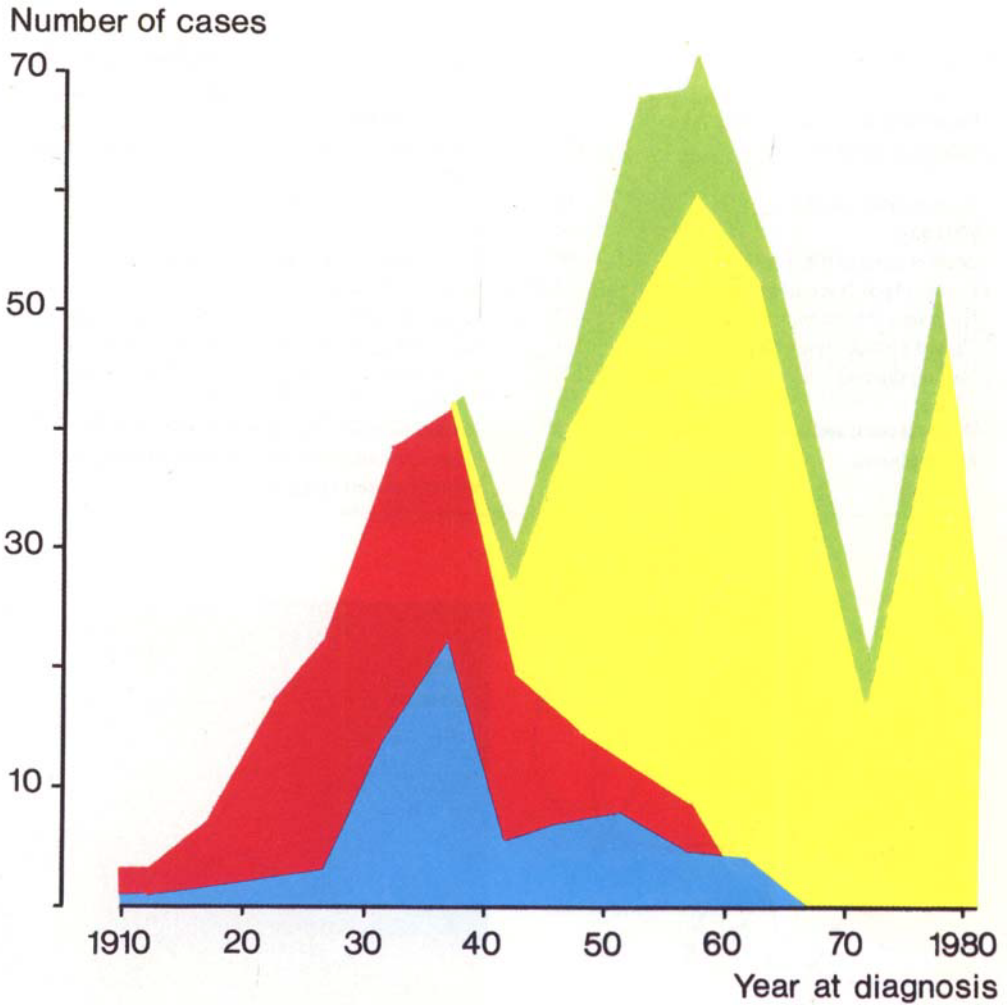


Figure 1. Number of children treated for physiolyis of the hip in southern Sweden over five-year periods 1910–1982. (1980–1982 15 cases, corresponding to 25 cases over 5 years). ■ = no treatment, ■ = hip spica, ■ = femoral neck osteotomy, ■ = nailing or pinning.

All children with PCF diagnosed or treated at three orthopedic departments in southern Sweden (Lund University Hospital, Malmö General Hospital, and Helsingborg Orthopedic Hospital) between 1910 and 1982 were collected from case record registers and operating room log books. Only cases with PCF that were diagnosed radiographically during adolescence were included.

A total of 532 children were treated during this period (Figure 1); 325 of these came from the primary catchment area (Malmöhus County) and 207 children were admitted from outside the county. The material includes the 32 cases described by Frising (31), the 166 cases described by Jerre (6), and 89 nailed or pinned and 26 osteotomized cases described by Wiberg (14, 32).

The material was used totally and in subsets in the different investigations as presented in Table 1.

*Table 1. Number of cases with physiolyis of the hip in the different investigations.*

Epidemiology	532	Total material
Incidence analysis	325	Those living in the primary catchment area (Malmöhus County)
Radiographic method	56	Normal material 120 hips.
Heredity	50	Consecutive cases
Body weight and height	40	From primary sample of 52 consecutive cases
Longitudinal bone growth	32	Primary operation 1977–1982
No primary treatment	57	Reexamined 37 (20–60) years after diagnosis
Closed reduction and hip spica	101	Reexamined 46 (25–66) years after treatment
Nailing/pinning	172	Reexamined 28 (20–42) years after operation;
		Nailing 32 (21–42) years, pinning 25 (20–38 years).
Femoral neck osteotomy	33	Reexamined 28 (16–32) years after operation
Hook-pinning	51	Cases treated 1975–1982 by hook-pinning with or without closed reduction in Lund.

# Methods

## Radiography

In order to develop a method that is able to detect PCF and determine the degree of slipping also after growth-plate closure, the anatomic structure calcar femorale (48) was analyzed and used as a landmark (34).

On radiographs of 80 normal hips (18 males, 22 females; 9–37 years), the calcar femorale was identified on Lauenstein projections and related to the central axis drawn through the center of the femoral head perpendicular to the growth plate or the scar from the growth plate (Figure 2). On an additional 50 normal hips (25 male, 25 female; 10–35 years), the same measurements were made, determining the reliability of the first normal sample. Thirdly, in 34 boys and 22 girls with PCF, the degree of slipping was determined using the relation between the calcar femorale and the central axis obtained in the normal material.

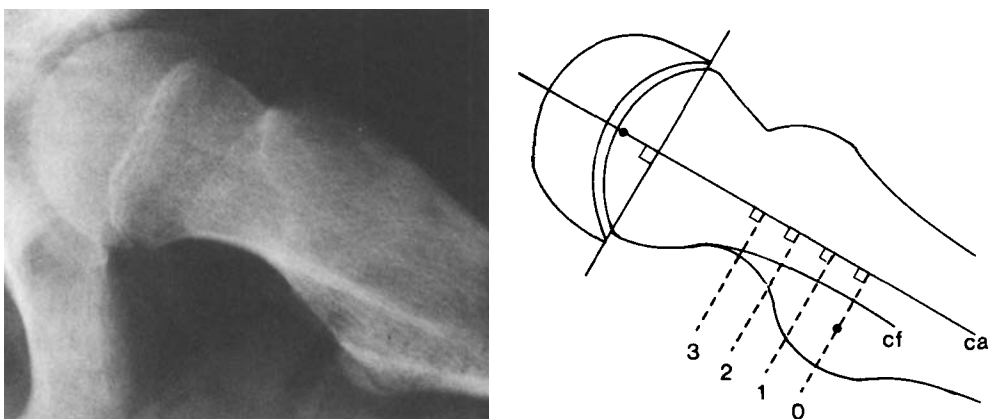


Figure 2. Relation between calcar femorale (cf) and central axis (ca) in a normal hip. Levels of measurement and center of the femoral head and the lesser trochanter indicated.

## Epidemiology

In each case the sex, place of residence, side of slipping, age at onset of symptoms, time of the year at onset of symptoms, and delay between onset and diagnosis were recorded (35). The incidence calculations of the patient material from the primary catchment area were possible because of the national registration of the population.

## Heredity

The first-degree relatives (e.g., parents, brothers and sisters) above the age of adolescence were examined radiographically (37). Anteroposterior and Lauenstein projections were used; and, besides a standard examination, the femoral head/calcar femorale relationship (34) was determined. The families were interviewed regarding PCF among second degree relatives (e.g., grandparents and consanguineous aunts or uncles).

## Body weight and height

To be included, longitudinal records of body measurements had to be available for the period before the age at onset of slipping to skeletal maturity. These were lacking and led to exclusion of 12 probands (7 boys, 5 girls) from the primary sample of 52 patients.

Information on attained weight and height during childhood and adolescence was obtained in all the patients from their individual school growth charts (41). These measurements were generally recorded once a year by school nurses. After the age of pinning the PCF, weight, and height were recorded at annual examinations at the hospital until the age at which subcapital growthplate closure in both hips took place, which occurred 2–4 years after the individual age at maximum gain during puberty. Final height was recorded at least 3 years after the age of maximum gain. From questionnaires, current parental weight and height were obtained in 33 of the 40 families.

The ICP growth model breaks down the body height curve into three additive components, consistent with current knowledge of the regulation of growth (47). The Infancy component represents the postnatal continuation of fetal growth, which appears to be independent of growth hormones and acts during the first 1–2 years of life. The Childhood component, representing the effect of growth hormone (GH) has its onset at 6–12 months of age and shows a decelerating pattern during childhood and adolescence (Figure 3). The Puberty component, the size of which is independent of its timing, describes the part of longitudinal growth stimulated by sexual hormones. By recording the individual age at maximum growth during puberty (peak height velocity, PHV), the puberty component can be determined (Figure 3). Predicted height in a normal population are in the ICP-model adjusted for the individual variations in pubertal maturation (peak height velocity).

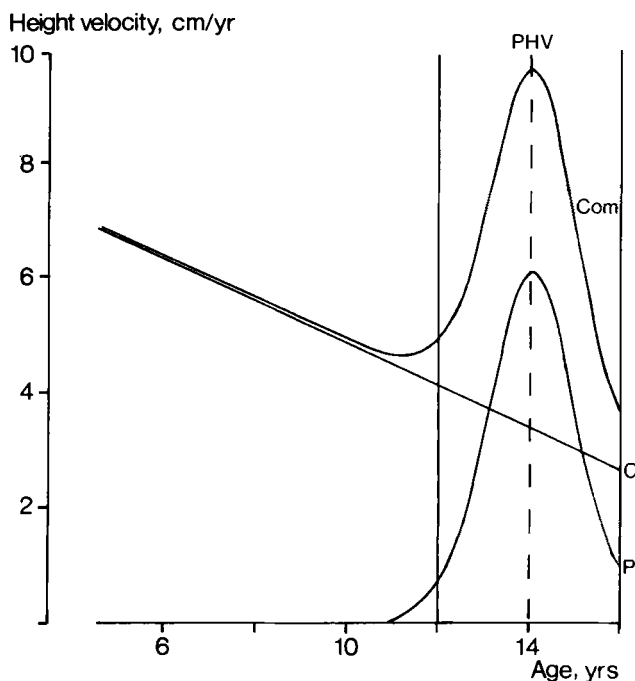


Figure 3. Average height velocity during childhood and adolescence as broken down by the ICP growth model; mean childhood component (C), mean puberty component (P), and mean combined growth (Com), i.e., the sum of the childhood and puberty components. Reference values during adolescence are adjusted individually by timing the puberty component to the actual age at peak height velocity (PHV) for an individual.

Age at PHV was individually determined by observing the individual velocity curve for height, which had been smoothed by a spline function. Age at PHV could be converted into standard deviation scores (SDS, i.e., deviation from the reference mean expressed in units of standard deviation of the normal population) according to reference values given by Karlberg et al. (49). Attained height at 2 years before age at PHV, attained height at maturity (final height), and total gain of height during puberty could all be expressed in SDS (49).

## Longitudinal bone growth

One or two tantalum balls (diam. 0.5 mm) were inserted into the distal fibula on each side of the growth plate at the time of hip surgery or within 1 month after surgery (42). The bone markers were inserted in both legs (18 cases), on the nonslipped side only (7 cases) or on the slipped side only (7 cases). In 1 boy, tantalum balls were inserted 14 months before the diagnosis of PCF. Only growth rates after pinning were used for the mean growth calculations.

The patients were followed with repeated roentgen stereophotogrammetric examinations (50, 51) at intervals averaging 5 (1–29) months. The total observation time averaged 28 (8–61) months.

The growth rate in each case was separated into age groups according to chronologic and skeletal age. Skeletal age was determined on the basis of Greulich and Pyle (52) on radiographs of the wrist. The mean growth rates in different age groups were calculated for the boys and girls separately and compared with a normal material (53). The growth rates during the first and second of the periods of investigation were compared to determine whether the slipping, the pinning, or the initial instability of the markers affected the growth rate. Body height was measured at the time of PCF diagnosis in each patient and compared with the body-length charts of Karlberg and Taranger (54).

## Therapy

Peroperative and postoperative complications were searched for in clinical and radiographic reports.

The patients were followed-up by questionnaire and clinical and radiographic examinations 34 (16–66) years after primary treatment (36, 38, 43, 45, Table 1). The clinical state was classified according to Charnley (55) based on the system of d'Aubigné and Postel (56) (Table 2). The degree of slipping was classified according to Bianco (28) (Table 3), in most cases using the calcar femorale (34). Anteroposterior, lateral, and Lauenstein projections were used, and the calcar femorale was visualized with fluoroscopy. Arthrosis was classified according to Ahlbäck's classification of gonarthrosis (57, Table 4).

On the anteroposterior projections, the articulo-trochanteric distance was measured according to Edgren (58, Figure 4) to discover growth disturbances of the subcapital growth plate.

*Table 2. Classification of function according to Charnley (1979).*

Score	Pain	Motion	Walking
1.	Severe and spontaneous	<30	Few yards or bedridden Two sticks or crutches
2.	Severe on attempting to walk	30–60	Time and distance very limited with or without canes
3.	Tolerable, permitting limited activity	60–100	Limited with one cane (< than 1 hour). Difficult without a cane. Able to stand long periods
4.	Only after some activity. Disappears quickly with rest	100–160	Long distances with one cane. Limited without a cane
5.	Slight or intermittent. Pain on starting to walk but becoming less with normal activity	160–210	No cane, but a limp
6.	No pain	>210	Normal

*Table 3. Classification of slipping according to Bianco (1966).*

		Displacement <sup>a</sup>
0	None	
1	Mild	<1/3
2	Moderate	1/3–2/3
3	Severe	>2/3

<sup>a</sup> related to the diameter of the base of the bony epiphysis.

*Table 4. Classification of coxarthrosis according to Ahlbäck's classification of gonarthrosis (1968).*

0	None	
1	Mild	Reduction of articular space
2	Moderate	Obliteration of articular space
3	Severe	Bone attrition

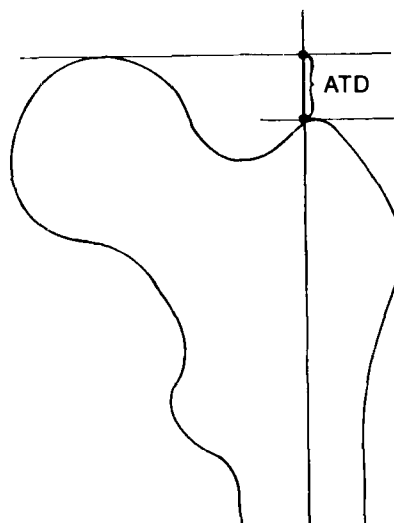


Figure 4. The articulo-trochanteric distance. Redrawn from Edgren (1965).

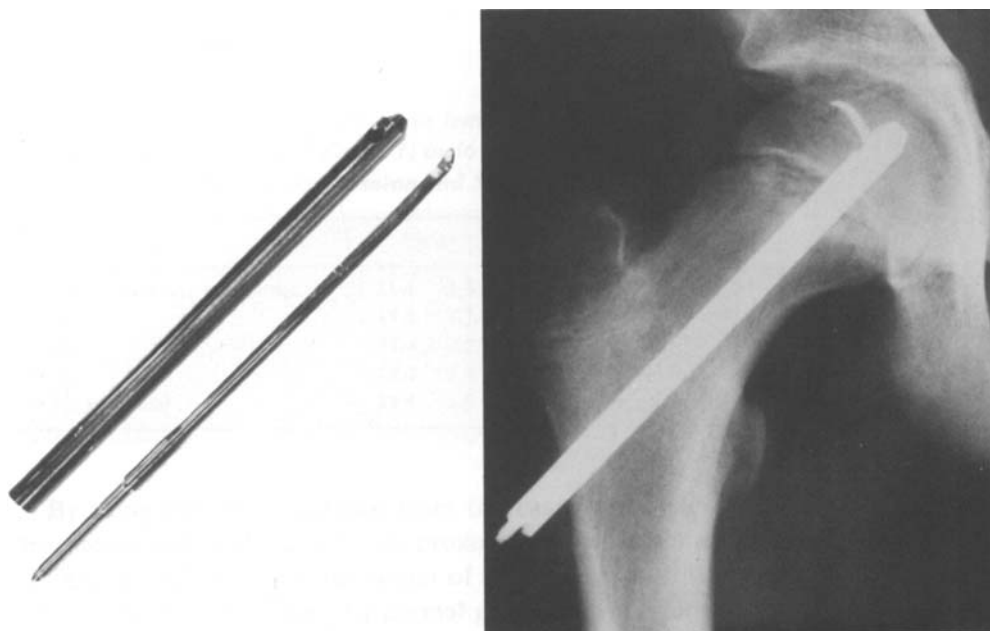


Figure 5. The hook-pin.

In order to eliminate the early complications found after Johansson nailing or Nyström pinning (physeal separation, lost epiphyseal grip, and premature growth plate closure), a pin with a hook was developed (33) (Figure 5). Between 1975 and 1982, the hook-pin was used in 56 slipped hips and prophylactically in 43 unslipped contralateral hips in Lund. The slipped hips were graded as mild: 43, moderate: 11, and severe: 2. The pinning was performed with fluoroscopy. The hook-pin is inserted in a predrilled channel and locked with the hook in the epiphysis. One hook-pin is used in each hip (Figure 5). After in situ pinning, weight-bearing was allowed immediately. After closed reduction and pinning, which was performed in 7 hips with acute moderate or severe displacement, weight bearing was allowed 4–6 weeks after operation.

These 99 hips (51 children; 33 boys – 18 girls) were clinically and radiographically reexamined 6 (3–10) years after the pinning. One hip treated by Nyström pinning 1973, and two hips treated by femoral neck osteotomy were excluded.

## Statistical methods

Depending on the variables, one of the following methods were used: Student's *t*-test, chi-square test, Poisson distribution, or direct calculations using Gaussian approximation.

The following levels of significance were used:

\*\*\* =  $P < 0.001$  Highly significant

\*\* =  $P < 0.01$  Significant

\* =  $P < 0.05$  Almost significant

NS =  $P > 0.05$  Not significant

# Results and comments

## Radiography

In the normal material the calcar femorale was in both sexes distinct from a level below the lesser trochanter and proximal to the area where the lamella joined the posterior cortex of the femoral neck. At the level of the lesser trochanter and 3 cm proximally, the calcar femorale was almost straight, parallel to the central axis and perpendicular to the growth plate (Figure 2). The angle of divergence, both proximally, between the calcar femorale and the central axis was  $2.2 \pm 4.1$  degrees in the males and  $1.2 \pm 3.5$  degrees in the females. The distance between the calcar femorale and the central axis (Figure 2) at different levels is shown in Table 5. Of the girls aged 9–15 years, the distance was, on an average, 0.6 mm less than in adults, and of the boys aged 9–15 years 0.2 mm less.

*Table 5. Distance (mm) between calcar femorale and central axis at different levels (according to Figure 1) in 36 male and 44 female hips (first normal group). Values are mean and SD.*

	Males		Females	
At level of lesser trochanter	<b>11.1</b>	3.4	<b>10.0</b>	3.3
1 cm	<b>11.2</b>	3.1	<b>9.9</b>	3.0
2 cm	<b>11.4</b>	2.8	<b>10.1</b>	2.8
3 cm	<b>12.2</b>	2.4	<b>10.7</b>	2.4
4 cm proximal	<b>14.6</b>	3.7	<b>12.0</b>	2.4

By using the mean distance from the calcar femorale at the level of the lesser trochanter and at the level 3 cm proximal to it, the central axis was predicted. The distance from this axis to the center of the femoral head (Table 6) gives the accuracy of the calculations in the first normal group, and the representativity of the normal material in the second normal group.

When constructing the central axis from the calcar femorale in the PCF material using the mean values from the first normal group, the distance between this axis and the

Table 6. Error of the radiographic method. Positive value means displacement/angulation below predicted central axis. Values are mean and SD.

	First normal group				Second normal group			
	Males		Females		Males		Females	
Displacement of caput center in mm (d)	0.2	2.4	0.0	2.3	-0.7	2.0	0.3	1.9
Angular deviation in degrees (v)	0.1	3.5	0.1	3.3	-1.9	4.8	-0.7	3.6

d and v according to Figure 6.

center of the femoral head depicts the displacement of the epiphysis. Both displacement and angular deformity (Figure 6) increased with degree of slipping according to Bianco (28, Figures 7 and 8). A displacement of 1 mm corresponded to a deviation of about 2 degrees in the males and about 2.5 degrees in the females. Of the contralateral hips judged as normal, the center of the femoral head was displaced  $2.7 \pm 3.9$  mm in the males \*\* and  $4.5 \pm 3.5$  mm in the females \*\*\*. The angular deviation was  $3.5 \pm 5.7$  degrees in the males \*\* and  $8.2 \pm 5.1$  degrees in the females \*\*\*.

*Comments.* The constant relation between the calcar femorale and the femoral head in normal hips provides a method for predicting the original position of the femoral head from the course of the calcar femorale. The calcar must, however, be distinctly visualized. A Lauenstein projection is usually sufficient, but radiography in combination with fluoroscopy is advantageous. With a distinct calcar femorale the method showed high accuracy and small variability in the normal material. From the optimal projection, the calcar femorale becomes increasingly unsharp with internal or external rotation, and is no longer visible after about 20 degrees of rotation. A projection 20

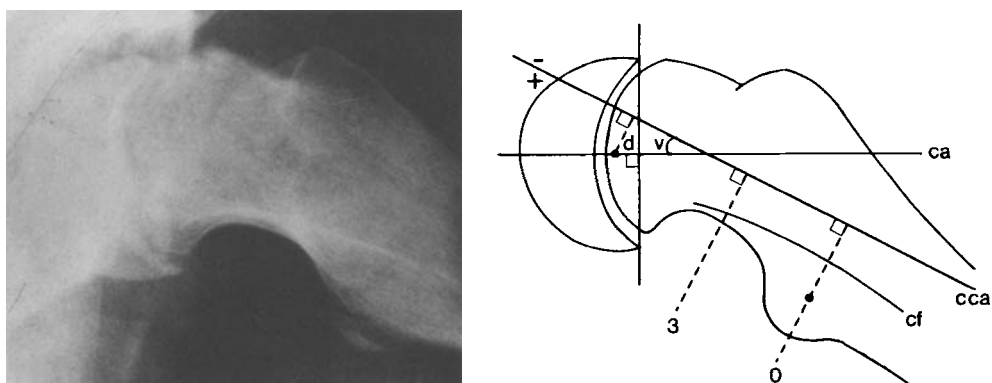


Figure 6. Calcar femorale (cf) with calculated central axis (cca) in physiylsis of the hip. Ca = central axis drawn from the center of the femoral head. d = displacement of femoral head. v = angular deviation.

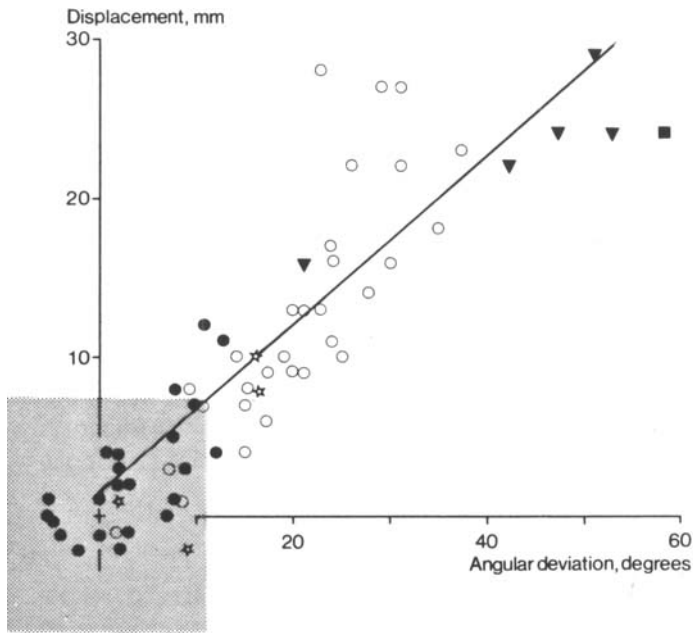


Figure 7. Displacement and angular deviation of femoral head in 34 males with physiolyis of the hip (63 hips). Gray area shows mean value  $\pm$  3 SD in first normal group.  $y=0.8+0.53x$ ,  $r=0.89$ . ● = normal contralateral hip; ☆ = asymptomatic slipping; ○ = mild slipping; ▼ = moderate slipping; ■ = severe slipping.

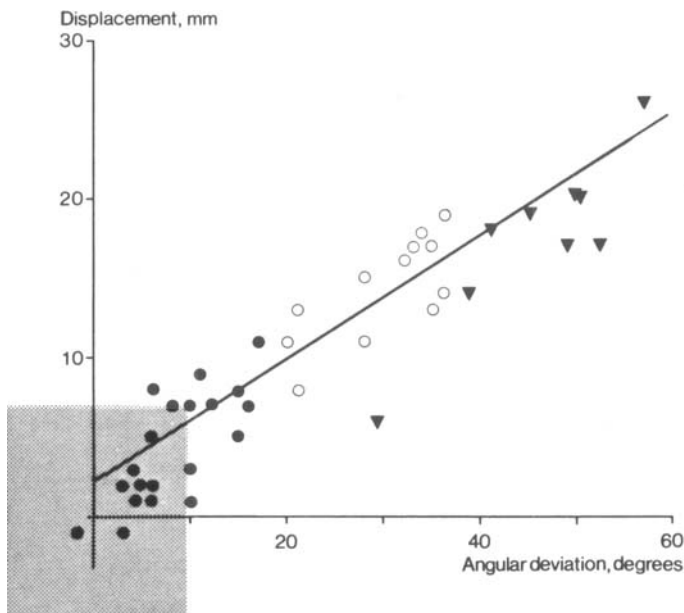


Figure 8. Displacement and angular deviation of femoral head in 22 females with physiolyis of the hip (41 hips). Same symbols as in Figure 5.  $y=1.4+0.39x$ ,  $r=0.92$ .

degrees from the optimal position gives a 6 per cent shortening of the calcar distance ( $1 - \text{calcar distance} \times \cos 20 \text{ degrees}$ ).

The Lauenstein projection is usually the best projection to demonstrate the displacement in physiolysis of the hip (6), as well as the calcar femorale. The direction of the slip is dorsal (29), most probably at a right angle to the calcar femorale. The calcar femorale persists without evident change of position throughout life (59). Also after physiolysis of the hip, we have found an individually constant calcar femorale/femoral head relation when comparing radiographs from adolescence with radiographs more than 20 years after the slipping. Consequently, the method is suitable for evaluating the degree of slipping from radiographs in adults.

Examination of the contralateral hips without known history of hip disease of the PCF patients revealed a minor displacement of the center of the femoral head in several hips (Figures 7 and 8). This displacement could be due to undiagnosed minor slipping (29).

## Epidemiology

### Sex distribution

In total, 372 cases (70 per cent) were boys and 160 (30 per cent) girls. The male preponderance has decreased from 85–90 per cent to 60–65 per cent during the period of investigation (Figure 9). During the whole period, the male preponderance was greater among those living in rural areas when compared with those living in cities \*\*\*.

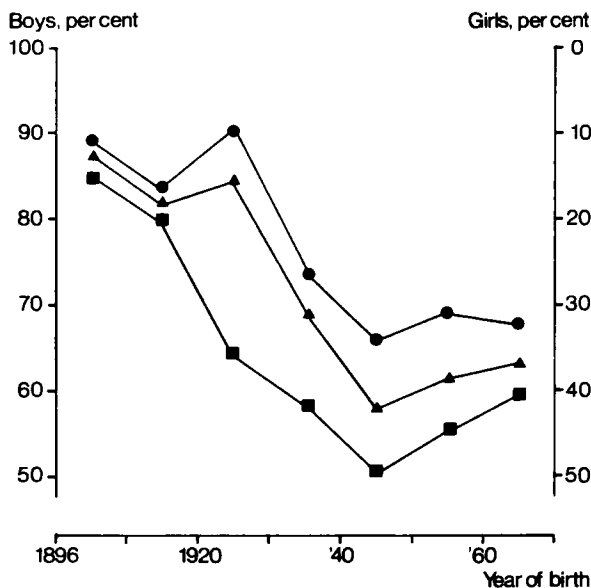


Figure 9. Sex distribution in relation to year of birth and place of residence. ■ = living in cities; ● = living in rural areas; ▲ = total

*Comments.* The male preponderance agrees with most earlier investigations (2, 4, 30, 60). Morscher (8), in rats, found that the growth plate could be more easily disrupted during periods of rapid growth. The growth spurt is greater in boys and lasts for a longer period (61). In addition, boys are more vulnerable at a later chronologic age than girls are, and they weigh more at the time of maximum vulnerability.

Animal experiments (8) have shown that estrogen increases the strength of the growth plate. The same experiments indicate that androgen during earlier periods of sexual maturation decreases physéal strength, whereas in high doses over a prolonged period of time, androgen increases physéal strength.

The divergences could also be a consequence of differences in physical activity with time and place of residence. In the earlier years of the present century, boys in puberty were often working. Symptoms in boys were probably taken more seriously, and more boys with PCF received qualified medical care. Currently, the children in puberty, both boys and girls, are still in school and are given a medical examination regularly.

### Age of slipping

The mean age at onset of symptoms was 14.4 (SD 2.1, range 5.4–23) years in the boys and 12.2 (SD 1.7, range 5.4–23) years in the girls (Figure 10). However, the mean age has gradually decreased: viz., in boys \*\*\* from 16±1.5 years (1896–1909) to 12.7±1.6 years (1960–1969) and in girls \* from 12.6±2.3 years (1910–1939) to 11.8±1.1 years (1950–1969) (Figure 11). No difference in relation to place of residence was found.

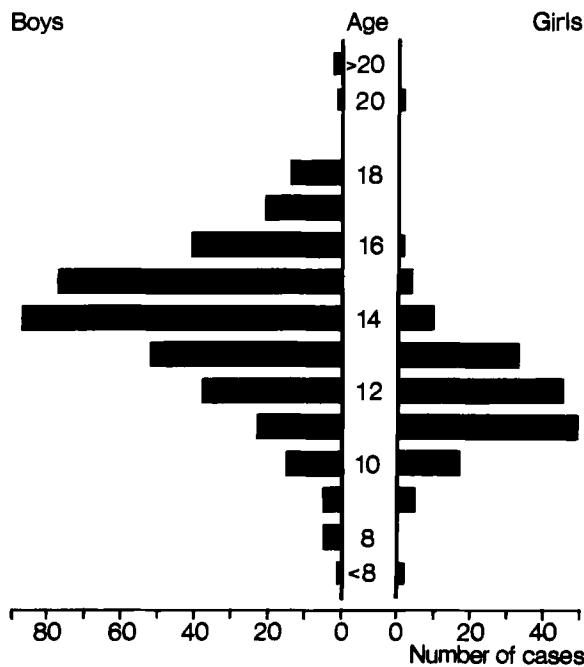


Figure 10. Number of cases in different age groups.

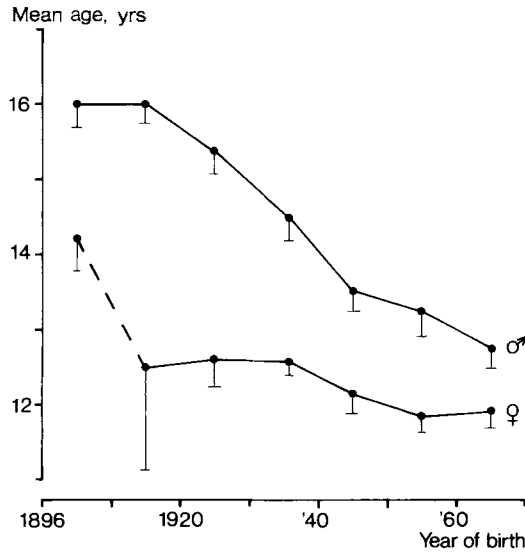


Figure 11. Mean age (with standard error of mean) at onset of symptoms in relation to sex and year of birth.

Four cases had their onset of symptoms at 20–24 years of age. One female with left-sided slipping at aged 20 years and right-sided slipping at aged 24 years had a cerebral tumor compressing the hypothalamus. She had no signs of pubertal development. One male had hypothyreosis, whereas two other males were both described as having had late pubertal development, but no endocrinologic investigations were conducted.

*Comments.* During the first years in the investigative period, there could have been some cases of PCF at an early age that missed registration. There are probably also some individuals born in the 1960s who have not developed PCF by 1982. These cases could influence, to a smaller extent, the mean ages in the corresponding age periods. However, even when comparing those born between 1910 and 1919 with those born between 1950 and 1959, the decrease in afflicted boys is significant \*\*\*.

The age of pubertal development has decreased during the last century (54). Comparisons among various ages of menarche indicate a decrease of 4 to 5 months per decade. The first pubertal changes take place about 1 year earlier in girls, whereas the sex difference in peak height growth velocity is about 2 years (54).

The decreasing age at onset of PCF is probably also in part accounted for by an increased awareness in the social environment, leading to recording of even minor initial symptoms.

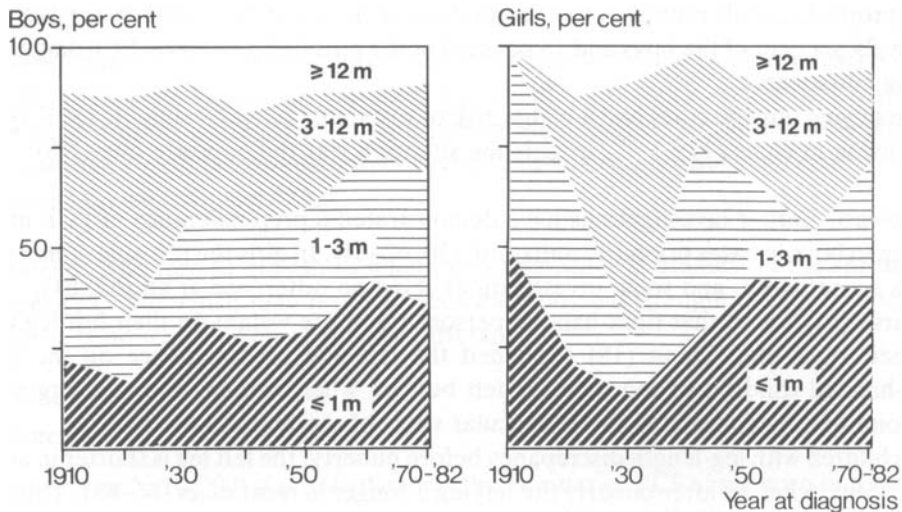


Figure 12. Number of cases related to time (month, m) between onset of slipping and diagnosis.

### Delay in diagnosis

The average duration between onset of symptoms and diagnosis was 4.8 months in boys and 3.4 months in girls. The average diagnostic delay decreased by about 1 month in both the boys and the girls during the period of this investigation (Figure 12).

*Comments.* Despite expanding health care during this century, the diagnostic delay has only slightly diminished. About 40 per cent of the males and 35 per cent of the females still have a history of pain or limping exceeding 3 months before diagnosis.

### Side and bilaterality

In both sexes the left hip was affected more often than the right one (Table 7). However, during the past few decades there has been a tendency \* towards equalization.

At primary admission, 18 boys and 4 girls of the 532 children had a bilateral PCF. Later, during adolescence, 45 boys and 14 girls had a contralateral symptomatic slip, and 24 boys and 7 girls had an asymptomatic slip. During the last 7 years, 30 boys and 19 girls

Table 7. Side affected at primary admission. Number of cases (percent).

	Left	Right	Bilateral	Total
Boys	243 (65)	111 (30)	18 (5)	372
Girls	96 (60)	60 (37)	4 (3)	160
Total	339 (64)	171 (32)	22 (4)	532

were prophylactically pinned in their contralateral hip. Excluding these, it appears that totally 25 per cent of the boys and 18 per cent of the girls had a bilateral PCF diagnosed during adolescence.

Boys living outside cities had a higher risk of sustaining bilateral slipping (30%) than boys living in cities (17%) \*\*. In girls the situation was the opposite one (NS).

*Comments.* Earlier investigations have demonstrated a preponderance of PCF in the left hip in boys in cases primarily unilateral (30, 62–64). In girls the left-side dominance is less accentuated, and some investigations show no difference at all (63, 64).

Marsk (65) found that right-handed persons put more weight on their left leg than on their right one. Dunn (18) explained the left-side predominance on the basis right-handed children sit more on the left buttock when writing, and thus aggravate the condition by congesting the retinacular veins of the femoral neck.

In children with leg-length discrepancy before puberty, the left leg is shorter in about 80 per cent, whereas after puberty the left leg is longer in most cases (66–68). This may indicate that during puberty the average growth rate is greater in the left than in the right leg.

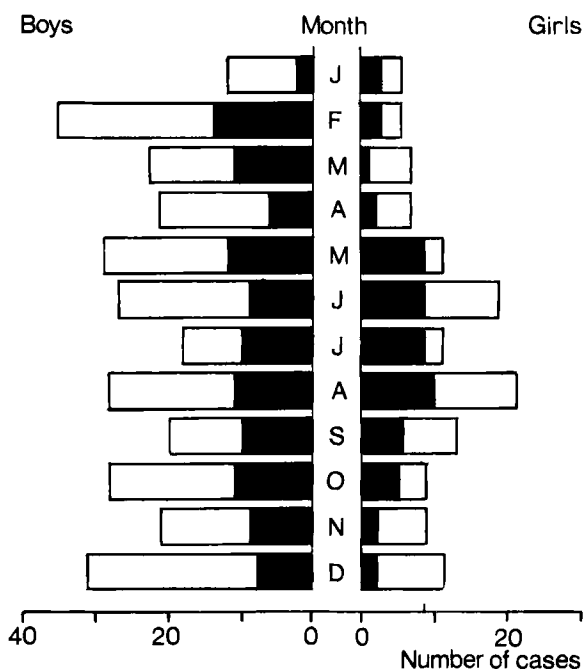


Figure 13. Number of cases related to month of onset of slipping. ■=<1 month between onset of slipping and diagnosis; □=>1 month between onset of slipping and diagnosis.

### Seasonal variation

In 294 boys and 139 girls, the month of onset of symptoms could be determined (Figure 13). In the boys no significant variation was noted. In the girls 46 per cent had their onset of symptoms during the 4-month period May-August. Regarding only females with less than 1 month between onset of symptoms and diagnosis, 59 per cent occurred between May and August \*\*\*.

*Comments.* The rate of growth in length in adolescence is greatest in the spring and summer (69, 70), which may result in decreased physéal strength during this period, but there is no explanation of the sex difference.

### Incidence

The incidence (n/10,000) was calculated as the number of PCF cases born in a specific year in relation to the number of births of that year (Figure 14). The average incidence in boys was 6.1 (range 0–26) and in girls 3.0 (range 0–21). In those born between 1930 and 1965, the average incidence was 7.1 in boys and 5.3 in girls. Boys living in the country have always been at higher risk (7.5) than those living in cities (4.8) \*\*\* (Figure 15). In girls the rural/urban relation has varied.

*Comments.* The results from earlier incidence calculations of PCF (2, 60, 71) are difficult to use because they are based on a heterogeneous population, 2–25 years of age, where the frequency is calculated per year, not taking into consideration the low risk in the younger and in the older age groups. In the present investigation, the incidence is presented as the number of cases with PCF during the entire growth period in relation to the number of males and females born in the same year. The figures should be regarded as minimum values because there are probably cases of PCF that have never been diagnosed for various reasons. The mortality rate between birth and

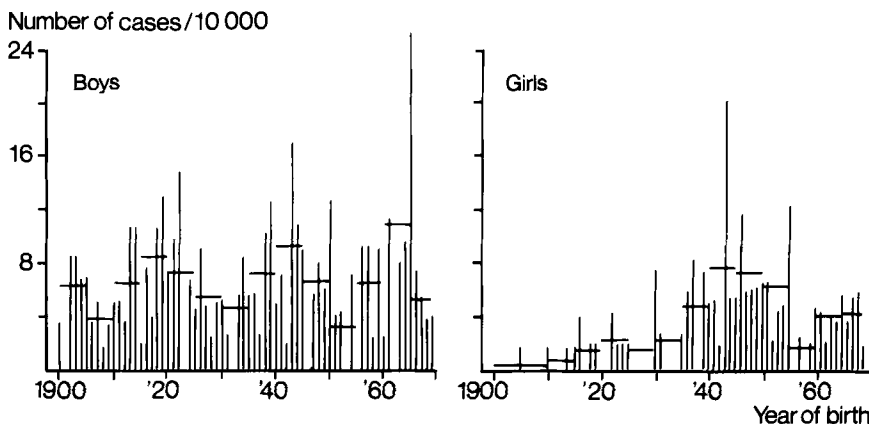


Figure 14. Incidence related to year of birth. Mean values over 5-year periods indicated.

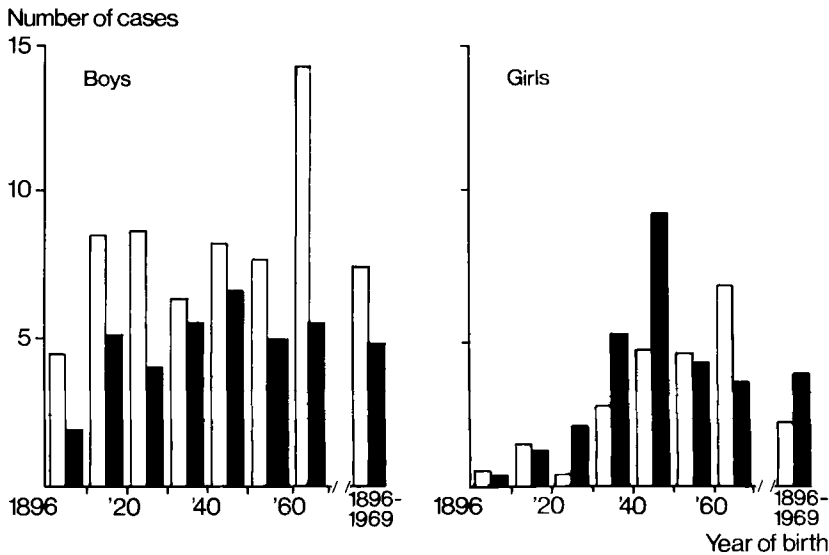


Figure 15. Incidence related to year of birth and place of residence. □ = living in the country; ■ = living in cities.

puberty is very low and could be disregarded. Change of residence during the years up to the onset of PCF is believed to be low and of minor importance.

Jerre (6), in his material containing patients with onset of symptoms between 1917 and 1945, found a higher incidence of PCF in the later years and explained this on the basis that people in the earlier periods did not seek medical advice as often as they did during the later years. It was also explained by an improved diagnostic awareness of PCF among nonspecialists and more frequent consultations with orthopedic surgeons during the later period.

Henriksson (60) found a decreasing incidence of PCF during his period of observation, 1947–1966, and attributed this to the higher standard of living in the later years, including better nutrition during childhood.

Our investigation demonstrates and confirms the same pattern of increase and decrease as that found by others studying the same periods. The long-range follow-up shows, however, that Jerre and Henriksson have analyzed a periodic incidence pattern of PCF in different phases. The decreasing tendency that Henriksson found during the 1960s has been followed by an increasing tendency during the 1970s, which makes the hypothesis about nutrition untenable.

The average incidence of PCF during the latter part of investigation is higher than that during the first part. As Jerre (6) postulated, this is probably because especially girls with minor symptoms did not seek qualified medical advice before 1930. However, there were still some children born in the 1960s who had not demonstrated symptoms of PCF by 1982.

It appears (Figure 15) that the incidence of PCF follows a periodic pattern with peaks approximately every 20th year. The same periodicity is seen in both boys and girls. The incidence, calculated over 5 years, differed by a factor of two to three between the highest and lowest values \*\*\*.

The cause of the periodic incidence pattern remains obscure. Perhaps nutritional or environmental factors with the same periodicity affect patients who are at a risk of contracting PCF. Factors discussed earlier are fluorides in drinking water (72) and aminonitriles in cow's milk (73, 74), but no absolute evidence has been presented.

## Etiology

### Heredity

The series of 50 consecutive cases contained 2 sisters; thus 49 families were investigated. Two parents had died; another was unavailable; and 10 relatives were only interviewed, none of whom had hip complaints.

In three families a first-degree relative was treated for PCF: the 2 sisters in the series, 1 father, and 1 brother. In four families there was a second-degree relative who had been treated for PCF. In one family, both a first- and a second-degree relative were treated for PCF (39, Figure 16).

At examination a marked bilateral slipping was found in the father of the 2 sisters treated for PCF (Table 8). In another 14 first-degree relatives, both the radiographic appearance and the femoral head/calcar femorale relationship were highly suspect for PCF. In all of these hips the femoral head in relation to the calcar femorale was displaced  $>3$  SD dorsomedially.

Totally, there was an obvious additional first-degree relative who was afflicted with PCF in four of the 49 families. When including the second-degree relatives, there were 2 individuals or more with PCF in seven families. If the highly suspect hips are included, 17 families had 2 members or more with PCF.

*Comments.* Earlier investigations on the hereditary transmission of PCF are all based on questionnaires or clinical reports; both Jerre (6) among 153 cases and Wilson et

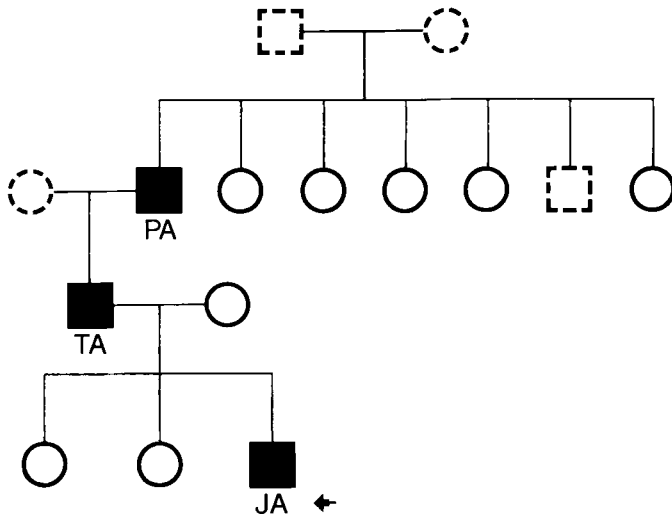
Table 8. Radiographic findings in first degree relatives of patients with physiolyis of the hip (PCF).

Conventional evaluation	Not examined	Normal	Suspected PCF	PCF	Total
Relation femoral head-calcar femorale <sup>c</sup>	Not examined	$<3$ SD <sup>a</sup>	$>3$ SD		
Fathers	5	37	5	2(+1) <sup>b</sup>	49
Mothers	4	38	7		49
Brothers	3	33		1	37
Sisters	1	25	2	1	29
Total	13	133	14	4(+1) <sup>b</sup>	164

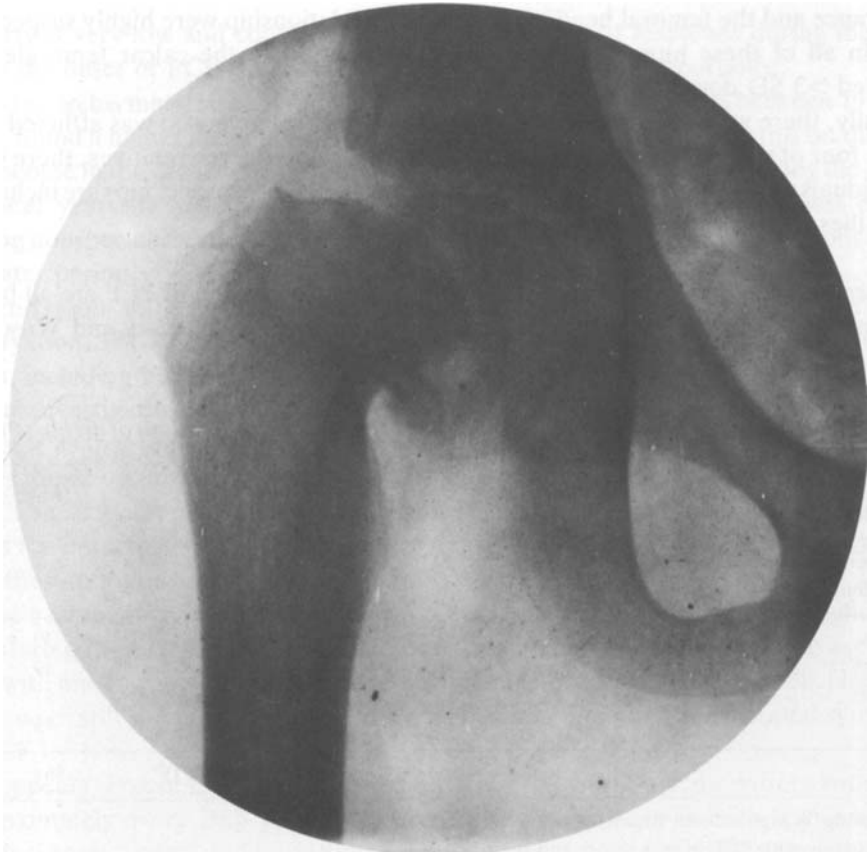<sup>a</sup> Including 38 hips without distinctly visualized calcar femorale.

<sup>b</sup> One family with PCF in two sisters and their father.

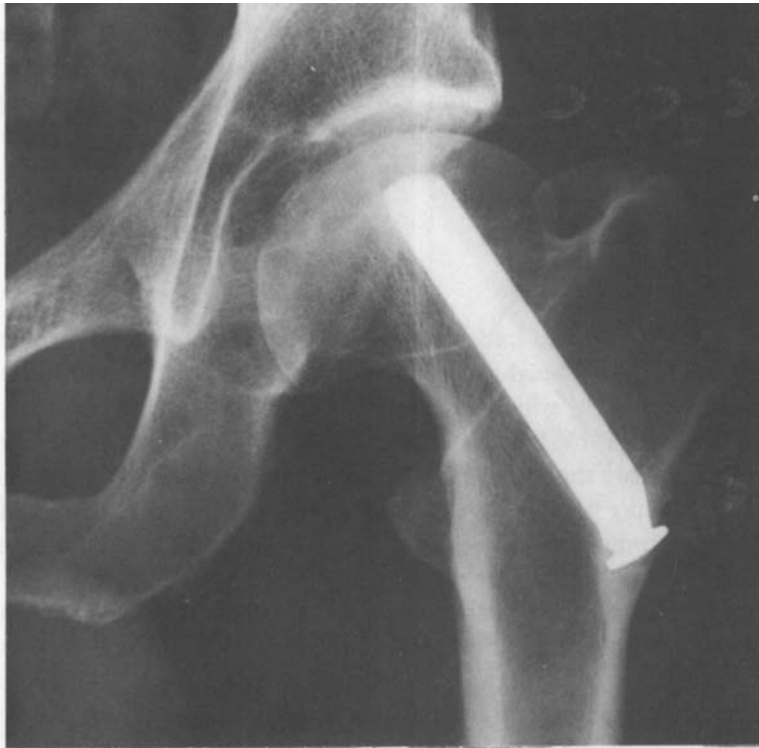<sup>c</sup> Displacement  $>3$  SD was judged as PCF (Hansson et al. 34).



A



B



C

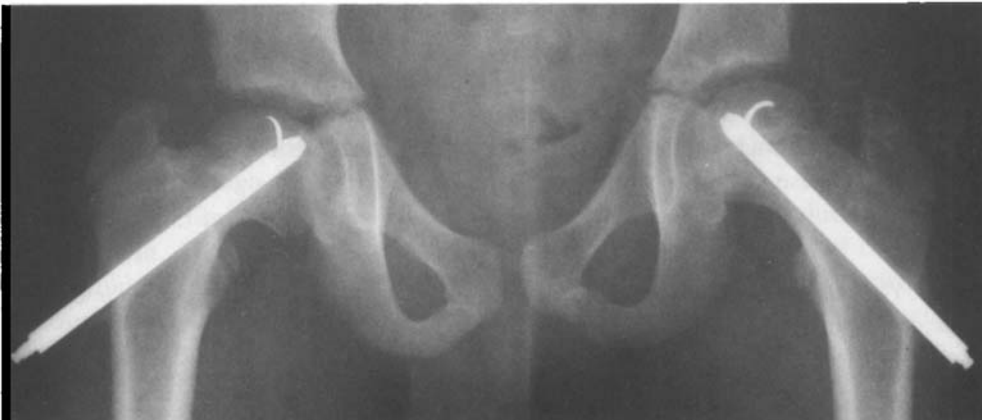

Figure 16. A family with physiolyis of the hip in three generations.  
 A. Family tree. ■ = PCF; ○ = Normal; □○ = Not examined.  
 B. PA, treated with hip plaster spica.  
 C. TA, Johansson nailing.  
 D. JA, hook-pinning bilaterally (prophylactic pinning of the left hip).

al. (4) among 240 cases found a 5 per cent incidence of PCF among close relatives. Finally, Rennie (5) found a 14.5 per cent incidence of PCF among relatives.

In our investigation, six families (12%) had more than 1 known member with PCF before the radiographic examination, corresponding to the previously presented results. The radiographic examination, however, revealed signs of slipping in members of another 11 families, indicating an accumulation of the disease in about one third of the families.

### Body weight and height

None of the patients included had a known hormonal or metabolic disorder.

The average age at peak height velocity (PHV) was  $13.7 \pm 1.3$  years in the boys and  $12.9 \pm 1.0$  years in the girls, which is 0.32 SDS less than normal in boys and 0.96 SDS above normal in girls (Table 9). The onset of slipping (hip symptoms) occurred on an average 1.1 years before the age at PHV, both in the boys and in the girls, i.e., during the period of increasing height gain during adolescence (Figure 17). Five children had their onset of symptoms before this age at increasing growth and 6 children after the age at PHV.

Mean attained height 2 years before age at PHV was significantly increased in both sexes also after adjustment for the individual age at PHV (Table 9). However, at maturity the height was only slightly (NS) above normal. Mean midparental heights were also almost normal, and adjustment for midparental height thus did not affect the mean heights at maturity. Average pubertal gain was, accordingly, lower than normal: 0.96 SDS in the boys \*\* and  $-1.84$  SDS \*\*\* in the girls.

The typical growth pattern found in these children with PCF is exemplified by 1 of the boys in Figure 17. This growth pattern, with an above average height before onset of puberty and a reduced pubertal gain, was found in 20 of the boys and in 14 of the girls. Four boys and 2 girls had an above average pubertal gain in height.

Weight for height, also expressed in SDS, was significantly increased at 2 years before the age at PHV ( $+3.13$  SDS in males and  $+1.85$  SDS in females), and remained increased up to the age at maturity \*\*\* (Table 9). The individual differences in weight for height at these two ages were tested and found to be not significant.

Table 9. Growth pattern in 24 boys and 16 girls with physiolysis of the hip, expressed in standard deviation scores (mean, SD). Two-tailed *t* test.

	Boys			Girls		
1 Age at peak height velocity (PHV)	-0.3	1.2	NS	1.0	1.1	**
2 Height 2 years before PHV	1.1	1.3	***	0.7	0.9	**
3 Same as 2, adjusted for age at PHV	0.9	1.4	**	0.9	1.0	**
4 Height at maturity	0.5	1.2	NS	0.1	0.9	NS
5 Pubertal gain (diff 4-3)	-1.0	1.4	**	-1.8	1.7	***
6 Weight for height 2 years before PHV	3.1	1.9	***	1.9	1.5	***
7 Weight for height at maturity	2.3	1.3	***	2.3	1.8	***

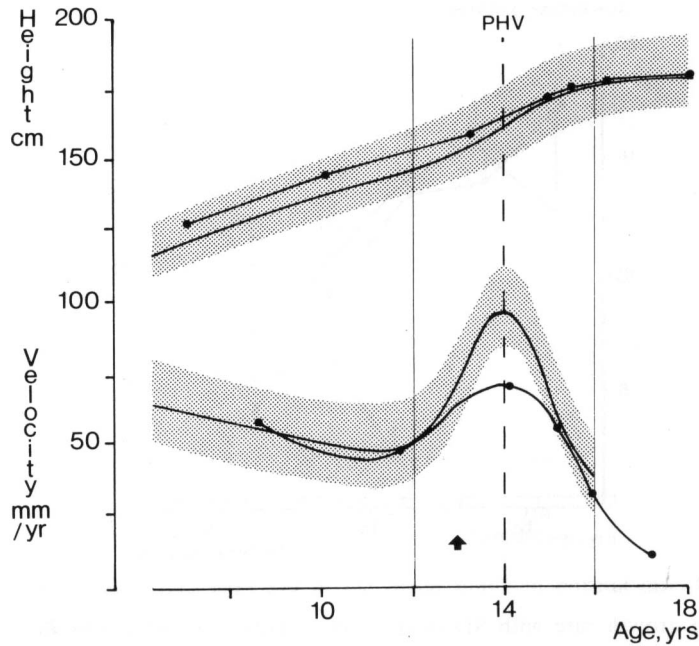


Figure 17. A typical growth pattern for a child (boy) with physiolysis of the hip. Reference values with  $\pm 2$  SD given in terms of the ICP model. Arrow depicts onset of symptoms. Age at peak height velocity (PHV)  $\pm 2$  years indicated.

*Comments.* An important feature of the ICP growth model is that it strongly accords with what is known about the endocrinologic regulation of longitudinal growth (47). The childhood component seems to be dependent mainly on growth hormone (GH), but to a less extent on thyroid hormone. The pubertal component, on the other hand, has been taken into account for the contribution of growth, effected by sexual hormones: testosterone in males and estrogens in females. The abnormal growth pattern before and during puberty in these PCF patients could be due to a disturbed hormonal regulation.

Animal experiments (8) have shown that the physis is weakened during periods of rapid growth. The time at the onset of symptoms was in the majority of cases during the period of increasing growth at the initial phase of the pubertal growth spurt. Because many slippings are asymptomatic (38), the 5 cases with onset of symptoms after PHV could have had their onset of slipping before this age.

### **Longitudinal bone growth**

The average skeletal age in the boys was  $0.5 \pm 1.0$  years lower than the chronologic age. In the girls the average skeletal and chronologic ages were the same ( $0.0 \pm 0.6$  years). In the following presentation skeletal age has been used. There was no difference in growth rate between the first and the second of the periods of investigation. Consequently, all periods were used in the study.

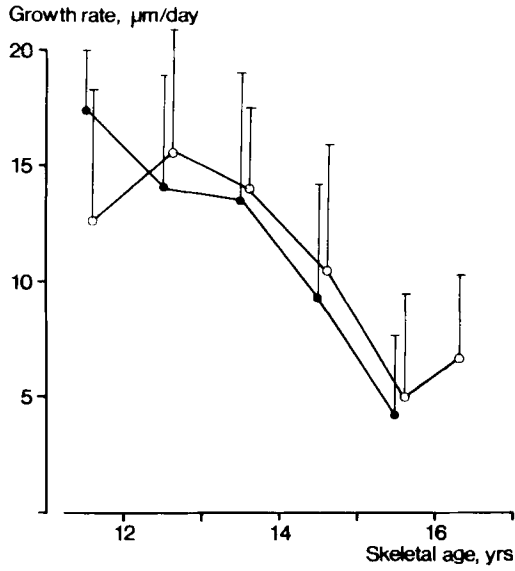


Figure 18. Mean growth rate with SD in the distal fibula in normal boys ● and boys with physiollis of the hip ○.

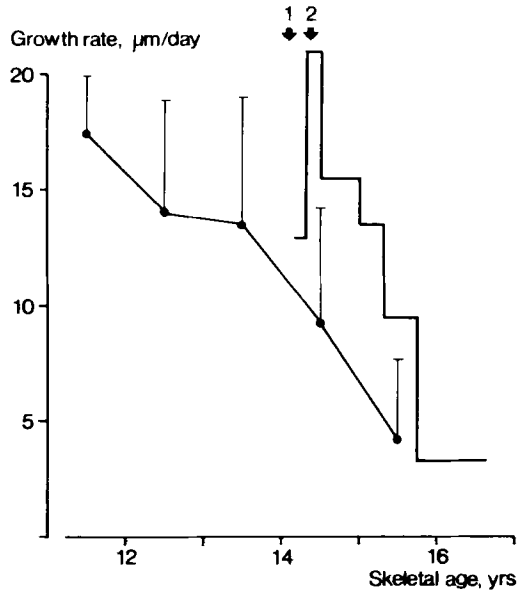


Figure 19. Growth diagram of the left distal fibula in a boy who sustained a fracture on the right ankle (arrow 1) and subsequently developed symptoms of physiollis of the hip bilaterally (arrow 2). Mean normal growth rate with SD indicated.

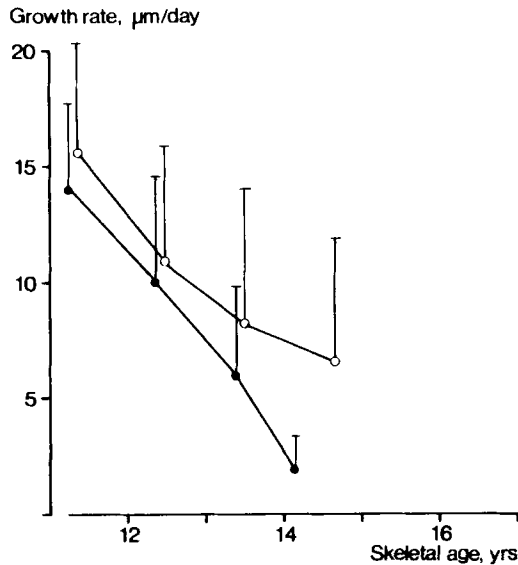


Figure 20. Mean growth rate with SD in the distal fibula in normal girls ● and girls with physiolysis of the hip ○.

The measured mean growth rate in boys with PCF corresponded to the mean growth rate in normal boys, especially after about 12.5 years of age (Figure 18). The mean growth rate before this age was based on only 4 cases.

One boy at the age of 11 years sustained a right-sided ankle fracture, and the distal fibula and tibia on both the fractured and the intact sides were followed up by roentgen stereophotogrammetric examinations (Figure 19). His skeletal age was about 14 years at the chronologic age of 11 years and 3 months. Four months after the ankle fracture, he experienced mild pain in both hips, but did not report his symptoms. Ten months later, bilateral PCF was diagnosed. At onset of symptoms, his growth rate in the intact left distal fibula was about 21  $\mu\text{m}/\text{day}$  (expected about  $9 \pm 6 \mu\text{m}/\text{day}$ ). After about 1 year, his growth rate was almost normal.

In the girls the average growth rates were slightly higher as compared with the normal growth charts (Figure 20), but these differences were not significant.

Body height at the time of diagnosis in relation to normal body length charts is presented in Table 10.

Table 10. Body height related to normal at physiolysis of the hip diagnosis in 22 boys and 10 girls.

		>-1 SD <+1 SD	>+1 SD <+2 SD	>+2 SD
Chronologic age	Boys	13	5	4
	Girls	6	4	
Skeletal age	Boys	9	6	7
	Girls	6	4	

*Comments.* The recorded growth rates were almost normal. Because the accuracy of the RSA method is very high (30–50  $\mu\text{m}$  per measurement, corresponding to 1–2  $\mu\text{m}/\text{day}$ , 53, 75), the SD in the results mainly represents the individual variations in growth rate.

However, 13 children (17 when adjusted for skeletal age) had a body height exceeding the mean value by more than 1 SD at the time of diagnosis. Thus, before diagnosis, these children must have had a higher than average growth rate. This is supported by the result from the boy (Figure 19) with growth measurements also before the slipping (51).

There is normally a seasonal variation in the growth rate (69, 70), with a higher rate during spring and summer. Most patients with PCF have their initial symptoms during the same period (35). This indicates that PCF could be associated with a temporarily increased general growth rate.

In conclusion, there are indications that the skeletal growth rate is slightly accelerated before slipping and fairly normal after slipping.

## Therapy

### No primary treatment

The material of 57 cases includes 16 patients treated with a short period of skin traction and 5 patients treated with a temporary hip spica without previous reduction. However, no case was immobilized for more than 4 weeks, and no attempt at reduction or fixation of the epiphysis was made.

No segmental collapse or chondrolysis was reported in the material.

Of the primary sample, 49 patients were reviewed by questionnaire and 44 by radiographic and clinical reexamination (Table 11).

*Table 11. Number of patients with physiolyis of the hip without treatment.*

	Patients	Hips
Primary material	57	68
Dead at follow-up	7	
Unidentified	1	
Questionnaire	49	59
Clinically and radiographically reexamined	44	53

One man had been operated on for severe arthrosis by three failed arthroplasties, two attempts at hip fusion, and finally a Girdlestone procedure. In this case the function before first operation was used.

All except 1 case, the male operated on for severe arthrosis, had at least tolerable pain and all except 2 could walk long distances at follow-up (Table 12).

Table 12. Function 37 (20–60) years after physiolyis of the hip left without primary treatment.

Grade	1	2	3	4	5	6	Total
Pain	1		3	5	15	35	59
Motion	1	3	1	4	27	17	53
Walking		1	1	7	12	38	59

At the radiographic reexamination, 67 hips showed slipping; 53 of them had been diagnosed during adolescence (Table 13). Of the 67 hips, 36 showed arthrosis. All but one with severe arthrosis also had a severe slipping.

Table 13. Slipping and arthrosis 37 (20–60) years after physiolyis of the hip left without primary treatment.

	Total no of hips	Slipping				Arthrosis			
		0	1	2	3	0	1	2	3
Physiolyis diagnosed during adolescence	53		10	8	35	20	15	6	12
Physiolyis diagnosed at follow-up	14		9	4	1	11	1		2
No physiolyis at follow-up	21	21				20	1		
<b>Total</b>	<b>88</b>	<b>21</b>	<b>19</b>	<b>12</b>	<b>36</b>	<b>51</b>	<b>17</b>	<b>6</b>	<b>14</b>

*Comments.* No early complications were registered. Most slipped epiphyses have a normal vitality at diagnosis (40); segmental collapse and probably also chondrolysis should in most cases be regarded as a complication of the treatment and not of the slipping.

The long-term results after no primary treatment seems favorable confirming Boyer et al (95). Maybe some cases with acute severe slipping and much pain were treated by closed reduction and hip spica, leaving those with less slipping without primary treatment. However, at follow-up, 36 of the 67 hips showed severe slipping, but several of these hips had mild slipping at primary admission, with progress to severe slipping during the adolescent period.

### Closed reduction and hip spica

All 101 cases were treated by attempted closed reduction under anesthesia and were then immobilized in hip plaster spica in abduction and internal rotation, usually for 3 months. Fifty-eight of the hips were investigated earlier by Jerre, who had access to primary radiographs; only 11 hips showed an evident improved position after the reduction maneuver.

*Early complications.* In 1 boy the femur fractured during reduction, but healed without sequelae during the immobilization period. Four hips developed chondrolysis and 15 hips segmental collapse. One boy with chondrolysis was operated on with arthrodesis at 17 years of age.

*Follow-up.* Of the primary sample of 101 cases, 72 were reviewed by questionnaire and 65 were clinically and radiographically reexamined (Table 14). Besides the boy operated on with arthrodesis at aged 17, 24 patients (27 hips) had been operated on at follow-up using arthrodesis (8), McMurray osteotomy (3), and arthroplasty (16). In these cases preoperative radiographs and information on hip function were used for evaluation.

Table 15 shows the function at follow-up. All cases with segmental collapse or chondrolysis had severe pain and limited walking capacity.

Of the 65 patients examined radiographically, 108 hips showed slipping; 32 of these were not diagnosed during adolescence (Table 16). Of the 71 reduced hips, 55 had arthrosis. Of 11 hips with known improved position of the epiphysis seven had severe

Table 14. Number of patients treated by closed reduction and hip spica.

	Patients	Hips
Primary material	101	112
Dead at follow-up	20	
Unidentified	9	
Questionnaire	72	79
Reexamined	65	71

Table 15. Hip function 46 (25–66) years after closed reduction and hip spica.

Grade	1	2	3	4	5	6	Total
Pain	5	16	10	11	12	25	79
Motion	19	12	11	8	9	12	71
Walking	2	20	18	4	11	24	79

Table 16. Slipping and arthrosis 46 (25–66) years after closed reduction and hip spica.

	Total no of hips	Slipping					Arthrosis				
		0	1	2	3	a	0	1	2	3	a
Closed reduction and hip spica	71			15	55	1	16	7	3	45	
Physiolysis diagnosed at follow-up	32		20	10	2		14	10	1	4	3
No physiolysis	22	22					17	1		1	3
Total	125	22	20	25	57	1	47	18	4	50	6

a Classification not possible. Five hips with other methods of treatment in the contralateral hip excluded.

arthrosis. Degree and frequency of arthrosis increased with degree of slipping and with follow-up time (45).

*Comments.* Segmental collapse or chondrolysis occurred in 19 of the 112 hips. There was probably damage to the vascular supply of the epiphysis during the reduction maneuver. This also explains the inferior results in hips with changed position of the epiphysis after the attempted reduction compared with those without improved position.

Immobilization of the hip in internal rotation is known to result in a high intrarticular pressure (76). This could explain the inferior results in the slipped hips, with or without reduction, when compared with the nontreated slippings. After slipping, the vascular supply is probably more vulnerable than in normal hips; the unslipped hips immobilised in hip spica did not develop arthrosis.

### **Nailing – pinning**

In the 172 patients, 204 hips were nailed or pinned. The three-flanged stainless steel Johansson nail or a Vitallium® nail of essentially the same type (Figure 21) was used in 116 hips. The Nyström pin made of of stainless steel or of Vitallium® was used in 88 hips. Totally, 179 hips were operated on without reduction and 25 hips with reduction (23 closed, two open).




Figure 21. Johansson nail (left) and Nyström pin (right).

Table 17. Early complications in 116 nailed and 88 pinned hips.

	Nailed	Pinned	Total
Physcal separation	11	2	13
Perforation of subchondral bone	4	3	7
Fracture	4	0	4
Segmental collapse	5	3	8
Chondrolysis	0	0	0
Lost epiphyseal grip due to sliding	8	5	13
Lost epiphyseal grip due to growth	1	13	14

The complications listed above occurred in 29 nailed and 24 pinned hips.

*Early complications (Table 17).* Peroperative physcal separation and displacement of the epiphysis was described in 11 hips after nailing and in two after pinning. The nail/pin was withdrawn about 5–10 mm in five hips. In two hips the nail was extracted and replaced with a Nyström pin. The diastasis was eliminated by hammering on the trochanteric area in three hips. In the remaining three hips the diastasis was left, but disappeared soon after surgery.

Perforation of the subchondral bone of the femoral head was recorded in four hips after nailing and in three hips after pinning. In all the cases the nail/pin was withdrawn 5–10 mm. In 1 male the guide wire broke when the surgeon was driving in the nail. The proximal part, which did not penetrate the subchondral bone, was left in the bony epiphysis.

Deep infection was noted in 2 patients. Both infections healed without sequelae after operative drainage and nail extraction.

The femur fractured at the level of the base of the nail in four hips after Johansson nailing 3, 12, 12, and 13 months, respectively, after operation. In all instances the fracture was due to trauma.

Segmental collapse was recorded in five hips after nailing and in three hips after pinning. Half of these patients had closed reduction performed prior to osteosynthesis.

Lost epiphyseal grip due to sliding of the nail/pin before physcal closure was recorded in eight hips after nailing and in five hips after pinning. Renailing/pinning was performed in 11 hips. In three hips there was sliding of the reinserted nail/pin, and a third operation with nailing/pinning was performed. In 2 children the nail was extracted. One of these sustained maximum slipping and was reoperated on by femoral neck osteotomy 3 years after the primary operation.

Lost epiphyseal grip due to the growth in length of the femoral neck was seen in one hip after nailing and in 13 hips after pinning. All 14 hips were reoperated on by fixation with a longer nail or pin. Three pinned hips required another reoperation and a longer pin.

*Follow-up.* Of the primary sample of 172 cases, 153 were reviewed by questionnaire and 132 were clinically and radiographically reexamined (Table 18). Owing to severe arthrosis, three males had been operated on using arthrodesis, McMurray osteotomy, and total hip replacement, respectively. In these cases preoperative radiographs and information on hip function were used for evaluation.

Table 18. Number of patients operated on by nailing/pinning.

	Patients	Hips				
		Total	Nailed	Pinned	In situ	Reduction
Primary material	172	204	116	88	179	25
Dead at follow-up	7	8				
Excluded	1	1				
Unidentified	11	14				
Questionnaire	153	181	101	80	161	20
Reexamined	132	157	87	70	140	17

Table 19. Hip function 28 (20–42) year after nailing/pinning.

Grade		1	2	3	4	5	6	Total
Pain	in situ	3	11	15	13	3	116	161
	reduction	1	6	4	1	1	7	20
Motion	in situ	1	2	2	19	66	50	140
	reduction	2	2	1	3	8	1	17
Walking	in situ			1	8	24	128	161
	reduction		1	1	4	2	12	20

Table 20. Slipping and arthrosis 28 (20–42) years after nailing/pinning.

	Total no of hips	Slipping					Arthrosis			
		0	1	2	3	a	0	1	2	3
Nailing/pinning in situ	140		14	51	72	3	106	29		5
Nailing/pinning with reduction	17		1	4	11	1	8	1		8
Slipping diagnosed at follow-up	55		39	14	2		39	15		1
No slipping at follow-up	44	44					42	2		
Total	256	44	54	69	85	4	195	47		14

a Slipping, classification not possible. Eight hips with other methods of treatment in the contralateral hip excluded.

Hip function at follow-up is presented in Table 19. The four hips with pain at rest and the seven hips with a total range of motion below 60 degrees all had Grade 3 arthrosis.

Among the 132 patients examined radiographically, 220 hips showed slipping. Eighty-eight patients (67%) had bilateral slipping, and of these, 55 were not diagnosed during adolescence; further, arthrosis was seen in 16 of these undiagnosed slippings (Table 20). There were more nailed than pinned hips with severe slipping (Figure 22), and more hips with severe slipping during the earlier years (Figure 23).

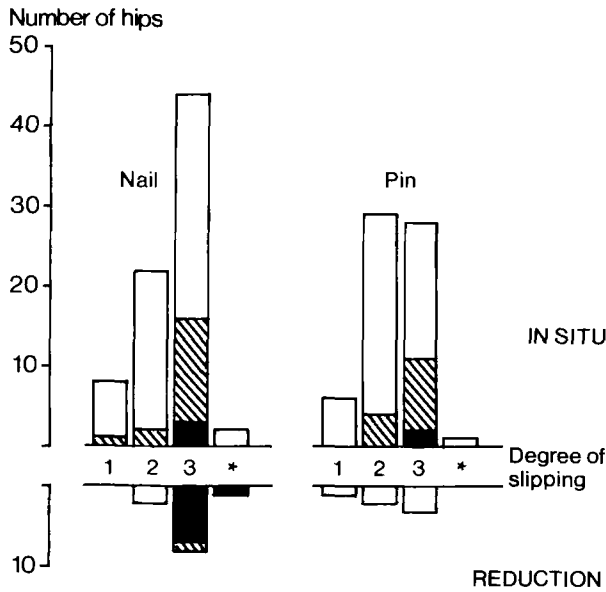


Figure 22. Arthrosis in relation to nailing/pinning and degree of slipping in 157 nailed/pinned hips. In reduced hips, degree of slipping at follow-up. ★ = slipping, classification not possible. □ = No arthrosis; ▨ = Grade 1 arthrosis; ■ = Grade 3 arthrosis. (No hip with grade 2 arthrosis at follow-up).

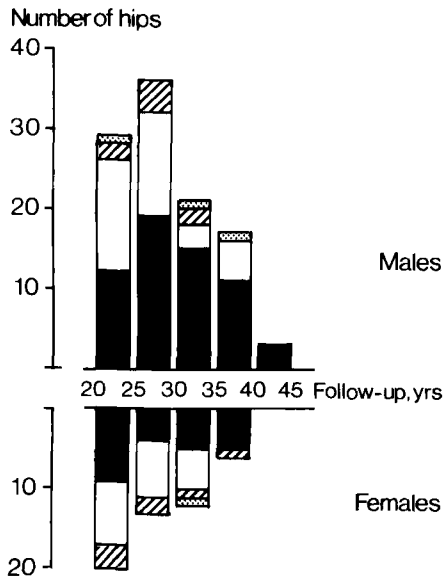


Figure 23. Slipping in relation to follow-up time in 157 nailed/pinned hips. In reduced hips degree of slipping at follow-up. ▨ = mild slipping; □ = moderate slipping; ■ = severe slipping; ▩ = slipping, classification not possible.

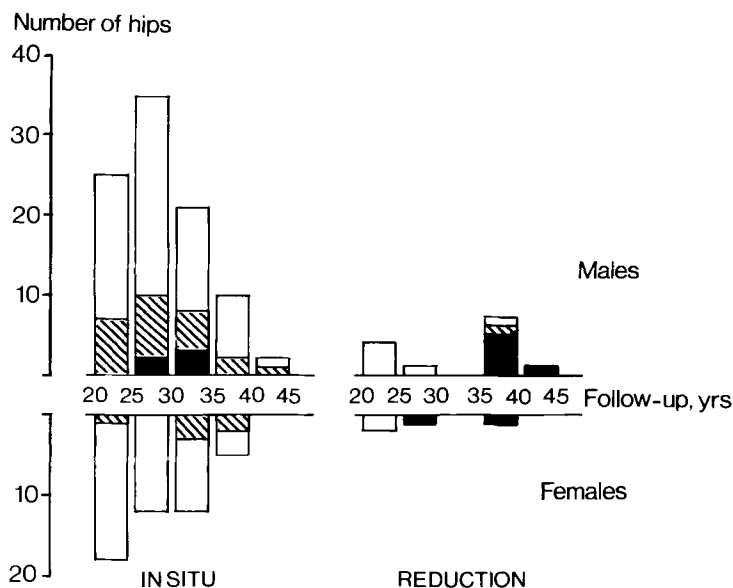


Figure 24. Arthrosis in relation to follow-up time in 157 nailed/pinned hips. Same symbols as in Figure 22.

Arthrosis was seen in 43 of the 157 nailed/pinned hips at follow-up: 34/140 after fixation in situ and 9/17 after fixation with reduction (Table 20). Frequency and severity of arthrosis increased with degree of slipping (Figure 22). However, among those operated on without reduction, there was no increased arthrosis with time during the period 20–40 years after surgery (Figure 24). Seven of the 9 patients operated on with reduction more than 35 years ago had severe arthrosis (Figure 24).

The radiographic findings in the cases with various early complications (Table 21) showed that only segmental collapse was correlated with arthrosis.

Table 21. Slipping and arthrosis at follow-up in relation to early complications in 157 nailed/pinned hips.

	Slipping				Arthrosis				Total
	1	2	3	a	0	1	2	3	
Physcal separation	3	6	1		9	1			10
Perforation of subchondral bone	1		4		3	2			5
Fracture		1	2		1	2			3
Segmental collapse	1	1	2	1	2			3	5
Lost epiphyseal grip due to sliding	2	5	4		9	2			11
Lost epiphyseal grip due to growth	2	8	3	1	13	1			14

a Slipping; classification not possible. The complications listed above occurred in 42 hips.

Table 22. *Articulotrochanteric distance in mm [mean (SD)] related to treatment and degree of slipping. Number of follow-up cases in italics. Normal values: 21±7 mm (Ordeberg et al. 1986b).*

	Slipping		
	Mild	Moderate	Severe
No treatment	17 ( 6.0) <i>10</i>	17 (9.8) <i>8</i>	8(12.4) <i>35</i>
Closed reduction-hip spica		14 (7.5) <i>11</i>	10( 7.4) <i>28</i>
Femoral neck osteotomy			12( 5.6) <i>27</i>
Johansson nailing	11 (10.3) <i>8</i>	17 (7.9) <i>25</i>	9( 7.2) <i>48</i>
Nyström pinning	22 ( 5.7) <i>8</i>	16 (5.5) <i>31</i>	13( 5.7) <i>31</i>

The position of the nail or pin in relation to the anticipated position of the growth plate was analyzed in the 74 hips with the nail/pin left at follow-up. In 16 out of 43 nailed hips and in 12 out of 25 pinned hips, the nail/pin ended distally to the physal scar and in another six hips the relation was doubtful. However, no correlation between nail/pin position and slipping or arthrosis was seen (Table 21).

The articulotrochanteric distance was slightly decreased in the nailed mild slippings when compared with pinning or nonoperative treatment (Table 22). There were also more nailed hips (eight) than pinned hips (two) with an articulotrochanteric distance >2 SD below the normal (46). However, no mean difference was seen between nailed and pinned hips with moderate or severe slipping.

Twenty-one former patients answered the questionnaire, but were not able to come for a reexamination. From the questionnaires the long-term results in these former patients seemed to correspond to those of reexamined patients: all walked unlimited distances, 14 were asymptomatic, 4 had pain only after some activity, and 3 of them experienced pain only initially when starting to walk. None of them had been operated on for arthrosis.

*Comments. Early complications.* Physal separation was more frequent after osteosynthesis with the blunt Johansson nail than with the pointed Nyström pin. Contrary to the report by Wilson et al. (4), this complication was not associated with segmental collapse or arthrosis.

Perforation of the subchondral bone is probably more frequent than has been recorded using AP and Lauenstein projections (77–79). Perforation has been associated with chondrolysis (77). In our investigation, there was no identified case with chondrolysis secondary to perforation of the subchondral bone. At the follow-up examination, however, 2 patients out of 5 with previous perforation had Grade 1 arthrosis.

Lost epiphyseal grip due to the growth in length of the femoral neck was considerably more frequent after pinning (Table 17). Probably there is greater damage to the physis when driving in the blunt nail, resulting in an increased risk of growth retardation and premature growthplate closure. This theory is supported by the differences in articulotrochanteric distance found between the nailed and the pinned hips. After lost grip due to sliding or growth in length, there is a risk of further slipping. Upon adding

those reoperated on because of lost epiphyseal grip to those with the physeal scar proximal to the nail/pin at reexamination, it appears that, if diagnosed before physeal closure, about 45 per cent of nailed and 70 per cent of pinned hips require renailling/pinning before growth-plate closure to prevent reslipping. If nails or pins without satisfactory anchorage in the bony epiphysis are used, the patient must be followed radiographically up to growthplate closure to avoid this complication. Correspondingly, the nail/pin must not be removed before growthplate closure. In fact, the case excluded from follow-up because of secondary operation with femoral neck osteotomy should be regarded as a failure for this reason.

Segmental collapse was seen in four hips out of the 25 treated with reduction before nailing/pinning. The high risk accords with the results after closed reduction and hip spica (6,45). Most of the reduced hips were still considerably displaced and showed a low articulochanteric distance, indicating residual and severe displacement and/or growth disturbance.

*Follow-up.* Most patients had a normal range of motion and walked long distances without walking aids. Some had pain due to pin protrusion or metallic corrosion, which disappeared after nail/pin extraction.

The preponderance of severe slippings during the earlier years (Figure 19) and among nailed hips (Figure 18) could be accounted for the longer delay between onset of slipping and diagnosis during the earlier years (35). Further, during the 1950s and early 1960s, when pinning was mostly used, some hips with severe slipping were treated by femoral neck osteotomy.

No Grade 3 arthrosis was seen among patients with mild or moderate slipping at follow-up, whereas among 83 patients with severe slipping, there were 13 with Grade 3 arthrosis. Arthrosis was about twice as frequent after reduction than after fixation in situ. Regarding Grade 3 arthrosis only, the difference was 13 to 1.

In summary, the only early complication associated with arthrosis was segmental collapse. This complication occurred in 4/25 hips operated on with reduction and in 4/179 hips operated on with fixation in situ. Arthrosis increased with the degree of slipping and was more frequent after reduction than after fixation in situ. Arthrosis did not increase with follow-up time among those nailed or pinned without reduction.

### **Femoral neck osteotomy**

In all 33 patients (hips) the preoperative displacement was reported as severe. The operative technique and the postoperative management have been described in detail by Wiberg (32). The osteotomy was performed with the base cranioventrally, and the epiphysis was fixed to the neck with a flanged screw. After operation the hip was immobilized in a hip plaster spica with abduction and inward rotation for 8 to 12 weeks. Weight bearing was allowed approximately 12 weeks after surgery.

*Early complications.* Eight hips developed segmental collapse, and three hips showed chondrolysis. One male with postoperative infection also had segmental collapse and chondrolysis, which could be a result of a septic arthritis. These 10 cases were treated with nonweight-bearing from 6 months up to 3 years. Of those patients with less than 3 months between onset of symptoms and osteotomy, 6/13 developed segmental

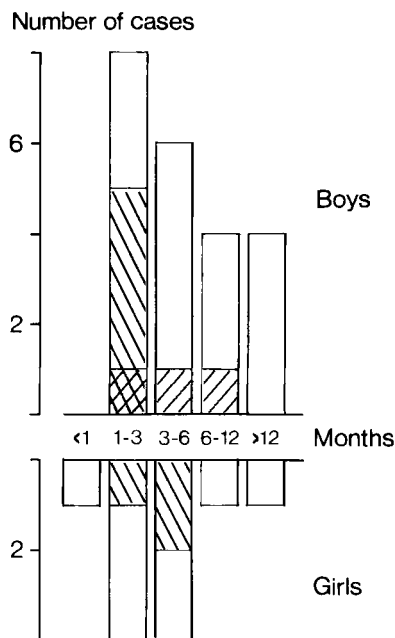


Figure 25. Number of patients in relation to sex and time between slipping and femoral neck osteotomy. ▩ = patients with segmental collapse; ▨ = patients with chondrolysis; □ = no complication.

collapse or chondrolysis, whereas of those with a history exceeding 3 months, 4/20 had these complications (Figure 25).

A postoperative wound infection was noticed in 3 cases. In 1 antibiotic treatment was sufficient for healing, whereas in the other 2 cases, operative drainage was needed. One male fell with his crutches during the period of nonweight-bearing and sustained a supracondylar femoral fracture on the operated on side. One male fell from his bicycle 8 months after osteotomy and sustained a breakage of the screw and a displacement of the osteotomy. He was operated on with extraction of the screw, reduction, and internal fixation with a bone peg.

*Follow-up.* Of the primary sample of 33 patients, 32 were reviewed by questionnaire, 28 by radiographic examination, and 26 by clinical examination (Table 23).

Table 23. Number of patients operated on by femoral neck osteotomy.

Primary material	33
Dead at follow-up	1
Questionnaire	32
Clinically reexamined	26
Radiographically reexamined	28

Table 24. Function 28 (16–32) years after femoral neck osteotomy. Cases with segmental collapse/chondrolysis in brackets.

Grade	1	2	3	4	5	6	Total
Pain	4(2)	6(4)	4(1)	4(2)	1	13(1)	32
Motion	2(2)	2(2)	7(3)	9(1)	6		26
Walking		1(1)	3(3)	5(3)	11(3)	12	32

One male and 1 female, both with segmental collapse, were operated on with total hip replacement because of severe arthrosis 22 and 23 years after the osteotomy. Another male with severe arthrosis was operated on with resurfacing hip arthroplasty 27 years after the osteotomy. One male, with chondrolysis, developed a shortening of 5 cm on the osteotomized side according to the clinical report. He was operated on with shortening osteotomy on the contralateral femur 5 years after the first operation. Twenty-three years after the femoral neck osteotomy, he was operated on again in the same hip because of arthrosis, now with McMurray osteotomy. In these 4 cases, radiographs and hip function before secondary operation were used for evaluation.

Nineteen patients had pain from their osteotomized hip and no one had a normal range of motion (Table 24). However, 23 patients could walk long distances without walking aids. The osteotomized leg was on an average 1.9 cm shorter (range 0–6 cm) than the contralateral leg.

Eighteen of the 28 osteotomized hips had arthrosis (Table 25). All nine hips with segmental collapse/chondrolysis had severe arthrosis. Of the contralateral hips, 11 evidenced slipping and one had mild arthrosis. Only three of these contralateral slippings were diagnosed during adolescence.

The articulothrochanteric distance was almost the same as in those hips with severe slipping left without treatment, and did not differ from other methods of treatment (Table 22).

*Comments.* During adolescence the bony epiphysis of the proximal femur receives its main blood supply from arteries in the capsula reflexa (80, 81). It is obvious that subperiosteal dissection, traction, or excessive rotation of the epiphysis during surgery

Table 25. Slipping and arthrosis 28 (16–32) years after femoral neck osteotomy. In brackets, cases with segmental collapse or chondrolysis.

		Slipping				Arthrosis			
		0	1	2	3	0	1	2	3
Osteotomized hip	Males				18(7)	7	3		8(7)
	Females				10(2)	3	3	1	3(2)
Contralateral hip	Males	10	4	1	3	17	1		
	Females	7	2	1		10			

is hazardous to these vessels. All the operations in our material have, however, been performed by experienced surgeons, with a technique designed to spare the vascular supply.

Segmental collapse or chondrolysis occurred in 10 of 33 hips. This frequency accords with most earlier reports concerning treatment of PCF with femoral neck osteotomy (4, 18, 22). Identification of segmental collapse and chondrolysis were based on our own examination of postoperative radiographs or, when these were not available, of the original report of the radiologist. Only cases with a joint space reduction to less than one half of that of the contralateral hip were classified as chondrolysis. Thus, the presented results should be regarded as minimum values.

There were more cases with segmental collapse among those with short delay between onset of symptoms and slipping (Figure 25). Dunn (18) presented less satisfactory results in cases with an acute on chronic slipping compared with chronic slipping. These differences may be explained by a better vascular adaptation in cases with a chronic and slow slipping. In acute slippings, there is probably also an instability in the physis during osteotomy, increasing the risk of peroperative damage of the retinacular vessels. Most slipped epiphyses have a normal vitality preoperatively (40), and segmental collapse should in most cases be regarded as a complication of the treatment and not of the slipping.

Chondrolysis was first described in 1930 by Waldenström (26). He realized that the joint cartilage receives its nourishment from the synovial fluid and that chondrolysis must result from some impairment of this nutrition. Cruess (82) found at histologic examinations, besides destruction of the joint cartilage, an almost complete destruction of the synovial lining, and supported the theory of Waldenström. Because the hip joint is a ball-and-socket joint, the pumping function during motion is important for the nutrition of the cartilage, and Cruess supposed that chondrolysis resulted from decreased production of synovial fluid in combination with surgical trauma and postoperative immobilization. Based on histologic and immunologic studies, Mankin et al. (83) and Ingram et al. (84) believed that chondrolysis is an immunologic response to cartilage antigens.

The ATD was almost the same as in the untreated hips with severe slipping (Table 22). Because the deformity was surgically corrected in the osteotomized hips, this operation probably resulted in a varying growth disturbance due to the physiodesis after screw fixation or to avascular necrosis.

In summary, one third of the hips with PCF treated by wedge osteotomy of the femoral neck were complicated by segmental collapse or chondrolysis, and severe arthrosis developed early in these hips. The remaining two thirds, in general, had no or only mild arthrosis and satisfactory function 30 years after the osteotomy.

### **Hook-pinning**

Fifty-six slipped and 43 unslipped hook-pinned hips were reviewed. One slipped hip showed chondrolysis before pinning. The pain ceased after pinning, but the restricted motion persisted.

Two boys developed a radiolucent zone 2–8 mm wide around the pin and elevated

ESR. Both were treated with antibiotics, 1 was reoperated on with extirpation of a bursa. Bacterial examination proved negative. In both hips there was a normal growth of the femoral neck; and after growthplate closure and pin extraction, there has been no signs of infection.

At the radiographic reexamination, one hip with an acute moderate slipping showed a minor segmental collapse. No chondrolysis was seen, besides the girl with chondrolysis diagnosed before pinning. All hook-pins had adequate anchorage in the epiphysis during the whole growth period.

The articulothrochanteric distance was on average 19 mm in the slipped hips and 23 mm in the prophylactic pinned hips (46), which is similar to values found in normal materials (46).

The pin was chosen so it protruded 10–15 mm laterally, permitting retraction with growth of the femoral neck. A few patients had minor discomfort with crepitations between the fascia lata and the pin, disappearing with retraction of the pin. In 49 slipped and all 43 unslipped hips, a longitudinal growth of 5–15 mm was recorded during the postoperative growth period (Figure 26).

In 49 hips the hook-pin has been extracted after growthplate closure. In 6 hips, where the base of the pin was retracted to the level of lateral cortex, a fenestration of the cortex had to be performed before extraction. One of these sustained a fracture at the level of fenestration 3 months after operation. The fracture healed after internal fixation, using a plate threaded on the hook-pin. In most cases, however, the pin could easily be extracted.

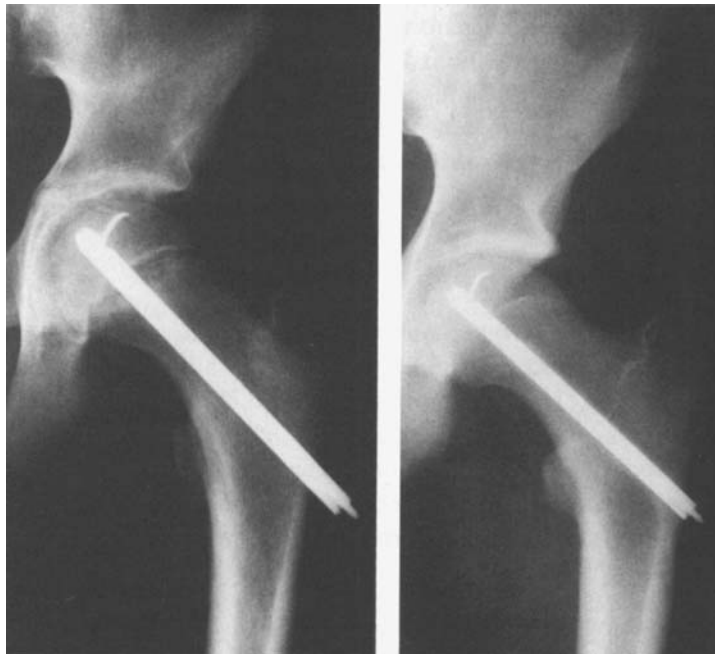

Figure 26. A boy with left-sided physiolyis at 15 years of age treated by hook-pinning. The same boy at 18 years of age, showing attained size of the femoral neck, with the pin retracted in its channel.

*Comments.* The new device eliminated the early complications found after Johansson nailing and Nyström pinning; physeal separation, lost epiphyseal grip and growth disturbances.

By gently pushing the pin through a predrilled channel no physeal separation has occurred. The hook prevents lost epiphyseal grip, because the pin cannot slide back in the channel and the femoral neck retracts the pin with growth.

Continued growth of the femoral neck was registered in most slipped hips and in all prophylactically pinned unslipped hips. In unilateral slipping at an early age, a growth arrest of the femoral neck can result in leg length discrepancy and reduced abduction because of continued growth of the greater trochanter (16). The average articulo-trochanteric distance after AO-screw fixation of mild or moderate slippings is 8–9 mm less than after hook-pinning (46).

In some hips, pin extraction was difficult due to pin retraction to the level of the lateral cortex. In children with PCF at an early age, we nowadays, when the pin has been retracted to nearly cortical level, reoperate with change to a longer pin if there is a considerable growth potential. Pin extraction and the insertion of the longer pin in the same channel has in these cases been technically easy without complications.

In conclusion, the hook-pin seems to eliminate the disadvantages found with the Johansson nail, the Nyström pin, and the AO-screw.

# Discussion and conclusions

## Epidemiology and etiology

The epidemiologic and etiologic studies suggest that PCF has a multifactorial etiology. These studies can be summarized under mechanical, hormonal, and familial predisposing factors.

### **Mechanical**

Only occasionally was the PCF due to a heavy trauma; trauma is of minor importance in most cases. Children with PCF are overweight \*\*\* at time of slipping and remain overweight until maturity, resulting in a higher than average load on the growth plate. The growth plate is weaker during periods of rapid growth (8). The slipping occurs mostly during the period of increasing height gain at puberty. The seasonal variation in incidence and the boy followed with roentgen stereophotogrammetric examinations before, during, and after PCF suggests a temporarily increased growth rate before and at time of onset of slipping.

### **Hormonal**

Animal experiments have shown that an imbalance between sex hormones and growth hormone (GH) weakens the growth plate (7, 8). In case reports, PCF has been associated with GH therapy (85, 86), hypothyroidism (9, 11), and hypogonadism (10, 64). The sex difference in incidence, the occurrence at puberty, and the decreasing age at onset parallel to the decreasing age at pubertal development indicate a connection with sexual hormones. The abnormal body constitution and the abnormal longitudinal growth during puberty further suggest a disturbed hormonal regulation of growth as an etiologic factor of PCF.

### **Familial**

Radiographic examination revealed PCF in about 10 per cent of the first-degree relatives; one third of the families had more than 1 member with PCF. In 3/164

first-degree relatives, PCF was diagnosed during adolescence, which is higher \*\*\* than expected from the incidence investigation.

However, there are still some findings that are not explained by these etiologic factors. The rural/urban differences in incidence and the periodic incidence pattern remain obscure. Perhaps nutritional or other environmental factors with the same periodicity and geographic difference affect those who are at risk of contracting PCF. However, to date no evidence has been presented.

## Therapy

No segmental collapse or chondrolysis was reported in the nontreated material. At follow-up, 36/57 slipped hips showed arthrosis; 14 of these were graded severe. Of the 112 slipped hips treated by closed reduction and hip spica, 19 developed segmental collapse or chondrolysis; and the frequency of arthrosis was higher than in the nontreated group. The inferior results could be due due to damage of the vascular supply to the epiphysis during the reduction maneuver and/or deficient cartilage nutrition during the immobilization period in hip spica.

The high risk (1/3) of osteonecrosis or chondrolysis after femoral neck osteotomy gives an overall poor long-term result. In fact, the frequency of arthrosis at follow-up was similar to frequencies of arthrosis with severe slipping left without primary treatment, though the latter were reexamined on an average 9 years later (Table 26). In intertrochanteric or subtrochanteric osteotomy, the risk of segmental collapse seems to be reduced (87), whereas the risk of chondrolysis seems to be increased (88).

The long-term results after nailing/pinning without reduction was superior to osteotomy or nonoperative treatment regardless of degree of slipping. Those nailed/pinned with reduction before 1950 have a poor function and a high frequency of severe arthrosis. Jerre (6) warned of reduction of chronic slippings. Maybe, those treated with reduction during the 1950s and 1960s had mostly an acute or acute-on-chronic slipping, which would account for the better results in these patients. However, there were no patients with mild or moderate slipping treated with in situ nailing/pinning with severe

Table 26. Arthrosis at follow-up related to method of treatment in hips with severe slipping.

Method	Arthrosis				Total no of hips
	0	1	2	3	
No treatment	7	10	6	13	36
Closed reduction, hip spica	7	5	2	41	55
Johansson nailing in situ	28	13	0	3	44
Johansson nailing, reduction	0	1	0	7	8
Nyström pinning in situ	17	9	0	2	28
Nyström pinning, reduction	3	0	0	0	3
Femoral neck osteotomy	10	6	1	11	28

arthrosis at follow-up. Consequently, in agreement with Boyer et al (95), there is no reason to actively reduce mild or moderate slippings. The high frequency of lost epiphyseal grip due to sliding or growth, with the risk of reslipping, is avoided using the hook-pin with reliable anchorage in the epiphysis.

Some authors (16, 23, 89) prefer bone pegging through the growth plate of the femoral neck to secure physiodesis. This method has shown good short-term results, similar to nailing/pinning. However, the operative procedure is more complicated and the patients are not allowed full weight-bearing postoperatively. The physiodesis may result in leg-length discrepancy and limited range of abduction owing to continuous growth of the trochanter major (16), which is important in cases with early and unilateral slipping. The use of screws to obtain growthplate closure results in the same problems with leg-length discrepancy and reduced abduction besides the problems at insertion and extraction (90, 91), which can be avoided by using the hook-pin (15, 16).

Bilateral PCF has been diagnosed in 20–25 per cent of this patient group during adolescence in most investigations (4, 63, 64), as in our material (24 per cent). Using more careful radiographic analysis, Klein et al. (92) reported 41 per cent, Jerre (6) 42 per cent, and Billing and Severin (93) 80 per cent bilateral slipping. At radiographic follow-up, using the relation between the femoral head and calcar femorale, bilateral slipping was seen in 62 per cent in our material. The high frequency of bilateral slipping and the corresponding increased risk of contracting arthrosis have changed our policy. All cases with PCF are today treated by prophylactic pinning of the contralateral hip, even if this side is asymptomatic and radiographically normal (15).

In conclusion, the long-term results after PCF mainly depend on the severity of slipping and the method of treatment.

### **Recommendations of treatment**

Based on our short- and long-term results and on our review of the literature, we recommend the following treatment of physiolysis of the hip.

#### *Mild and moderate slipping – acute and chronic type*

Pinning without reduction, using a gentle technique and a device with such anchorage in the epiphysis that lost grip due to sliding of pin or growth of the femoral neck is prevented, e.g., the hook-pin. Prophylactic pinning of the contralateral hip. Full weight-bearing is allowed from the first day postoperatively. Follow-up with radiography 3 months postoperatively. Extraction of the pins after completion of growth.

#### *Severe slipping – acute type*

Preoperative pin traction with abduction, flexion, and internal rotation according to Casey et al. (94). After a few days in traction, partial or complete reduction is achieved in most cases. The patient is operated on under general anesthesia with bilateral pinning without further active reduction. In some cases further reduction occurs spontaneously during muscle relaxation during the general anesthesia. Full weight-bearing is allowed

on the prophylactically pinned hip, partial weight-bearing during the first 4–8 weeks on the reduced hip. Follow-up as mild and moderate slippings.

*Severe slipping – chronic type*

Pinning without reduction if technically possible. Prophylactic pinning of the contralateral hip. Follow-up as mild and moderate slippings. In those very few cases where pinning is impossible, extracapsular wedge osteotomy at the base of the femoral neck (21, 22) or at the trochanteric level (23, 24) is probably least dangerous to the femoral head.

# Summary

This work is based on 532 cases of physiolysis colli femoris (PCF) in southern Sweden from 1910 through 1982. The material was analyzed epidemiologically. Subsets were used for different investigations aimed at surveying the etiology of PCF, and long-term follow-ups were conducted after various methods of treatment. Finally, the short-term results after hook-pinning, a new device, were evaluated.

After radiographic examination of anatomic specimens and normal hips, a method to diagnose and grade PCF was developed. The *calcar femorale* was found to be of constant shape and position and was used as a landmark to which the position of the femoral head was related. The advantage of this method is that it is easy to use and it is able to determine PCF also after growthplate closure.

Epidemiologic analysis of the total material revealed large changes during the 20th century. The disease is more common in males than in females, but the male predominance has decreased from about 90 per cent to about 60 per cent during the period of investigation. Mean age at onset of slipping has decreased by about 3 years in males to 12.7 years and by about 1 year in females to 11.8 years. The incidence has followed a periodic pattern with peaks approximately every 20th year. The mean incidence was 6/10,000 in boys and 3/10,000 in girls. Boys living in the country have always been at higher risk than those living in cities. They were also at higher risk of sustaining bilateral slipping. In girls, there is a seasonal variation, with a higher incidence between May and August.

The etiologic investigations dealt with hereditary, mechanical, and hormonal aspects. Radiographic examination revealed PCF in about 10 per cent of the first-degree relatives of 50 consecutive patients with PCF. One third of the families had 2 or more members with PCF. This familial accumulation is much higher than shown in earlier investigations based on questionnaires or clinical reports, and higher \*\*\* than expected from the incidence calculations.

The growth analysis using the ICP model showed in both sexes an above average body height before puberty. However, at maturity the heights were almost normal, and accordingly the pubertal gain in height was lower than normal. Both the boys and the girls were markedly overweight before puberty and remained so at maturity. The ICP model accords with what is known about hormonal regulation of growth, and the growth abnormalities indicate a disturbed hormonal growth regulation. Most patients had their onset of symptoms during the period of increasing growth at puberty.

Roentgen stereophotogrammetric analysis of longitudinal growth in the distal fibula showed in both sexes an almost normal rate during the years after pinning of the PCF. However, at diagnosis 13 children (17 when adjusted for skeletal age) of the 32 investigated had a body height exceeding the mean value by more than 1 SD, indicating higher than average growth before diagnosis. This is supported by the result from a boy with growth measurements also before slipping, showing a temporarily marked increased growth rate at time of onset of symptoms probably resulting in a weaker growth plate.

In the investigations concerning therapy, 57 cases left without primary treatment, 101 cases treated with closed reduction and hip spica, 33 cases operated on by femoral neck osteotomy, and 172 cases operated on by Johansson nailing or Nyström pinning were evaluated on an average 34 (16–66) years after primary diagnosis.

Of the nontreated cases, no segmental collapse or chondrolysis was seen. At follow-up 12/53 slipped hips had severe arthrosis; only 1 man was operated on with hip replacement. Most patients had a good hip function with at least tolerable pain and good walking capacity.

Of the children treated by closed reduction and hip spica, 19/112 slipped hips developed segmental collapse or chondrolysis. At follow-up, 45/71 hips showed severe arthrosis. Both the result regarding function and arthrosis was inferior when compared with the nontreated patients, indicating impairment of the epiphysis during reduction and/or during the immobilization in hip spica.

Of the osteotomized patients, 10 out of 33 sustained segmental collapse and/or chondrolysis. These patients developed severe arthrosis at an early age and had poor function at follow-up. The remaining two thirds had satisfactory function and, in general, no or only mild arthrosis.

Of the nailed/pinned cases, four of 25 hips treated with reduction and four of 179 hips operated on without reduction developed segmental collapse. This complication was associated with poor long-term results. There was a high frequency of lost epiphyseal grip due to sliding of the nail/pin or growth in length of the femoral neck resulting in many reoperations. No increase in arthrosis was found associated with this complication. Arthrosis was twice as frequent at follow-up after reduction (1/2) than after fixation in situ (1/4). Regarding severe arthrosis only, the ratio was 13 to 1. No severe arthrosis was seen after mild or moderate PCF that was nailed or pinned without reduction. The clinical and radiographic results were better than those from the same region after femoral neck osteotomy or nonoperative treatment. It is concluded that pinning in situ is the method of choice regardless of degree of slipping. Bilateral slipping was found in 62 per cent of the patients at follow-up, indicating prophylactic pinning of the contralateral hip in cases with unilateral slipping.

A new device, the hook-pin (33), was developed to eliminate the early complications (physeal separation, lost epiphyseal grip, and growth disturbances) found after Johansson nailing or Nyström pinning. Fifty-one children (56 slipped and 43 unslipped hips) treated with the hook-pin were evaluated after growthplate closure. No physeal separation or lost epiphyseal grip were recorded. In most hips a continuous growth in length of the femoral neck of 5–15 mm occurred during the postoperative growth period. In conclusion, the hook-pin seems to eliminate the disadvantages found with nails, pins and screws, and has been found useful in prophylactic pinning.

# Acknowledgements

We wish to express our gratitude to Johan Karlberg for collaboration with the ICP growth model, Staffan Sandström for the assessment of radiographs, Göran Selvik for the roentgen stereophotogrammetric analyses, Mona Olsson for illustrations, Göran Eliasson for the photography, Curt G. Carlbom for the language revision, and Kristina Persson, Gerda Seidel, and Birgitta Särgava for technical assistance.

This work was sponsored financially by The Swedish Medical Research Council (project 17X-02031), Greta and Johan Kochs Stiftelser, Alfred Österlunds Stiftelse, and Stiftelsen för Bistånd åt Vanföra i Skåne.

# References

1. Paré A. Fractures of the neck of the femur. In: Cinq livres de chirurgie, Paris 1572, cited in Oeuvres complètes, Book 13, Chap. 21, Paris 1840;2.
2. Kelsey J L, Keggi K J, Southwick W O. The incidence and distribution of slipped capital femoral epiphysis in Connecticut and Southwestern United States. *J Bone Joint Surg (Am)* 1970;52(6):1203–16.
3. Ninomiya S, Nagasaka Y, Tagawa H. Slipped capital femoral epiphysis. A study of 68 cases in the eastern half area of Japan. *Clin Orthop* 1976;(119):172–6.
4. Wilson P D, Jacobs B, Schechter L. Slipped capital femoral epiphysis. An end result study. *J Bone Joint Surg (Am)* 1965;47:1128–45.
5. Rennie A M. The inheritance of slipped upper femoral epiphysis. *J Bone Joint Surg (Br)* 1982;64(2):180–4.
6. Jerre T. A study in slipped capital femoral epiphysis. *Acta Orthop Scand* 1950;(Suppl 6).
7. Harris W R. The endocrine basis for slipping of the upper femoral epiphysis. An experimental study. *J Bone Joint Surg (Br)* 1950;32:5–11.
8. Morscher E. Strength and morphology of growth cartilage under hormonal influence of puberty. Animal experiments and clinical study on the etiology of local growth disorders during puberty. *Reconstr Surg Traumatol* 1968;10:3–104.
9. Heyerman W, Weiner D. Slipped epiphysis associated with hypothyroidism. *J Pediatr Orthop* 1984;4(5):569–73.
10. Primiano G A, Hughston J C. Slipped capital femoral epiphysis in a true hypogonadal male (Klinefelter's mosaic XY-XXY). A case report. *J Bone Joint Surg (Am)* 1971;53(3):597–601.
11. Puri R, Smith C S, Malhotra D, Williams A J, Owen R, Harris F. Slipped upper femoral epiphysis and primary juvenile hypothyroidism. *J Bone Joint Surg (Br)* 1985;67(1):14–20.
12. Bianco A J. Treatment of mild slipping of the capital femoral epiphysis. *J Bone Joint Surg (Am)* 1965;47:387–96.
13. Kelsey J L, Acheson R M, Keggi K J. The body build of patients with slipped capital femoral epiphysis. *Am J Dis Child* 1972;124(2):276–81.
14. Wiberg G. Considerations on the surgical treatment of slipped capital femoral epiphysis with special reference to nail fixation. *J Bone Joint Surg (Am)* 1959;41:253–61.

15. Hansson L I. Osteosynthesis with the hook pin in slipped capital femoral epiphysis. *Acta Orthop Scand* 1982;53(1):87-96.
16. Howorth B. The bone pegging operation for slipping of the capital femoral epiphysis. *Clin Orthop* 1966;48:79-87.
17. Klein A, Joplin R J, Reidy J A. Treatment of slipped capital femoral epiphysis. *JAMA* 1948;136:445-51.
18. Dunn D M. Severe slipped capital femoral epiphysis and open replacement by cervical osteotomy. In: *The Hip. Proceedings of the Third Open Scientific Meeting of the Hip Society*, C.V Mosby, St Louis 1975:115-26.
19. Nelson C L. An approach to salvage procedures for poor results in slipped capital femoral epiphysis. In: *American Academy of Orthop Surg* 1980;29:78-81.
20. Fish J B. Cuneiform osteotomy of the femoral neck in the treatment of slipped capital femoral epiphysis. *J Bone Joint Surg (Am)* 1984;66(8):1153-68.
21. Kramer W G, Craig W A, Noel S. Compensating osteotomy at the base of the femoral neck for slipped capital femoral epiphysis. *J Bone Joint Surg (Am)* 1976;58(6):796-800.
22. Gage J R, Sundberg A B, Nolan D R, Sletten R G, Winter R B. Complications after cuneiform osteotomy for moderately or severely slipped capital femoral epiphysis. *J Bone Joint Surg (Am)* 1978;60(2):157-65.
23. DePalma A F, Danyo J J, Stose W G. Slipping of the upper femoral epiphysis. *Clin Orthop* 1964;37:167-83.
24. Southwick W O. Osteotomy through the lesser trochanter for slipped capital femoral epiphysis. *J Bone Joint Surg (Am)* 1967;49(5):807-35.
25. Axhauser G. Die Nekrose des proximalen Bruchstücks beim Schenkelhalsbruch und ihre Bedeutung für das Hüftgelenk. *Arch Klin Chir* 1922;120:325-46.
26. Waldenström H. On necrosis of the joint cartilage by epiphyseolysis capitis femoris. *Acta Chir Scand* 1930;67:936-46.
27. Billing L. Roentgen examination of the proximal femur end in children and adolescents. *Acta Radiol* 1954;(Suppl 110).
28. Bianco A J Jr. Treatment of slipping of the capital femoral epiphysis. *Clin Orthop* 1966;48:103-10.
29. Griffith M J. Slipping of the capital femoral epiphysis. *Ann R Coll Surg Engl* 1976;58(1):34-42.
30. Engelhardt P. *Juvenile Hüftkopflösung und Koxarthrose*. Ferdinand Enke, Stuttgart 1984.
31. Frising G. *Epiphyseolysis capitis femoris i förhållande till coxa vara*. Berlingska, Lund 1926.
32. Wiberg G. Surgical treatment of slipped epiphysis with special reference to wedge osteotomy of the femoral neck. *Clin Orthop* 1966;48:139-52.
33. Hansson L I. Sliding nail in treatment of slipped capital femoral epiphysis. *IRCS Med Sci Biomed Technol* 1975;3:567-8.
34. Hansson L I, Hägglund G, Ordeberg G, Sandström S. The calcar femorale as a landmark in hip physiolsis. *Acta Orthop Scand* 1988. In press.
35. Hägglund G, Hansson L I, Ordeberg G. Epidemiology of slipped capital femoral epiphysis in southern Sweden. *Clin Orthop* 1984;(191):82-94.

36. Hägglund G, Hansson L I, Ordeberg G, Sandström S. Slipped capital femoral epiphysis in southern Sweden. Long term results after femoral neck osteotomy. *Clin Orthop* 1986;(210):152-9.
37. Hägglund G, Hansson L I, Sandström S. Familial slipped capital femoral epiphysis. *Acta Orthop Scand* 1986;57(6):510-2.
38. Hägglund G, Hansson L I, Sandström S. Slipped capital femoral epiphysis in southern Sweden – long term results after nailing/pinning. *Clin Orthop* 1987;(217):190-200.
39. Hägglund G, Hansson L I. Slipped capital femoral epiphysis in three generations. *Acta Orthop Scand* 1986;57(3):240-2.
40. Hägglund G, Hansson L I, Ordeberg G. Vitality of the slipped capital femoral epiphysis. Preoperative evaluation by tetracycline labeling. *Acta Orthop Scand* 1985;56:215-7.
41. Hägglund G, Hansson L I, Hansson V, Karlberg J. Growth of children with physiolysis of the hip. *Acta Orthop Scand* 1987;58:117-20.
42. Hägglund G, Bylander B, Hansson L I, Kärrholm J, Selvik G, Svensson K. Longitudinal growth of the distal fibula in children with slipped capital femoral epiphysis. *J Pediatr Orthop* 1986;6:274-7.
43. Ordeberg G, Hansson L I, Sandström S. Slipped capital femoral epiphysis in southern Sweden. Long term result with no treatment or symptomatic primary treatment. *Clin Orthop* 1984;(191):95-104.
44. Ordeberg G. Physiolysis of the hip. Epidemiology, natural history and long term results after closed treatment. Thesis, University of Lund, Lund, Sweden 1986.
45. Ordeberg G, Hansson L I, Sandström S. Slipped capital femoral epiphysis in southern Sweden. Long term result with closed reduction and hip plaster spica. *Clin Orthop* 1987;(220):148-54.
46. Ordeberg G, Hägglund G, Hansson L I, Sandström S. Articulotrochanteric distance in slipped capital femoral epiphysis. 1986. Submitted for publication.
47. Karlberg J. A biologically oriented mathematical model(ICP) for human growth. In: Key issues in child growth: Some new developments (Eds. Fryer, J.G. and Lawrence C.J.) Quintiles Inc., Chapel Hill 1986. In press.
48. Harty M. The calcar femorale and the femoral neck. *J Bone Joint Surg (Am)* 1957;39:625-30.
49. Karlberg J, Fryer J G, Engström I, Karlberg P. Analysis of linear growth using a mathematical model II from-3 to-21 years of age. *Acta Paediatr Scand* 1987;(Suppl 337):12-29.
50. Selvik G. A roentgen stereophotogrammetric method for the study of the kinematics of the skeletal system. Thesis, University of Lund, Lund, Sweden 1974.
51. Kärrholm J, Hansson L I, Selvik G. Roentgen stereophotogrammetric analysis of growth pattern after supination eversion ankle injuries in children. *J Pediatr Orthop* 1982;2(1):25-37.
52. Greulich W W, Pyle S I. Radiographic atlas of skeletal development of the hand and the wrist. Stanford University Press, Stanford 1959.
53. Kärrholm J, Hansson L I, Selvik G. Longitudinal growth rate of the distal tibia and fibula in children. *Clin Orthop* 1984;(191):121-8.

54. Karlberg P, Taranger J. The somatic development of children in a swedish urban community. *Acta Paediatr Scand* 1976;(Suppl 258):1-148.
55. Charnley J. Low friction arthroplasty of the hip. Theory and practice. Springer Verlag, Berlin 1979.
56. d'Aubigné M R, Postel M. Functional results of hip arthroplasty with acrylic prosthesis. *J Bone Joint Surg (Am)* 1954;36:451-75.
57. Ahlbäck S. Osteoarthritis of the knee. A radiographic investigation. *Acta Radiol (Diagn) (Stockh)* 1968;(Suppl 277):7-72.
58. Edgren W. Coxa plana. A clinical and radiological investigation with particular reference to the importance of the metaphyseal changes for the final shape of the proximal part of the femur. *Acta Orthop Scand* 1965;(Suppl 84):1-129.
59. Griffin J B. The calcar femorale redefined. *Clin Orthop* 1982;(164):211-4.
60. Henrikson B. The incidence of slipped capital femoral epiphysis. *Acta Orthop Scand* 1969;40(3):365-72.
61. Deming J. Application of the Gompertz curve to the observed pattern of growth in length of 48 individual boys and girls during the adolescent cycle of growth. *Hum Biol* 1957;29:83-122.
62. Oram V. Epifysiolysis capitis femoris. Thesis, University of Aarhus, Aarhus, Denmark 1952.
63. Burrows H J. Slipped upper femoral epiphysis. Characteristics of a hundred cases. *J Bone Joint Surg (Br)* 1957;39:641-58.
64. Sörensen K H. Slipped upper femoral epiphysis. Clinical study on aetiology. *Acta Orthop Scand* 1968;39(4):499-517.
65. Marsk A. Studies on weight distribution upon the lower extremities in individuals working in a standing position. *Acta Orthop Scand* 1958;(Suppl 31).
66. Hult L. Cervical, dorsal and lumbar spinal syndromes. *Acta Orthop Scand* 1954;(Suppl 17).
67. Willner S. Factors contributing to structural scoliosis. Thesis, University of Lund, Lund, Sweden 1972.
68. Johnsson B. Postural faults in school children. Thesis, University of Lund, Lund, Sweden 1983.
69. Tanner J M. Growth at adolescence. Blackwell, Oxford 1962.
70. Kärrholm J, Hansson L I, Laurin S, Selvik G. Post traumatic growth disturbance of the ankle treated by the Langenskiöld procedure. Evaluation by radiography, roentgen stereophotogrammetry, scintimetry and histology: case report. *Acta Orthop Scand* 1983;54(5):721-9.
71. Waldenström H. Om epifysglidningen i höftleden. Iduns Tryckeri AB, Stockholm 1939.
72. Kelsey, J L, Keggi K J. An epidemiological study of the effect of fluorides in drinking water on the frequency of slipped capital femoral epiphysis. *Yale J Biol Med* 1971;44(3):274-85.
73. Ponseti I V, McClintock R. The pathology of slipping of the upper femoral epiphysis. *J Bone Joint Surg (Am)* 1956;38:71-83.

74. Andrén L, Borgström K E. Seasonal variation of epiphysiolysis of the hip and possibility of alimentary causal factor. *Acta Orthop Scand* 1958;28:22–36.
75. Selvik G, Alberius P, Aronson A S. A roentgen stereophotogrammetric system. Construction, calibration and technical accuracy. *Acta Radiol (Diagn) (Stockh)* 1983;24(4):343–52.
76. Wingstrand H. Transient synovitis of the hip in the child. *Acta Orthop Scand* 1986;(Suppl 219):1–61.
77. Walters R, Simon S R. Joint destruction: a sequel of unrecognized pin penetration in patients with slipped capital femoral epiphyses. In: *The Hip. Proceedings of the Eighth Open Scientific Meeting of The Hip Society, C.V. Mosby, St Louis* 1980:145–64.
78. Bennet G C, Koreska J, Rang M. Pin placement in slipped capital femoral epiphysis. *J Pediatr Orthop* 1984;4(5):574–8.
79. Lehman W B, Menche D, Grant A, Norman A, Pugh J. The problem of evaluating in situ pinning of slipped capital femoral epiphysis: an experimental model and a review of 63 consecutive cases. *J Pediatr Orthop* 1984;4(3):297–303.
80. Trueta J. The normal vascular anatomy of the human femoral head during growth. *J Bone Joint Surg (Br)* 1957;39:358–94.
81. Hulth A. The vessel anatomy of the upper femur end with special regard to the mechanism of origin of different vascular disorders. *Acta Orthop Scand* 1958;27:192–209.
82. Cruess R L. The pathology of acute necrosis of cartilage in slipping of the capital femoral epiphysis. *J Bone Joint Surg (Am)* 1963;45:1013–24.
83. Mankin H J, Sledge C B, Rothschild S, Einstein A. Chondrolysis of the hip. In: *The Hip. Proceedings of the Third Open Scientific Meeting of The Hip Society, C.V. Mosby Co, St Louis* 1975:127–35.
84. Ingram A J, Clarke M S, Clarke C S Jr, Marshall W R. Chondrolysis complicating slipped capital femoral epiphysis. *Clin Orthop* 1982;(165):99–109.
85. Fidler M W, Brook C G. Slipped upper femoral epiphysis following treatment with human growth hormone. *J Bone Joint Surg (Am)* 1974;56(8):1719–22.
86. Rennie W, Mitchell N. Slipped femoral capital epiphysis occurring during growth hormone therapy. Report of a case. *J Bone Joint Surg (Br)* 1974;56(4):703–5.
87. Southwick W O. Compression fixation after biplane intertrochanteric osteotomy for slipped capital femoral epiphysis. A technical improvement. *J Bone Joint Surg (Am)* 1973;55(6):1218–24.
88. Frymoyer J W. Chondrolysis of the hip following Southwick osteotomy for severe slipped capital femoral epiphysis. *Clin Orthop* 1974;(99):120–4.
89. Herndon C H, Heyman C H, Bell D M. Treatment of slipped capital femoral epiphysis by epiphyseodesis and osteoplasty of the femoral neck: A report of further experience. *J Bone Joint Surg (Am)* 1963;45:999–1012.
90. Cameron H U, Wang M, Koreska J. Internal fixation of slipped femoral capital epiphyses. *Clin Orthop* 1978;(137):148–53.
91. Friberg S, Larsson S, Dahlström H. Complications associated with extraction of the AO epiphysiodesis screw. *Acta Orthop Scand* 1984;55(6):684.

92. Klein A, Joplin R J, Reidy A J, Hanelin J. Management of the contralateral hip in slipped capital femoral epiphysis. *J Bone Joint Surg (Am)* 1953;35:81-7.
93. Billing L, Severin E. Slipping epiphysis of the hip: A roentgenological and clinical study based on a new roentgen technique. *Acta Radiol* 1959;(Suppl 174).
94. Casey B H, Hamilton H W, Bobechko W P. Reduction of acutely slipped upper femoral epiphysis. *J Bone Joint Surg (Br)* 1972;54(4):607-14.
95. Boyer D W, Mickelson M R, Ponseti I V. Slipped capital femoral epiphysis. Long-term follow-up study of one hundred and twenty-one patients. *J Bone Joint Surg (Am)* 1981;63(1):85-95.







