

## Accessory ossicles in the elbow

Accessory ossicles in the elbow are often diagnosed as osteochondritis dissecans or chondromatosis, but no terminologic agreements seem to exist in the literature. Our study of 5 patients suggests that accessory ossicles in the fossa olecrani or coronoidea may represent anatomic variants, perhaps best described as os supratrochleare anterius and posterius, respectively.

Correspondence: Dr. Gudmundsen, Department of Radiology, Buskerud Sentralsykehus, N-3000 Drammen, Norway

**Tor Erik Gudmundsen  
Harald Østensen**

Departments of Radiology,  
University Hospital of  
Tromsø, Tromsø, Norway

### Introduction

Confusion apparently exists in describing accessory ossicles in the elbow; terms like aseptic necrosis, osteochondritis dissecans, sesamoid bones, persistent epiphysis, or synovial chondromatosis have been used in the literature (Morgan 1953, Hilger 1954, Ellinghausen 1955, Schwarz 1957, Oschenschlaeger 1959, Schmidt 1959, Kohlmann & Neumann 1961, Canigiani et al. 1972, Crasselt & Willkommen 1974, Christensen & Poulsen 1975, Lais & Flesch 1984). Although accessory ossicles are relatively rare in the elbow region, their origin is important for both diagnostic and therapeutic purposes.

### Case reports

*Case 1.* Male, born in 1946. At the age of 16 years, he experienced a minor trauma to his right elbow causing pain and some deficit of extension. In the fossa olecrani an oval ossicle measuring 11 mm was observed radiographically (Figure 1); there was no fracture. Pain and

limitation of motion persisted for the next 3 years, finally leading to surgical removal of the ossicle with complete improvement and a radiographically normal elbow.

*Case 2.* Male, born in 1962. At the age of 18 years, he experienced increasing pain and limitation of motion in his left elbow and after some months in his right elbow as well. No trauma was known. Radiograms showed oval bony ossicles in both fossae olecrani, measuring 11 mm in the left and 14 mm in the right elbow. The left ossicle was removed and the patient improved completely. An operation was planned on his right elbow as well, but the patient moved to another part of the country and no further contact could be established.

*Case 3.* Male, born in 1945. At 13 years of age, he had slowly increasing pain and limitation of motion in his right elbow. One year later, similar symptoms occurred in his left elbow. Not until the symptoms had persisted for 7 years did he have radiographs of his elbows, initiated by a minor trauma to his right elbow. The examination showed a small bone-structured particle at the radial condyle of his right humerus, interpreted as an accessory ossicle caused by the trauma, even if no residual defect could be demonstrated in the articular

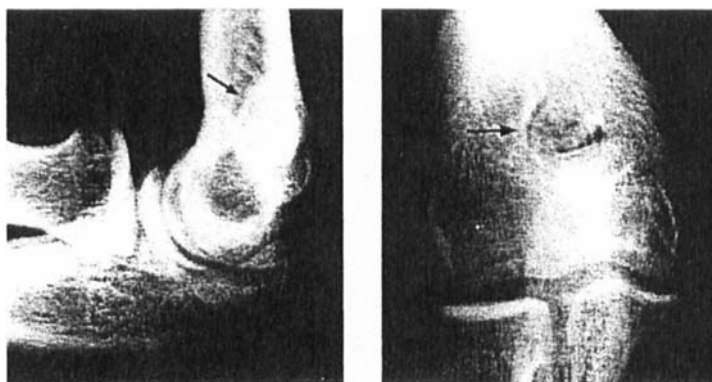


Figure 1. Case 1, right elbow. Arrow indicates ossicle in the fossa olecrani.

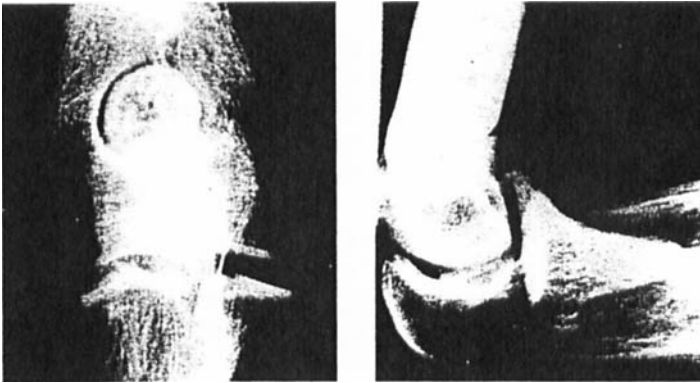


Figure 2. Case 3, left elbow. Ossicle in the fossa olecrani measuring 21 mm.

surface; there were three additional bony particles in the fossa coronoidea. In his left elbow, there was a bony structure measuring 21 mm in the fossa olecrani (Figure 2). Owing to increasing symptoms, the bony ossicle at the right humeral condyle was removed surgically. At the operation, no cartilaginous or bony defect could be found in the joint surfaces.

A repeat trauma some months later to his left elbow lead to further RE's and, in addition to the earlier demonstrated ossicle in the fossa olecrani, a loose calcified fragment was seen in the joint. No bony defects could, however, be demonstrated. Surgical treatment was planned, but for some reason, it was not performed, and the symptoms persisted or even increased during the following years.

*Case 4.* Male, born in 1959. At the age of 16 years, he suffered minor trauma to his right elbow. Radiographs of both elbows were normal. Twelve months later, he had slowly increasing pain and limitations of motion in his right elbow, and small oval ossicles were now seen in both the fossa olecrani and the fossa coronoidea. Because of increasing symptoms, both ossicles (Figure 3) were removed, and the patient improved completely; at operation there were no signs of synovitis or of any bony or cartilaginous defect.

*Case 5.* Male, born in 1917. For more than 20 years, he had complained of pain and disturbed motion in his right elbow. No trauma was known. Radiographs showed a large ossicle in the fossa coronoidea and two minor ossicles in the fossa olecrani; the large ossicle clearly had a bony structure; the radiographs did not reveal any other pathologic findings or bony defects.

### Discussion

Ossicles in the fossa coronoidea, in the fossa olecrani, and at the radial epicondyle of the humerus are located intraarticularly, whereas other ossicles are situated outside the joint (Figure 4). Ossicles at the radial or ulnar humeral condyle, most likely being persistent apophyses, hardly cause any clinical or diagnostic problems unless they fracture. In such cases, however, they may falsely be interpreted as osteochondritis dissecans. Intraarticular ossicles may cause pain and loss of motion. Fragmentation, notably due to trauma, may increase the symptoms and lead to the false radiographic diagnosis of osteochondritis. Furthermore, ossicles in the fossa olecrani

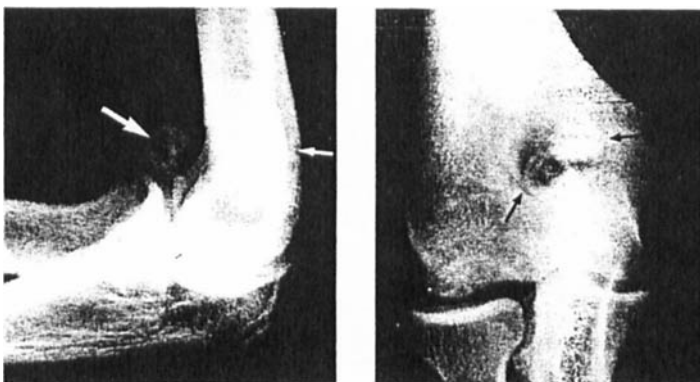


Figure 3. Case 4, right elbow. Ossicles in the fossa olecrani and fossa coronoidea.

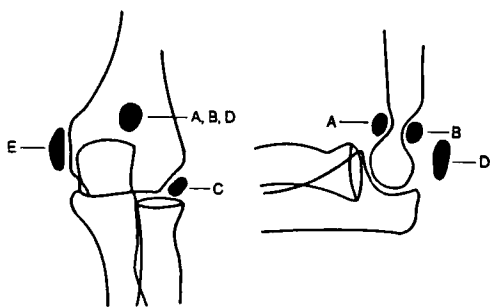


Figure 4. Sites of accessory ossicles in the elbow. A (os supratrochleare anterius), B (os supratrochleare posterius), and are located in the joint; D and E are not.

should be distinguished from sesamoid bones in the triceps tendon; both conditions may produce similar clinical symptoms, but extraarticular sesamoid bones are never associated with loose osteo-cartilaginous bodies within the joint.

Accessory ossicles in the fossa olecrani have been described as osteochondritis dissecans originating from a supratrochlear septum (Hillger 1954, Ellinghausen 1955, Schwarz 1957, Schmidt 1959, Kohlmann & Neumann 1961, Canigiani et al. 1972). Ochsenschlaeger (1959), describing 1 patient with two ossicles in his fossa coronoidea, postulated possible aseptic necrosis of a supratrochlear septum. Schwarz (1957), however, claimed that ossicles in the fossa coronoidea could be sesamoid bones, and he suggested the term *fabella cubiti*, a logical term for bones lying in the tendon of the biceps muscle, but not for intraar-

ticular ossicles. None of our patients showed any bone defect suggesting osteochondritis, and it seems rather unlikely that all such defects should have completely healed. Furthermore, real bony structure of the accessory ossicles could be demonstrated radiographically in 1 of our patients that contrasts with that seen in necrotic fragments. Histologic examinations of such ossicles have shown the presence of normal bone tissue as well (Schmidt 1959). Thus, we agree with Obermann & Loose (1983) and Canigiani et al. (1972) suggesting accessory ossicles in the elbow to be anatomic variants that ossify relatively late, probably after puberty, as shown in our fourth patient. Becoming larger, the ossicles may cause pain and limitation of motion, and due to trauma, they may fragment, thus simulating osteochondritis (Obermann & Loose 1983, Basset et al. 1981). The treatment should probably be removal of both ossicles and fragments.

We have no explanation of the fact that, as far as we know, only male patients have been reported. Occupational factors leading to trauma and radiographic examinations may be one explanation. Our fifth patient diagnosed at the age of 67 years may indicate the possibility of many undiagnosed accessory ossicles in the elbow, giving a spuriously low prevalence rate.

In conclusion, we propose the terms "os supratrochleare anterius" and "os supratrochleare posterius" to distinguish accessory ossicles from osteochondritis.

## References

- Bassett, L. W., Mirra, J. M., Forrester, D. M., Gold, R. H., Bernstein, M. L. & Rollins, J. S. (1981) Post-traumatic osteochondral "loose body" of the olecranon fossa. *Radiology* **141**, 635-638.
- Canigiani, G., Wickenhauser, J. & Czech, W. (1972) Beitrag zur Osteochondritis dissecans im Foramen supratrochleare. *Fortschr. Roentgenstr.* **117**, 66-68.
- Christensen, J. H. & Poulsen, J. O. (1975) Synovial chondromatosis. *Acta Orthop. Scand.* **46**, 919-925.
- Crasselt, C. & Willkommen, H. (1974) Die Therapie der Chondromatosis synovialis. *Beitr. Orthop.* **21**, 315-321.
- Ellinghausen, H. P. (1955) Eine seltene Lokalisation der Osteochondritis dissecans. *Fortschr. Roentgenstr.* **94** 277-278.
- Hillger, H. (1954) Eine seltene Lokalisation der Osteochondritis dissecans. *Fortschr. Roentgenstr.* **81**, 829-830.
- Kohlmann, E. & Neumann, G. (1961) Osteochondritis dissecans im Foramen supratrochleare beiderseits. *Fortschr. Roentgenstr.* **94**, 277-278.
- Lais, E. & Flesch, U. (1984) Die Diagnostik freier Körper in der Fossa olecrani des Ellenbogengelenkes. *Fortschr. Roentgenstr.* **141**, 713-715.
- Morgan, P. W. (1953) Osteochondritis dissecans of the supratrochlear septum. *Radiology* **60**, 241-243.
- Obermann, W. R. & Loose, H. W. (1983) The os supratrochleare dorsale: A normal variant that may cause symptoms. *A. J. R.* **141**, 123-127.
- Ochsenschlaeger, A. (1959) Zum Krankheitsbild der "aseptischen Knochennekrose" des Septum supratrochleare. *Z. Orthop.* **91**, 441-444.
- Schmidt, E. (1959) Beitrag zur Osteochondritis dissecans des Ellenbogengelenkes. *Zbl. Chir.* **84**, 256-259.
- Schwarz, G. S. (1957) Bilateral antecubital ossicles (*Fabella cubiti*) and other rare accessory bones of the elbow. *Radiology* **69**, 730-733.