



Reconstruction with a free vascularized fibular graft for malignant bone tumor

Magnus Åberg¹, Anders Rydholm², Jan Holmberg³ and Jan B Wieslander¹

Seven patients with a bone tumor were operated on with local excision and a free vascularized fibular graft. Four of the patients received both chemotherapy and radiotherapy. The blood flow in the grafts was evaluated by scintigraphy within 1 week after the operation. The median follow-up time was 4 (1-5) years.

All but one graft-host junction healed primarily. There were 5 graft fractures in 3 patients. Four of the fractures occurred in 2 patients who received preoperative and postoperative chemotherapy and radiotherapy. Three of these fractures healed without surgery. Resorption of the grafts was never seen, whereas hypertrophy was observed in 6 patients. None of the patients had any permanent morbidity at the donor site. One patient had tumor recurrence and died after 2 years.

Our findings indicate that a vascularized bone graft is also a useful alternative for reconstruction of large bone defects in patients receiving both chemotherapy and radiotherapy.

Reconstruction of skeletal defects can be made with autogenic or allogenic avascular bone grafts. In large defects the healing time is considerable and graft complications, i.e., fracture, nonunion, and infection, are not uncommon (Enneking et al. 1977, Mankin et al. 1982). Microvascular techniques have made reconstruction with vascularized bone possible (Östrup 1971, Weiland et al. 1977, Shaffer et al. 1985, Hieayama et al. 1985). We report the outcome in our first 7 cases of reconstruction with a free vascularized fibular graft after excision of bone tumors.

Patients and methods

Seven patients were treated in 1981-1986 (Table 1). All the tumors were diagnosed by open biopsy

or aspiration cytology (Case 7) after staging studies had been performed with conventional radiography, computed tomography, angiography, and scintigraphy. None of the patients had clinical or radiographic signs of metastases. Four of the patients also received varying combinations of preoperative and postoperative chemotherapy and radiotherapy.

Operative technique and aftercare

The tumor was removed with a wide margin in 6 patients and with a marginal margin in 1 (Case 5). Preparation of the fibular graft was started at the same time as the tumor surgery and performed according to Gilbert (1979) and Donski et al. (1982) in a bloodless field. A muscle cap was left around the fibula, and the peroneal vessels were prepared to the trifurcation. To minimize the ischemic time, the vessels were not divided until the tumor was excised and the recipient vessels isolated (except in Case 1). Usually one end-to-end or end-to-side arterial anastomosis and two end-to-end venous anastomoses were made. To protect the blood supply to the graft, we tried to place the vessel anastomoses outside areas treated

Lund University Departments of Plastic Surgery¹ and Hand Surgery³ Malmö General Hospital, and Department of Orthopedics², University Hospital, Lund, Sweden

Correspondence: Dr. Anders Rydholm, Department of Orthopedics, University Hospital, S-221 85 Lund

Table 1. Seven patients reconstructed with vascularized fibular grafts after excision of bone tumors

Case	Age	Sex	Diagnosis	Location	Bone defect (cm)	Adjuvant therapy		Callus (weeks)	Graft complications	Follow-up time (years)
						preop	postop			
1	20	M	Osteosarcoma	Prox. humerus	13	-	-	8	Pseudarthrosis bone junction, healed after operation. Unhealed graft fracture	5
2	13	F	Adamantinoma	Tibial shaft	14	-	-	6	None	4.5
3	13	F	Ewing sarcoma	Ulnar shaft	16	C, R	C	8	Slow healing of the proximal bone junction	4
4	44	F	Recurrent giant cell tumor	Distal femur	10	-	-	24	None	4
5	12	M	Ewing sarcoma	Femoral shaft	17	C	C, R	4	Fractured twice. Both healed, the latest after bone grafting.	3.5
6	13	M	Osteosarcoma	Prox. humerus	15	C	C	9	Fractured twice. Both healed after closed treatment	2 (dead)
7	14	F	Osteosarcoma	Humeral shaft	17	C	C	9	None	1

C chemotherapy, R radiotherapy.

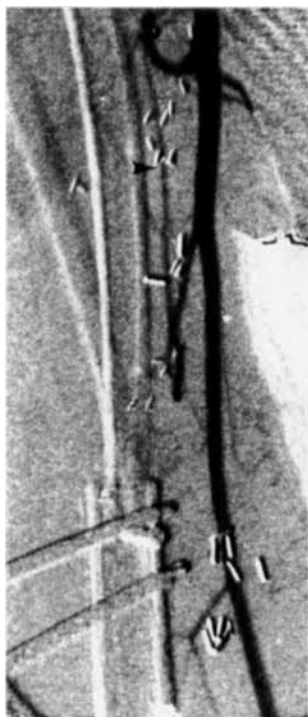

Figure 1. Case 6. Digital microangiography with intravenously administered contrast visualized the peroneal artery (arrow) running parallel to the graft. Lateral to the vascularized graft, a nonvascularized tibial graft can be seen.

with radiotherapy (Krag et al. 1982). All the patients were given prophylactic antibiotics.

Case 1 had an orthosis, Case 4 had internal fixation with a Küntscher nail, and 5 patients had external fixation. Various methods were used for fixation of the graft-host junction. If possible the graft was tucked into the remaining parts of the resected bone. In Cases 4, 6, and 7 the bone defect was also bridged by an avascular autologous bone graft. Except in Case 1, the fixation was applied before the excision of the tumor. This made the insertion of the graft and anastomosing of the vessels easier.

In all the cases, ^{99m}Tc-MDP scintigraphy was performed within 1 week of the operation (Figure 4). Case 6 was also examined with digital microangiography after intravenously injected contrast (Figure 1).

Results

The median ischemic time of the graft was 2.8 (2.5-4.5) hours, and the median operation time was 12 (10-14) hours. The postoperative course was uneventful in all the patients, and no infection occurred. Except for Case 1, all the patients

showed clear-cut isotope uptake in the graft. In Case 6 the angiography showed contrast filling of the fibular artery of the graft, indicating patent vessel anastomoses (Figure 1). Callus formation at the graft-host junction was seen after a median of 8 (4-24) weeks (Table 1).

The bone junctions healed primarily except in Case 1, where nonunion required additional surgery. This patient later had a graft fracture, which remains unhealed after 5 years, and is almost painless. Also Cases 5 and 6 suffered fractures of the grafts (Table 1); both had graft fractures on two different occasions and at different sites. These four graft fractures healed, one after surgery. None of the patients had any permanent morbidity at the donor site. Resorption of the graft was not seen, whereas the graft thickened in 6 patients. The tumor recurred in 1 patient (Case 6), who died 2 years after the first operation.

Case reports

1. A 20-year-old man with a low-grade malignant osteosarcoma had resection of the proximal 13 cm of the humerus. The graft, which in this case included the fibular head, was tucked into the distal part of the humerus; the fibular head was anchored to the glenoid cavity with a soft-tissue reconstruction. External fixation with an orthosis was used. Postoperative scintigraphy was inconclusive. At follow-up, there was no resorption of the graft, and there was radiographic evidence of callus formation at the graft-host junction. A pseudarthrosis developed however, which healed after plate fixation and grafting with autologous iliac bone performed 2 years after the first operation. Six months later, the patient fractured the graft when he fell on the arm; he developed a new

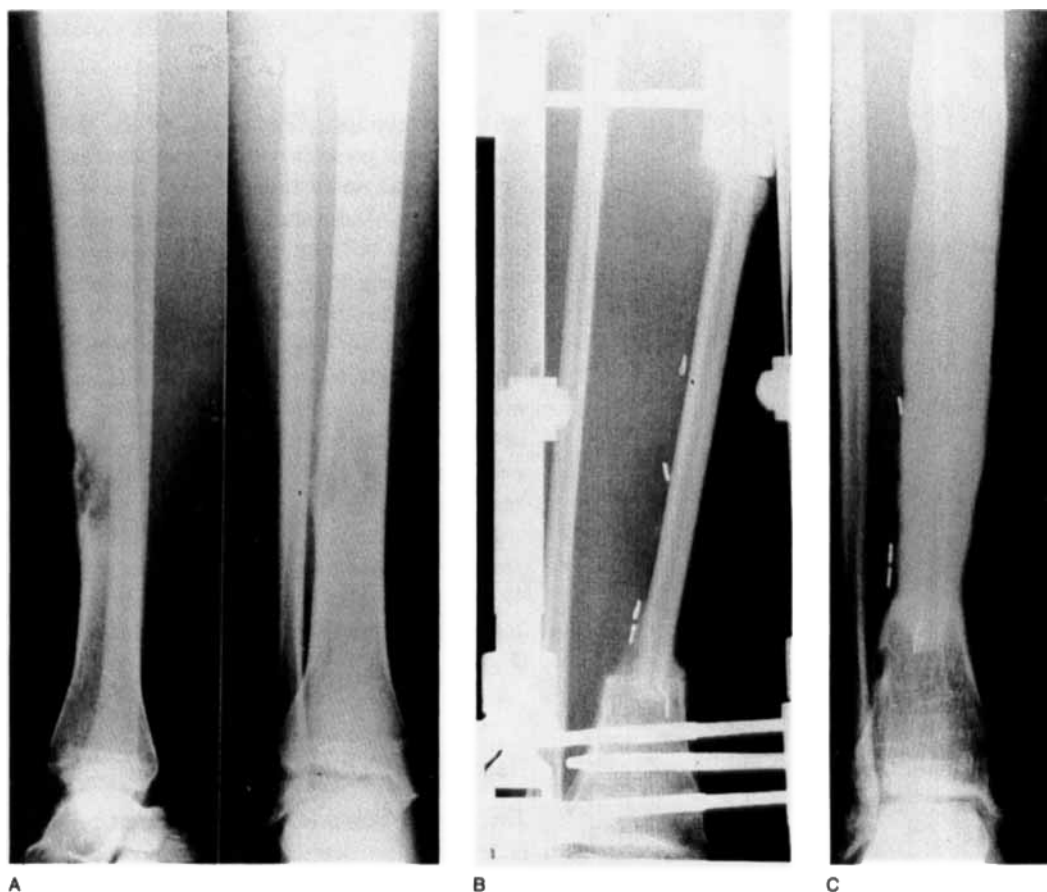


Figure 2. Case 2. Adamantinoma of the tibial diaphysis in a 13-year-old girl.

A. Preoperatively.

B. 2 months after operation, callus formation at the bone junctions.

C. 9 months after operation and after 3 months of weight bearing, the fibular graft has hypertrophied.

- pseudarthrosis, which is almost painless and permits 30° of motion, more than is obtained at the junction between the fibular head and glenoid cavity. Five years after the first operation, the patient has full flexion and 10° of extension loss in the elbow, normal rotation in the lower arm, and normal hand function. He works full time as a clerk, plays soccer in the summer and ice hockey in the winter.
2. A 13-year-old girl with an adamantinoma had 14 cm of the tibial diaphysis resected. The graft was tucked into the remaining parts of tibia, and external fixation was applied. Radiographs 2 months after operation showed callus formation both distally and proximally. Three months after the operation, the external fixation was removed and replaced with a lower leg orthosis. The patient began full weight bearing 6 months after the operation, after which the fibular graft thickened. Nine months after the operation, the size of the fibula was similar to that of the contralateral tibia (Figure 2). The patient has normal leg function and had no pain at the latest follow-up 4.5 years after the operation.
 3. A 13-year-old girl with an Ewing sarcoma had a 16-cm resection of the ulnar diaphysis after systemic chemotherapy and local radiotherapy. The graft was stabilized with 2-cm plates and screws at both ends, and, for control of forearm rotation, external fixation was applied before resection. Graft healing was rapid distally, but slow proximally. The external fixation was removed after 4 months. At the latest follow-up 4 years after the operation, she had 100° pronation in the lower arm and full motion in the elbow, wrist, and fingers.
 4. A 44-year-old woman with a giant cell tumor in the distal femur was treated with curettage and autologous bone grafting. She then had several fractures through the tumor area and developed a severe knee arthrosis with pain and decreased motion. Ten years after the first operation a large local recurrence occupying most of both femoral condyles was diagnosed. Ten centimeters of the distal femur including the knee joint was resected. A long Küntscher nail through the femur and the tibia was inserted and the bone defect was bridged with a vascularized fibular graft laterally and a nonvascularized autologous iliac bone graft medially. Bone healing was uncomplicated and the patient walked with full weight bearing 7 months after the operation. She had no pain and worked full time as a cook at the latest follow-up 4 years after the operation.
 5. A 12-year-old boy with an Ewing sarcoma had 17 cm of the femoral shaft resected after systemic chemotherapy. The graft was tucked into the remaining parts of the femur and external fixation was applied. The microscopic examination showed a marginal margin in one part of the surgical specimen and local radiotherapy (40 Gy) was added to the planned postoperative chemotherapy. After 6 months on crutches, the patient was allowed to walk on the leg. The external fixation was removed after 8 months. Two days later, the graft fractured when the patient turned in bed. After 2 months in external traction, the patient started partial weight bearing in a hip orthosis. Callus was seen radiographically after another 2 months, and the patient was then allowed full weight bearing. Six months after the fracture, the radiographs showed widening of the graft for the first time. Two years after the operation, the patient fell down outdoors and fractured the graft below the earlier fracture. He was treated with a thigh plaster cylinder. Callus developed, but the fracture did not heal. It was exposed 8 months after the fracture and bridged by autologous iliac grafts and then healed in 3 months. Three and a half years after tumor surgery, the patient had a 7-cm shortening of the right lower extremity, full range of motion in the hip, and full extension with 25° flexion in the knee.
 6. A 13-year-old boy with a high-grade malignant osteosarcoma had 15 cm of the proximal humerus including the joint resected after systemic chemotherapy. The graft was tucked into the distal humerus and into the upper lateral part of the scapula for a shoulder arthrodesis. In addition, a cortical bone graft from the tibia was fixed to the humerus and to the acromion. External fixation was supported for 2 months with a thoracobrachial orthosis.

Then, the patient used his arm freely with increasing mobility between the scapula and the thoracic cage (Figure 3). Six months after the operation, the patient fell and fractured the fibular graft without loosening of the external fixation. The pain disappeared after a few days, and the fracture was radiographically healed after 6 weeks. The external fixation was removed 10 months after the operation and 1 month later, the patient fell again, and now both grafts fractured 3 cm distal to the first fracture. These fractures were treated with an orthosis. Radiographs after 3 weeks showed more callus in the fibular graft than in the tibial graft fracture (Figure 3). At the same time, a tumor recurrence was diagnosed in the distal part of the right humerus. The arm was amputated through the healed shoulder arthrodesis.

Histologic examination showed tumorfree bone around the healed anastomosis between the graft and the distal humerus. The recurrence was thus probably caused by a so-called skip metastasis. Ten months later, multiple metastases were diagnosed, and the boy died 4 months later.

7. A 14-year-old girl with a high-grade malignant osteosarcoma had 17 cm of the right humeral shaft excised after preoperative chemotherapy. The surgical specimen included the surrounding muscles and 15 cm of the radial nerve. The bone graft was bridged by one vascularized and one avascular fibular graft after external fixation. The vascularized fibula was tucked into the proximal and distal humerus. The avascular graft was fixed by screws. Three months later, the nerve defect was

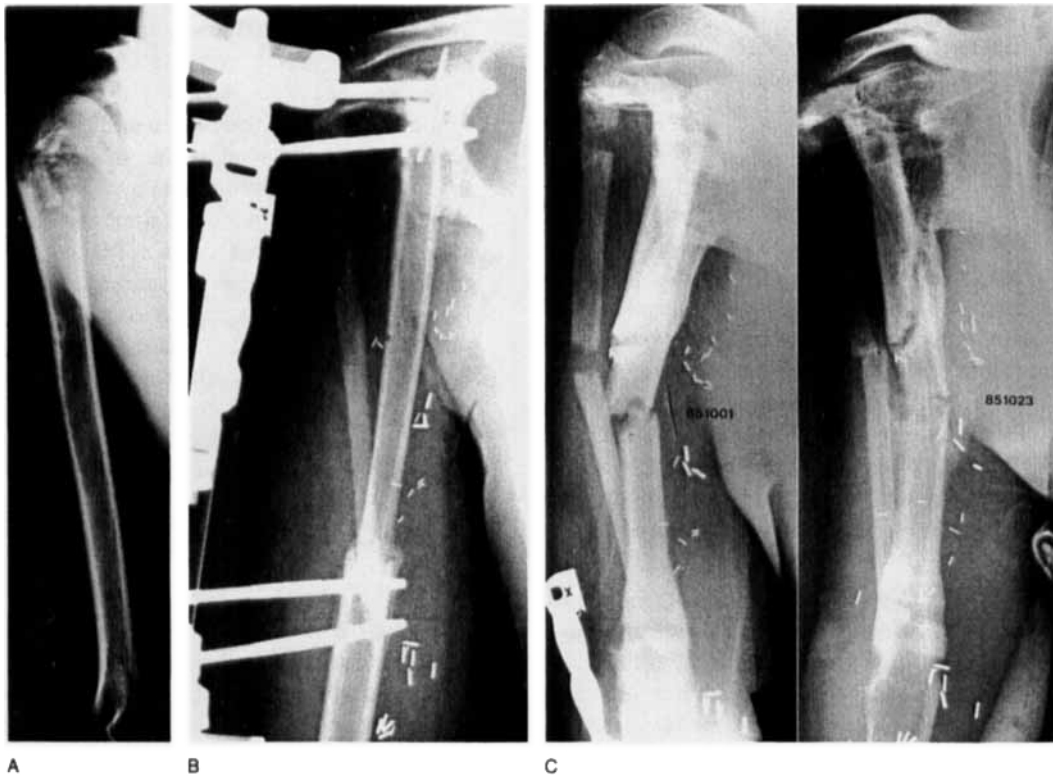

Figure 3. Case 6. Osteosarcoma with fracture of the proximal humerus in a 13-year-old boy.

A. At admission

B. 2 months after operation; 15 cm of the proximal humerus has been resected. The fibular graft was tucked into the distal humerus and into the upper lateral part of scapula. For stabilization a nonvascularized cortical bone graft from the tibia was fixed to the humerus and to the acromion.

C. At the second trauma 11 months after the operation, both grafts fractured (left). After 3 weeks, more callus can be seen around the thickened vascularized fibular graft (right).

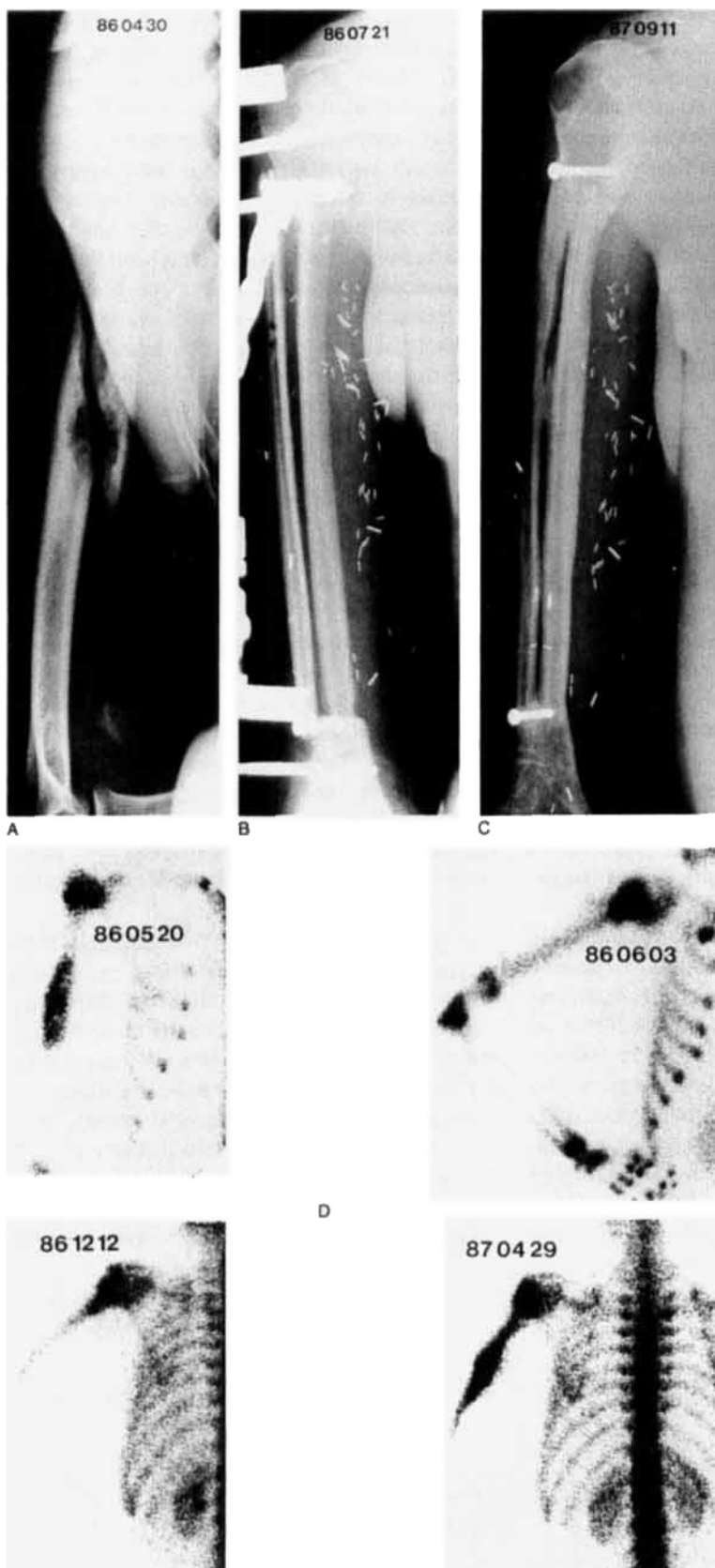


Figure 4. Case 7. Osteosarcoma with fracture of the humeral shaft in a 14-year-old girl.

A. At admission.

B. 17 cm of the humeral shaft has been resected. The fibular graft was tucked into the remaining parts of humerus. For stabilization a nonvascularized cortical bone graft from the tibia was used laterally.

C. 15 months after operation, hypertrophy of the vascularized, but not of the nonvascularized, graft can be observed.

D. Isotope uptake before (upper left), 5 days after (upper right), 6 months after (lower left), and 11 months after operation (lower right). The last examination was performed 6 weeks after removal of the external fixation. The uptake had now increased, and later radiographs showed thickening of the vascularized graft (Figure 4 c).

reconstructed with sural nerve grafts. The postoperative chemotherapy was finished 5 months after the tumor operation, and the external fixation was removed after another 4 months. Scintigraphy 6 weeks later showed a highly increased uptake of isotope and later radiographs now showed widening of the graft (Figure 4). At the latest follow-up, 15 months after the tumor operation, the girl had 150° abduction in the shoulder and 15°-150° flexion at the elbow. She could now extend the wrist and the fingers indicating a reinnervation of the radial extensor carpi and extensor digitorum muscles.

Discussion

Nonvascularized autografts bridging long defects carry a substantial risk for graft fractures and nonunion at the bone junctions; Enneking et al. (1977) reported that 5 of 20 patients treated with autografts required additional surgery because of graft complications. Similar complications, as well as deep infections, occur with the use of frozen cadaveric allografts; Mankin et al. (1982), in a series of 61 patients with allografts, reported 13 graft healing complications and 8 deep infections, 3 of them leading to amputation. Three of the infections occurred in the three patients treated with chemotherapy.

Multimodality therapy is now routine for several types of malignant bone tumors, notably osteosarcoma and Ewing sarcoma. Both chemotherapy and radiotherapy have adverse effects on bone turnover, especially osteoblastic activity, with delayed bone allograft incorporation and fracture healing (Östrup and Fredriksson 1975, Friedlaender et al. 1984). The use of large allografts for reconstruction following tumor surgery combined with chemotherapy, has been associated with a high rate of complications (Grant et al. 1981, Mankin et al. 1982, Dick 1985).

The use of vascularized bone grafts should make these complications less frequent (Östrup 1971, Moore et al. 1983). The uncomplicated healing of the bone junctions in our 4 cases on various combination of preoperative and postoperative chemotherapy and radiotherapy can probably be ascribed to the use of vascularized grafts. All the other patients also had early radiographic signs of callus formation at the bone anastomoses sites, and all but one healed. Our first patient developed a pseudarthrosis, which healed after bone grafting; the fixation with an orthosis was probably inadequate. Further, this was the only case in which the isotope uptake was questionable. There was, however, no resorption of the graft. In this first case the ischemic period was long, 4.5 hours, because we isolated the graft before the recipient vessels were identified. In the other patients, graft circulation was not severed until we had prepared the recipient vessels; and the ischemic period was shorter. Scintigraphy and angiography indicated patent vessel anastomosis in all the other 6 patients.

Four graft fractures occurred in 2 of the 6 patients who had graft circulation according to the scintigraphy. These 2 patients were treated with chemotherapy and radiotherapy preoperatively and postoperatively, which may have caused slow remodeling and strengthening of the grafts. However, all the fractures healed probably because the grafts were vascularized.

Experiments suggest that vascularized bone grafts have a capacity to respond to mechanical stress (Shaffer et al. 1985). This was especially well demonstrated in Case 2, with dramatic thickening of the graft during weight bearing (Figure 2), and in Case 7 with highly increased isotope uptake and thickening of the graft shortly after removal of the external fixation (Figure 4).

Our results indicate that vascularized bone grafts can be used for reconstruction of large bone defects in patients also given chemotherapy and radiotherapy.

References

- Berggren A, Weiland A J, Ostrup L T. Bone scintigraphy in evaluating the viability of composite bone grafts revascularized by microvascular anastomoses, conventional autogenous bone grafts, and free non-revascularized periosteal grafts. *J Bone Joint Surg (Am)* 1982;64(6):799-809.
- Dick H M, Malinin T I, Mnaymneh W A. Massive allograft implantation following radical resection of high grade tumors requiring adjuvant chemotherapy treatment. *Clin Orthop* 1985;(197):88-95.
- Donski P K, Buechler U, Tschopp H M. Surgical dissection of the fibula for free microvascular transfer. *Chir Plast* 1982;6:153-64.
- Enneking W F, Shirley P D. Resection arthrodesis for malignant and potentially malignant lesions about the knee using an intramedullary rod and local bone grafts. *J Bone Joint Surg (Am)* 1977;59(2):223-36.
- Friedländer G E, Tross R B, Doganis A C, Kirkwood J M, Baron R. Effects of chemotherapeutic agents on bone. I. Short term methotrexate and doxorubicin (adriamycin) treatment in a rat model. *J Bone Joint Surg (Am)* 1984;66(4):602-7.
- Gilbert A. Vascularized transfer of the fibular shaft. *Int J Microsurg* 1979;1(2):100-2.
- Grant T T, Eilberg F R, Johnson E E. Limb salvage in osteosarcoma. *Orthop Trans* 1981;5:427.
- Hirayama T, Suematsu N, Inoue K, Baitoh C, Takemitsu Y. Free vascularised bone grafts in reconstruction of the upper extremity. *J Hand Surg (Br)* 1985;10(2):169-75.
- Krag C, De Rose G, Lyczakowski T, Freeman C R, Shapiro S H. Free flaps and irradiated recipient vessels: an experimental study in rabbits. *Br J Plast Surg* 1982;35(3):328-36.
- Mankin H J, Doppelt S H, Sullivan T R, Tomford W W. Osteoarticular and intercalary allograft transplantation in the management of malignant tumors of bone. *Cancer* 1982;50(4):613-30.
- Moore J R, Weiland A J, Daniel R K. Use of free vascularized bone grafts in the treatment of bone tumors. *Clin Orthop* 1983;(175):37-44.
- Shaffer J W, Field G A, Goldberg V M, Davy D T. Fate of vascularized and nonvascularized autografts. *Clin Orthop* 1985;(197):32-43.
- Weiland A J, Daniel R K, Riley L H Jr. Application of the free vascularized bone graft in the treatment of malignant or aggressive bone tumors. *John Hopkins Med J* 1977;140(3):85-96.
- Östrup L T. The free, living bone graft an experimental study. Thesis. University of Linköping, Sweden 1971;(31).
- Östrup L T, Fredrickson J M. Reconstruction of mandibular defects after radiation, using a free, living bone graft transferred by microvascular anastomose. An experimental study. *Plast Reconstr Surg* 1975;55(5):563-72.