

Reconstruction of the tibia by dual grafting

3 cases of tumor resection

Bart A. Swierstra, Willard J. Rijnberg and Bert van Linge

Large defects of the tibia can be bridged with autologous cancellous grafts between the remaining fibula and a contralateral tibial cortical graft. The long-term results of this technique in 3 cases after resection of a malignant tumor were either excellent or fair. It is concluded that this technique is an effective limb-saving surgical procedure.

Between 1977 and 1982, 3 patients with a primary bone sarcoma underwent wide resection and reconstruction of the tibia without adjuvant chemotherapy or radiotherapy.

Case 1. A 25-year-old female with a Stage IA adamantinoma of the tibia. Bone defect 17 cm.

Case 2. A 19-year-old male with a Stage IA osteosarcoma of the distal tibia. Bone defect 15 cm down to the ankle joint.

Case 3. A 21-year-old female with a Stage IB adamantinoma of the tibia. Bone defect 26 cm (Figure 1).

Resection was followed by a two-step reconstructive procedure. In the first step the defect was bridged by a cortical graft from the contralateral tibia. In Case 1 an external fixator was used, and in the other cases a long-leg plaster cast was applied. In Case 2 the tibial grafting was performed after the primary resection, and in the other cases during the same operation. The donor leg was protected in a patella-tendon-bearing plaster cast for 2 months.

In the second step, iliac bone strips were packed between the fibula and the cortical graft through a lateral approach between the peroneal muscles and long extensor. This operation was performed after healing of the first wound and definitive pathologic reports. During healing the leg was protected in a plaster cast. A gradual increase in weight bearing

was allowed after about 2 months. A brace was applied afterwards until consolidation.

All the patients have been followed clinically and radiographically. Functional evaluation has been performed according to Enneking (1987).

Results

In Case 1 the amount of iliac bone strips near the proximal osteotomy was too sparse. After removal of the brace at 6 months, nonunion was evident. Supplementary cancellous grafting was performed at 9 months. The functional result was excellent at 17 months.

In Case 2, fracture of the grafts occurred after a fall at 9 months when the brace had been removed. Union during plaster cast immobilization did not occur, necessitating a second cancellous graft. At 2 years, the result was fair, with an arthrodesis of the ankle joint.

In Case 3 the brace could be discontinued at 10 months. An excellent end result was obtained at 1 year.

In none of the patients was there any donor site problem.

A remarkable transformation of the grafts took place resulting in a weight-bearing shaft, including the cortex and marrow cavity. This transformation continued for years as documented by computer tomography (Figure 1)

At 6-12 years' follow-up, no recurrence has been observed.

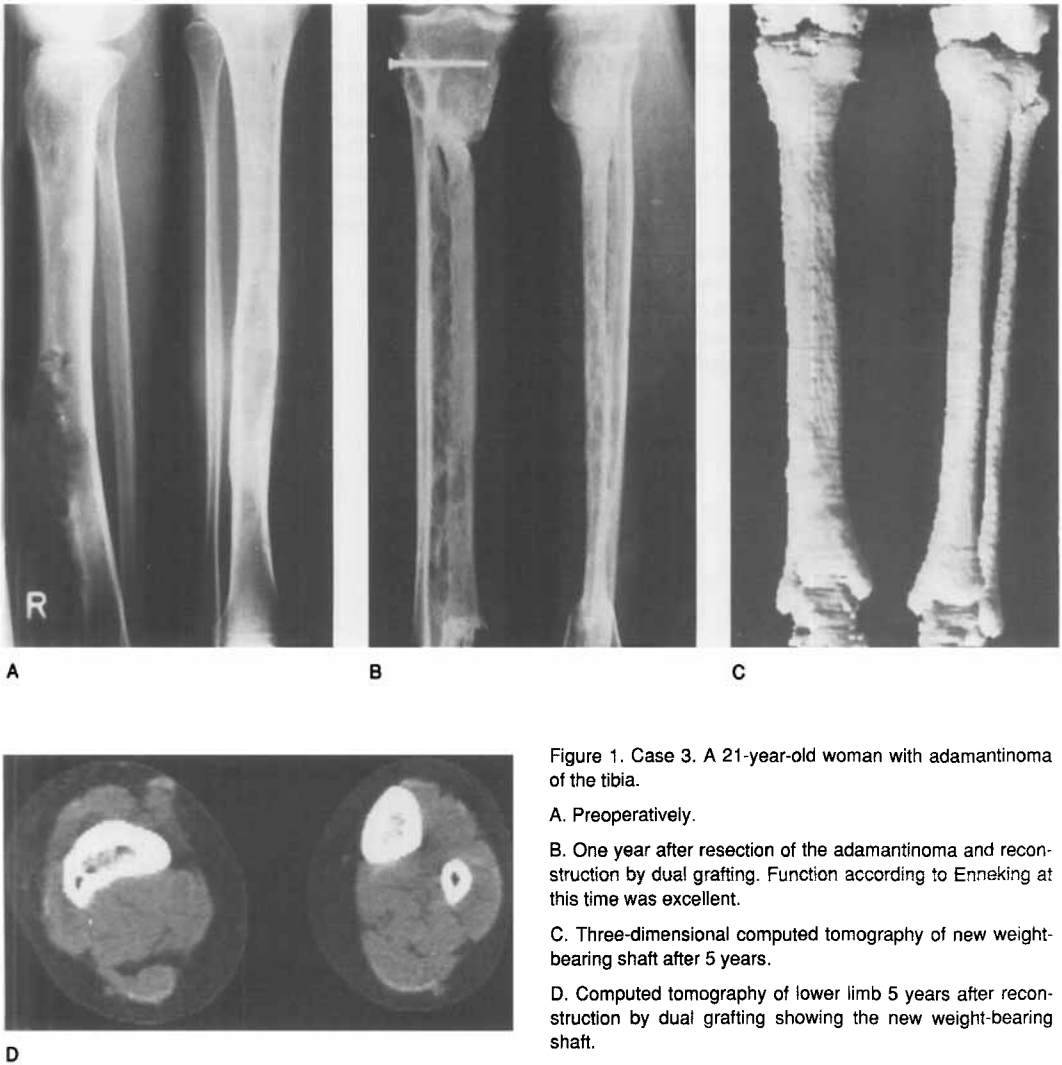


Figure 1. Case 3. A 21-year-old woman with adamantinoma of the tibia.

A. Preoperatively.

B. One year after resection of the adamantinoma and reconstruction by dual grafting. Function according to Enneking at this time was excellent.

C. Three-dimensional computed tomography of new weight-bearing shaft after 5 years.

D. Computed tomography of lower limb 5 years after reconstruction by dual grafting showing the new weight-bearing shaft.

Discussion

The aim of the described procedure is to induce the formation of a new weight-bearing shaft between the original fibula and the cortical graft, and not the incorporation of an autologous cortical graft in the bone defect, as has been described by others (Enneking et al. 1980). From our experience with these patients and also with our posttraumatic cases (Rijnberg and Van Linge 1988), we advocate the following: large amounts of autologous iliac bone strips as a central cancellous graft, nonrigid immobilization, and early weight bearing.

The actual interest in limb salvage is focused on allografts, vascularized fibular grafts, and endoprostheses. The advantages of our procedure are technical simplicity, no stress-shielding implant, permanent solution, and integrity of the contralateral limb.

The excellent result of our last patient, in which all the aforementioned prerequisites were met, was reached after 1 year. The same period of time for "clinically complete" reconstruction is proposed for allografts (Gebhardt et al. 1987) and vascularized fibular grafts (De Boer and Wood 1989). The complications that we encountered (nonunion, fracture) do not differ from those in other reconstructive techniques.

Our patients did not receive adjuvant treatment. Based on our experiences, we cannot predict the outcome of dual grafting under a multimodality therapy.

In conclusion, we think that this technique deserves consideration when choosing a reconstructive procedure for the tibia, either as a primary solution or as a salvage procedure for failed alternatives.

References

- de Boer H H, Wood M B. Bone changes in the vascularised fibular graft. *J Bone Joint Surg (Br)* 1989; 71(3): 374-8.
- Enneking W F, Eady J L, Burchardt H. Autogenous cortical bone grafts in the reconstruction of segmental skeletal defects. *J Bone Joint Surg (Am)* 1980; 62(7): 1039-58.
- Enneking W F. A system for the functional evaluation of the surgical management of musculoskeletal tumors. In: *Limb Salvage in Musculoskeletal Oncology*. 2nd Bristol Myers/Zimmer Orthopedic Symposium, Orlando, Florida 1985 (Ed. Enneking W F). Churchill Livingstone, New York 1987: 5-15.
- Gebhardt M C, Lord F C, Rosenberg A E, Mankin H J. The treatment of adamantinoma of the tibia by wide resection and allograft bone transplantation. *J Bone Joint Surg (Am)* 1987; 69(8): 1177-88.
- Rijnberg W J, van Linge B. Central cancellous graft of the leg for long standing pseudarthrosis of the tibia. *Acta Orthop Scand* 1988; 59 (Suppl 227): 66.