

# Longitudinal ruptures of the peroneal tendons

## A report of a rugby player

Etsuo Shoda<sup>1</sup>, Masahiro Kurosaka<sup>2</sup>, Shinichi Yoshiya<sup>2</sup>, Akira Kurihara<sup>1</sup>  
and Kazushi Hirohata<sup>2</sup>

Rupture of one or both peroneal tendons is rare. We present a case of longitudinal ruptures in both peroneus longus and brevis tendons.

We obtained a very satisfactory clinical result with surgical debridement of the abnormal granulation tissue and proliferated synovial sheath.

Departments of Orthopedics, Kobe <sup>1</sup>Rosai and <sup>2</sup>University Hospital, Kobe, Japan

Correspondence: Dr. Masahiro Kurosaka, Department of Orthopedics, Kobe University Hospital, 7-5-1, Kusunoki-cho, Chuo-ku, Kobe 650 Japan

Tel +81-78-341-7451 Ext. 5622. Fax +81-78-351-6930

Submitted 91-02-62. Accepted 91-07-10

A 22-year-old male rugby player had had repeated ankle sprains and a 2-year history of increasing right lateral ankle pain and swelling. After experiencing sharp pain in his right ankle while jogging, his symptoms became exacerbated. However, he continued to play rugby with the ankle taped. Swelling and pain along the peroneal tendons increased, and occasionally there was a snapping sound. He also received several local steroid injections.

Upon physical examination, there were no signs of subluxation of the peroneal tendons. Plain radiographs were normal. A CT scan demonstrated swelling of the soft tissues around the peroneal tendons, but a rupture was not identified (Figure 1). We suspected chronic peroneal tenosynovitis, and decided to explore the tendons.

During surgery, marked proliferation and hypertrophy of the peroneal tendon sheath were observed.

Underneath this hypertrophic tendon sheath, a 4-cm longitudinal rupture of the brevis tendon and a small longitudinal tear in the longus tendon were found (Figure 2).

Granulation tissue around the tendons was thoroughly debrided, and the proliferated synovial sheath was removed. The retinaculum was sutured, and the smooth movement of both tendons was confirmed before skin closure. A histologic examination revealed tenosynovitis, but no deposition of steroids was found.

After surgery, a below-the-knee plaster cast was worn for 6 weeks. Our patient resumed playing rugby 5 months after his surgery; and at the 2-year follow-up examination, he reported that he was able to play rugby as well as before his injury, without pain or swelling.

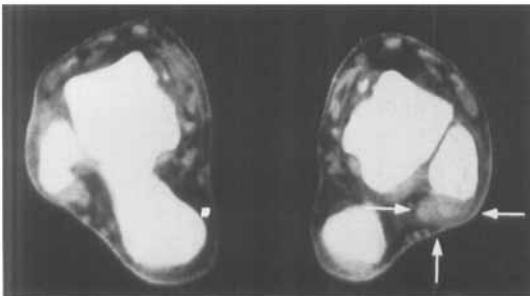


Figure 1. A CT scan showing the swelling of soft tissues around the peroneal tendons (arrows).

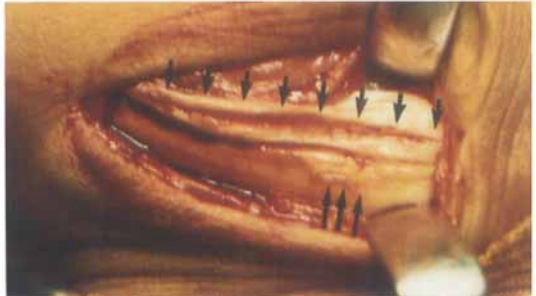

Figure 2. The 4-cm longitudinal rupture of the peroneus brevis tendon (small arrows) and a small longitudinal tear in the peroneus longus tendon (long arrows).

## Discussion

Only a few cases with peroneal tendon ruptures have been reported, and they have been associated with a giant lateral malleolus (Burman 1956), secondary degenerative changes due to fracture of the os peroneum (Cachia and Grumbine 1988, Peacock et al. 1986), an abnormal os peroneum (Thompson and Paterson 1989), absence of the long peroneus tendon (Cross et al. 1988), and an abnormally large peroneal sesamoid (Evans 1966).

Only 3 cases of a longitudinal tear of peroneal tendons have been reported: Munk and Davis (1976) have reported 1 case of longitudinal rupture of the peroneus brevis tendon, and Larsen (1987) has reported 2 similar cases. Because the peroneus brevis tendon routes between the peroneal longus tendon and the edge of the lateral malleolus, the above-mentioned authors speculated that the peroneus longus tendon may act like a wedge and split the underlying flattened peroneus brevis tendon during dorsiflexion of the ankle. Another possible explanation of this rupture is that the peroneus brevis tendon subluxates and is split by the posterior margin of the lateral malleolus under the compression of the peroneus longus tendon.

In our case, although the patient had a history of repeated ankle sprains, subluxation of the peroneal tendon could not be verified in the clinical and CT examinations. Therefore, we speculated that repeated trauma seemed to have been concentrated in and around the peroneal tendons. Subsequently, the peroneus brevis tendon was exposed to the constant

pressure between the peroneus longus tendon and the lateral malleolus, finally consummating in chronic rupture. Although no steroid deposits were found during the histologic examination, the local injection of steroids might have had a deleterious effect on this process.

## References

- Burman M. Subcutaneous tear of the tendon of the peroneus longus. *Arch Surg* 1956; 73: 216-219.
- Cachia V V, Grumbine N A. Spontaneous rupture of the peroneus longus tendon with fracture of the os peroneum. *J Foot Surg* 1988; 27: 328-333.
- Cross M J, Crichton K J, Gordon H, Mackie I G. Peroneus brevis rupture in the absence of the peroneus longus muscle and tendon in a classical ballet dancer. A case report. *Am J Sports Med* 1988; 16: 677-678.
- Evans J D. Subcutaneous rupture of the tendon of peroneus longus. Report of a case. *J Bone Joint Surg (Br)* 1966; 48: 507-509.
- Larsen E. Longitudinal rupture of the peroneus brevis tendon. *J Bone Joint Surg (Br)* 1987; 69: 340-341.
- Munk R L, Davis P H. Longitudinal rupture of the peroneus brevis tendon. *J Trauma* 1976; 16: 803-806.
- Peacock K C, Resnic E J, Thoder J J. Fracture of the os peroneum with rupture of the peroneus longus tendon. A case report and review of the literature. *Clin Orthop* 1986; 202: 223-226.
- Thompson F M, Paterson A H. Rupture of the peroneus longus tendon. *J Bone Joint Surg (Am)* 1989; 71: 293-295.