

# Mechanoreceptors in the posterior cruciate ligament

## Histologic study on cadaver knees

Pavlos G. Katonis<sup>1</sup>, Antonis P. Assimakopoulos<sup>1</sup>, Manolis V. Agapitos<sup>2</sup>  
and Evangelos I. Exarchou

The purpose of the study was to identify mechanoreceptors in the healthy, human posterior cruciate ligament. Ten ligaments from 10 fresh cadavers were studied with light microscopy. In addition to free nerve endings, two types of encapsulated mechanoreceptors were identified. They were located at the femoral and tibial attachments, and

on the surface of the ligament. These findings support the hypothesis that the posterior cruciate ligament has an anatomic basis for a discriminating afferent flow of nerve impulses to the central nervous system. Therefore, its neural network may play a role in regulating the contraction of muscle groups that are fundamental to knee stability.

<sup>1</sup>Second Department of Orthopedics, The General Hospital of Athens, and <sup>2</sup>Department of Pathology, University of Athens, Greece

Correspondence: Dr. Pavlos G. Katonis, 16, Mitropolitou Iacovou St., GR-145 61 Kifissia-Athens, Greece

Tel + 30-1 80 87 282

Submitted 90-06-26. Accepted 91-01-11

Although there has recently been an increased interest in knee neurology (Kennedy et al. 1982, Day et al. 1985, Zimny et al. 1986, Halata and Haus 1989) and the role of the posterior cruciate ligament in the kinesiology of the human knee is accepted, the existence of neural elements in this ligament remains relatively unknown. The mechanoreceptors of the posterior cruciate ligament in the knee joint have been widely investigated in animals (Samuel 1952, Boyd 1954, Skoglund 1956, Freeman and Wyke 1967). Schultz et al. (1984) have studied the neural network of this ligament in the human knee, but their research was limited exclusively to arthrotic knee joints. Therefore, the purpose of our investigation was to identify the possible existence of mechanoreceptors in the posterior cruciate ligament of the healthy human knee joint.

### Material and Method

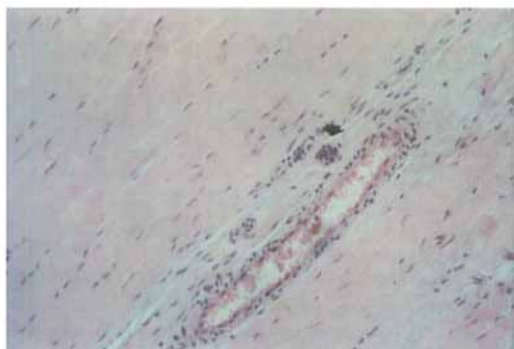
Ten posterior cruciate ligaments from 10 fresh cadavers (7 men and 3 women, aged 15 to 45 years) were studied. All the specimens were unaffected by joint disease, and they were obtained within 24 h of death. They were kept in a normal saline solution until transfer to the laboratory, where they were stained using the gold chloride method as modified

by O'Connor and Gonzales (1979). The ligaments were then embedded in paraffin blocks; longitudinal serial 5- $\mu$ m sections were made; and the prepared slides were studied under a light microscope. The nerve endings were classified into four types according to Freeman and Wyke (1967): Type I or Ruffini's corpuscles, Type II or Vater-Pacini corpuscles, Type III or Golgi's corpuscles, and Type IV or free nerve endings.

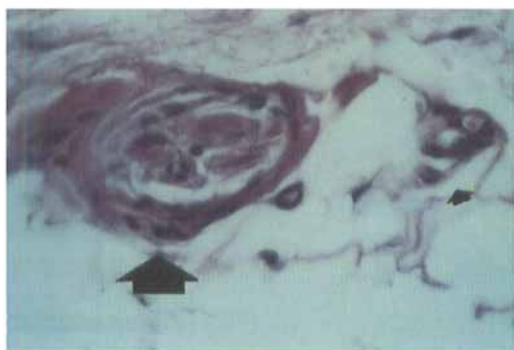
### Results

The posterior cruciate ligaments presented an extensive intraligamentous neural network. Three types of nerve endings were observed: Ruffini's corpuscles, Vater-Pacini corpuscles, and free nerve endings.

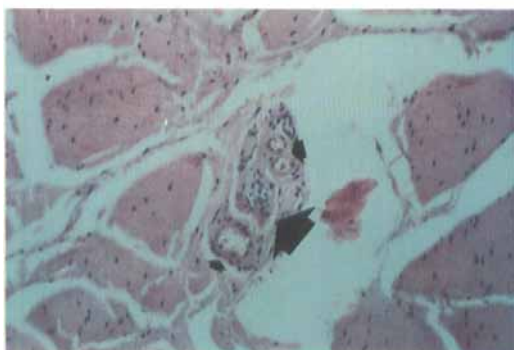
The Ruffini corpuscles consisted of a loose arborization of nerve fibers ending in flattened expansions and interspersed with a peculiar granular material dotted with nuclei. Elongated connective tissue bundles and fibroblasts provided support to the structure. The Vater-Pacini corpuscles were made up of a central elongated granular mass with many concentric thin layers. The free nerve endings represented unmyelinated thin fibers.



Type I or Ruffini's corpuscle (arrow).  $\times 40$ .



Vater-Pacini corpuscles (large arrow); free nerve ending (small arrow).  $\times 600$ .



Interfascicular connective tissue; Vater-Pacini corpuscles (large arrow); and surrounding capillaries (small arrows).  $\times 40$ .

Figure 1. Nerve endings in the posterior cruciate ligament. Gold chloride.

These three types of nerve endings existed in each ligament, but they were present in greater numbers at each bony attachment. We were unable to identify any Type III or Golgi's corpuscles. In the interfascicular connective tissue, only Vater-Pacini corpuscles were seen (Figure 1).

Another finding was the presence of capillaries surrounding all the types of neural tissue.

## Discussion

The mechanoreceptors in the anterior cruciate ligament of the human knee have been thoroughly described (Zimny et al. 1986, Halata and Haus 1989). To our knowledge, there is only one histologic study on the human posterior cruciate ligament, but on arthrotic knees (Schultz et al. 1984). Our study includes posterior cruciate ligaments only from healthy human knees, where we observed receptors of Type I or Ruffini's corpuscles, with a very slow threshold reaction to pressure changes; Type II or Vater-Pacini corpuscles, rapidly adapting, because they are velocity receptors; and Type IV or free nerve endings, which form the actual pain receptor system. Most of these mechanoreceptors were observed at each bony attachment and on the surface of the studied ligaments. The same observations on the human anterior cruciate ligament have been previously reported (Zimny et al. 1986, Halata and Haus 1989).

It is difficult to explain the absence of Type III or Golgi's corpuscles.

Because Schultz et al. (1984) described only one intact Type III receptor in each cruciate ligament, but from arthrotic knees, and because all the other reports concerned experiments carried out on animals (Skoglund 1956, Burgess and Clark 1969, Grigg et al. 1977), they cannot be compared to the present study.

We are also unable to explain the close relationship of blood vessels to corpuscles. We can only suggest that free nerve endings may have a vasomotor action (Freeman and Wyke, 1967). Although the neural tissue within the posterior cruciate ligament is the center of proprioceptive signals of sensitivity to the central nervous system, the control of muscle activity from this function is still under discussion (Skoglund 1956, Burgess and Clark 1969, Grigg and Greenspan 1977, Zimny et al. 1986).

The observation in our study that the healthy human posterior cruciate ligament contains Type I, II, and IV receptors suggests that a rupture of this ligament does not only create a mechanical disturbance, but also a neurologic disturbance, which is caused by the interruption of the afferent flow of nerve impulses to the central nervous system.

## References

- Boyd I A. The histological structure of the receptors in the knee joint of the cat correlated with their physiological response. *J Physiol (Lond)* 1954; 124: 476-88.
- Burgess P R, Clark F J. Characteristics of knee joint receptors in the cat. *J Physiol (Lond)* 1969; 203(2): 317-35.
- Day B, Mackenzie W G, Shim S S, Leung G. The vascular and nerve supply of the human meniscus. *Arthroscopy* 1985; 1(1): 58-62.
- Freeman M A, Wyke B. The innervation of the knee joint. An anatomical and histological study in the cat. *J Anat* 1967; 101(3): 505-32.
- Grigg P, Greenspan B J. Response of primate joint afferent neurons to mechanical stimulation of knee joint. *J Neurophysiol* 1977; 40(1): 1-8.
- Halata Z, Haus J. The ultrastructure of sensory nerve endings in human anterior cruciate ligament. *Anat Embryol (Berl)* 1989; 179(5): 415-21.
- Kennedy J C, Alexander I J, Hayes K C. Nerve supply of the human knee and its functional importance. *Am J Sports Med* 1982; 10(6): 329-35.
- O'Connor B L, Gonzales J. Mechanoreceptors of the medial collateral ligament of the cat knee joint. *J Anat* 1979; 129(4): 719-29.
- Samuel E P. The autonomic and somatic innervation of the articular capsule. *Anat Rec* 1952; 113: 53-70.
- Schultz R A, Miller D C, Kerr C S, Micheli L. Mechanoreceptors in human cruciate ligaments. A histological study. *J Bone Joint Surg (Am)* 1984; 66(7): 1072-6.
- Skoglund S. Anatomical and physiological studies of knee joint innervation in the cat. *Acta Physiol Scand* 1956; (Suppl 124): 36.
- Zimny M L, Schutte M, Dabezies E. Mechanoreceptors in the human anterior cruciate ligament. *Anat Rec* 1986; 214(2): 204-9.