

Intraarticular fractures of the distal end of the radius in young adults

A 16 (2-26) year follow-up of 42 patients

Hans Henrik Strange-Vognsen

Forty-two patients, aged 29 (17-42) years when they sustained an intraarticular fracture of the distal end of the radius, were reexamined after 16 (2-26) years. More than two thirds of the fractures were caused by high-energy trauma. Subjectively, 34 patients had excellent or good results, while only 8 had fair or poor results; 6 patients had changed their occupation owing to disability from the wrist. Almost half of the patients had residual deformity at the follow-up clinical examination. Slightly more than half of the

patients had radiographic arthrosis. Subjective evaluation correlated with residual deformity and arthrosis, but not with radiographic displacement or intraarticular step off. Arthrosis correlated with residual deformity and intraarticular step off, but not with radiographic displacement. Clinical residual deformity included soft-tissue changes in contrast to radiographic displacement. More interest should be directed to soft-tissue changes following this type of fracture.

Orthopedic Hospital, Sorø, Denmark. Correspondence: Dr. H. H. Strange-Vognsen, Nøddekrogen 7, DK-2920 Charlottenlund, Denmark

Submitted 89-04-08. Accepted 91-05-03

Arthrosis is common after an intraarticular fracture of the distal end of the radius in young adults (Gartland and Werley 1951, Smaill 1965, Cooney et al. 1980, Knirk and Jupiter 1986), but the long-term results are otherwise largely unknown.

I analyzed clinical and radiographic findings and employment consequences 16 (2-26) years after intraarticular fracture of the distal end of the radius in young adults.

Patients and methods

From 1962 to 1985 inclusive, 54 patients under the age of 43 years were admitted to Orthopedic Hospital (Sorø, Denmark) with an intraarticular fracture of the distal end of the radius. Patients with fractures of the carpal bones or ulna, except the styloid, and patients with epiphysiolysis or a previous fracture of the same radius were not included. At follow-up, 3 patients did not attend, 3 patients had emigrated, 2 patients were deceased, 1 patient could not be located, 1 patient refused to participate, and 2 patients had had a refracture during the follow-up period. Thus, there were 42 patients available for follow-up on an average of 16 (2-26) years after the fracture (Table 1). There were 32 men and 10 women aged 29 (17-42) years at the time of injury. The fracture was classified on the basis of the first radiographs taken or, in 15 cases, from the

radiography report. There were 28 Colles, four Smith, and two Barton fractures; eight comminuted fractures could not be classified. The fractures were in more than two thirds of the cases high-energy fractures caused by traffic accidents or by a fall from one level to another. The treatment was in most of the cases closed reduction; only 3 patients were operated on. All of them had plaster cast immobilization and were normally followed as outpatients to ensure rehabilitation.

The intraarticular step off was measured as the highest step off on the radiographs taken at the end of immobilization. Of these radiographs, 13 were lost; but, except for 2 cases, data were found in the radiography report. Thirteen fractures had no intraarticular step off, 20 fractures had a step off from 0 to 1 mm, and only seven fractures had a step off measuring more than 1 mm.

At follow-up, all the patients were interviewed regarding subjective complaints and employment consequences (Table 2). A standardized clinical examination was refused in Case 39, and was impossible to carry out in Case 24, who had radiocarpal fusion in the follow-up period. Three patients were examined by an orthopedic specialist at the local hospital. The subjective evaluation and the clinical examination were based on a scheme used to evaluate healed Colles' fractures (Gartland and Werley 1951). Arthrosis grading (Table 3) and measurement of radial or volar displacement (Figure 1; Van der Linden and Erikson 1981) were performed on the standard radiographs of

Table 1. Observations in 42 cases of intraarticular fracture of the distal end of the radius in young adults

No.	A	B	C	D	E	F	G	H	I	J	K	L	M	N	O	P	Q	R	S
1	F	30	1	1	2	22	2	1	1	1	1	2	1	2	2	1	1	4	2
2	F	23	6	1	2	18	4	3	2	1	1	2	2	2	2	2	5	0	2
3	F	39	1	1	2	17	1	1	2	1	1	1	1	1	1	-	-	-	2
4	M	28	6	1	2	7	3	1	1	1	1	1	2	2	2	2	1	2	2
5	M	28	1	1	1	18	1	1	1	1	1	1	2	2	2	1	1	5	1
6	M	26	1	1	2	14	2	1	1	1	1	1	2	2	2	1	6	1	2
7	F	41	4	2	1	17	1	1	1	1	1	1	2	2	2	-	-	-	3
8	F	35	2	1	2	9	2	1	2	1	1	1	2	2	2	1	2	3	2
9	M	31	5	2	2	23	2	1	2	2	1	1	1	1	2	2	6	2	1
10	M	27	5	4	2	11	2	1	2	2	1	1	2	2	2	2	2	2	2
11	M	23	2	1	2	21	1	1	2	1	1	1	2	2	2	0	3	1	2
12	F	17	5	1	2	3	2	1	2	1	1	1	2	2	2	0	8	0	2
13	M	20	2	1	1	22	2	1	1	1	1	1	2	2	2	0	5	1	1
14	F	38	4	4	3	5	3	1	2	1	1	1	2	2	2	1	2	2	3
15	M	23	5	2	2	3	2	1	1	1	1	1	2	2	2	0	1	3	2
16	M	25	2	1	2	10	4	1	2	2	1	2	2	2	2	2	5	2	2
17	M	20	2	1	2	19	1	3	1	1	1	1	2	2	2	2	4	5	4
18	M	30	1	4	1	15	1	1	1	1	1	1	2	2	2	0	0	2	2
19	M	34	1	1	2	25	4	3	2	2	2	2	1	1	2	0	3	9	1
20	M	25	3	4	2	24	1	1	1	1	1	1	1	1	2	0	1	2	-
21	M	34	4	1	1	25	1	1	2	1	1	1	1	1	2	0	4	2	1
22	M	21	6	1	2	12	1	1	1	1	1	1	2	2	2	0	2	1	3
23	F	41	1	1	2	17	3	1	2	1	1	1	2	2	2	-	-	-	1
24	M	40	2	4	4	5	4	3	-	-	-	-	2	2	2	-	-	-	4
25	M	24	2	1	2	19	1	1	1	1	1	1	1	1	2	2	6	1	2
26	M	18	5	4	1	25	1	1	1	1	1	1	1	1	2	0	4	6	1
27	M	39	2	1	2	16	1	1	1	1	1	1	1	1	2	1	1	2	2
28	M	32	6	1	2	8	1	1	1	1	1	1	1	2	2	1	3	1	2
29	M	17	2	1	2	17	2	1	2	1	1	1	1	1	1	-	-	-	-
30	M	29	7	4	1	25	1	1	1	1	1	1	1	1	2	2	5	2	1
31	M	40	3	2	2	22	3	1	2	2	2	1	1	1	2	2	2	2	1
32	F	36	1	1	2	15	2	3	2	2	1	1	2	2	2	1	0	5	2
33	M	42	2	1	2	17	1	1	2	1	1	1	2	2	2	0	0	4	2
34	F	36	1	1	2	2	2	1	1	1	1	1	2	2	2	0	6	6	1
35	M	21	5	1	1	3	1	1	1	1	1	1	2	2	2	0	4	2	2
36	M	30	1	1	1	21	2	3	1	1	1	1	2	2	2	0	0	3	1
37	M	21	8	4	1	26	1	1	1	1	1	1	1	1	2	0	1	1	1
38	M	26	5	1	3	9	2	1	2	1	1	1	2	2	2	1	3	2	2
39	M	25	1	3	1	19	2	1	-	-	-	-	2	2	1	-	-	-	2
40	M	26	1	1	2	21	1	1	1	1	1	1	1	1	1	-	-	-	1
41	M	23	1	3	2	16	1	1	1	1	1	1	2	2	2	1	6	1	4
42	M	23	2	1	2	11	2	1	2	1	1	1	2	2	2	1	6	5	3

- A Sex
- B Age at injury
- C Cause of injury
 - 1 fall on the same level
 - 2 fall to another level
 - 3 machine work
 - 4 bicycle accident
 - 5 motorcycle accident
 - 6 car accident
 - 7 tractor accident
- D Type of fracture
 - 1 Colles'
 - 2 Smith's
 - 3 Barton's
 - 4 unclassified
- E Treatment
 - 1 no reduction
 - 2 closed reduction
 - 3 open reduction and fixation with K-wires
 - 4 open reduction, fixation with K-wires and bone chips' transplantation
- F Follow-up in years
- G Subjective evaluation according to Table 2
 - 1 excellent
 - 2 good
 - 3 fair
 - 4 poor
- H Employment consequences
 - 1 no employment consequences
 - 2 change in occupation due to sick leave
 - 3 change in occupation due to disability
- I Visible residual deformity: 1 no, 2 yes
- J Motion restricted: 1 no, 2 yes
- K Painful motion in the distal radioulnar joint: 1 no, 2 yes
- L Grip strength reduced: 1 no, 2 yes
- M Initial radiographs available: 1 no, 2 yes
- N Radiographs at the end of immobilization: 1 no, 2 yes
- O Radiography of both wrists at follow-up: 1 no, 2 yes
- P Arthrosis grading (Table 3)
- Q Dorsal or volar displacement (Figure 1): mm
- R Radial displacement (Figure 1): mm
- S Intraarticular step off (mm)
 - 1 0
 - 2 0-1
 - 3 1-2
 - 4 2-3

Table 2. Subjective evaluation, employment consequences, and data recorded at the clinical examination

Subjective evaluation	
Excellent:	No pain, disability, or limitation of motion
Good:	Occasional pain, slight limitation of motion, and no disability
Fair:	Occasional pain, some limitation of motion, feeling of weakness in the wrist, no particular disability if careful, and activities slightly restricted
Poor:	Pain, limitation of motion, disability, and activity more or restricted

Employment consequences

No change in occupation
Change in occupation due to disability from the wrist
Change in occupation due to sick leave because of the fracture

Clinical examination

Residual deformity visually compared with the other wrist
Motion restricted if less than dorsiflexion 45°, palmar flexion 30°, radial and ulnar deviation 15°, pronation and supination 50°
Painful motion in the distal radioulnar joint. Grip strength reduced if less than 60 percent of the opposite side

Table 3. Radiographic arthrosis grading on the basis of the radiographs taken of both wrists at follow-up

0	No signs of arthrosis
1	Joint space narrowing more than one third of the other wrist. Visible joint space
2	Joint space narrowing more than one third of the other wrist. Visible joint space. Osteophyte formation
3	Obliterated joint space

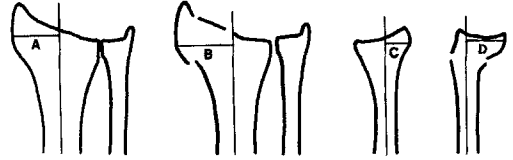


Figure 1. Radiographic measurements for radial displacement (B-A) and dorsal or volar displacement (D-C). The numerical value was used. D was always greater than zero.

both wrists taken at follow-up. This was impossible in Cases 3, 7, 23, 29, 40 due to fracture of the contralateral wrist, as well as in the patient with fusion and in the patient who refused clinical examination.

Nonparametric correlation analysis was performed according to Spearman.

Results

Subjectively, there were 19 excellent, 15 good, 4 fair, and 4 poor results. Six patients had changed their occupation due to disability from the wrist, including the patient with fusion, who had a disability pension. Clinical examination of 40 patients showed 18 cases of residual deformity, notably prominence of the ulnar head and thickening of the carpal region. Six patients had restricted motion, 2 had painful motion in the distal radioulnar articulation, and 4 had reduced grip strength. Arthrosis grading of 35 cases yielded the following results: 15 had no arthrosis, 11 had Grade 1, 9 had Grade 2, and 0 had Grade 3 arthrosis. Dorsal or volar displacement in 35 cases was found to be 2 mm or less in 16 cases, between 2 and 5 mm in 8 cases, and 5 mm or more in 11 cases. Radial displacement was found to be 2 mm or less in 23 cases, between 2 and 5 mm in 5 cases, and 5 mm or more in 7 cases.

There was a correlation ($P < 0.01$) between subjective evaluation and arthrosis ($\rho = 0.46$). Subjective

evaluation correlated ($P < 0.002$) with residual deformity ($\rho = 0.60$), but not with dorsal or volar displacement, radial displacement, or intraarticular step off. Arthrosis correlated ($P < 0.05$) with residual deformity ($\rho = 0.34$) and with intraarticular step off ($P < 0.05$; $\rho = 0.34$), but not with dorsal or volar displacement or with radial displacement. No correlation was found between residual deformity and intraarticular step off.

Discussion

It is difficult to classify this type of fracture due to the random nature of high-energy trauma. The male dominance is more pronounced than in distal forearm fractures in both younger and older age groups (Falch 1983, Benger and Johnell 1985, Solgaard and Petersen 1985).

The subjective evaluation with only one fifth fair or poor seems to be very good when compared with the two fifths found with a fair or poor evaluation after 7 years reported by (Knirk and Jupiter 1986). The treatment in my study was primarily nonoperative. The subjective evaluation by the 6 patients who had changed their occupation owing to disability from the wrist was 1 excellent, 2 good, and 3 poor. A better status at follow-up can be due to direct improvement or as a result of a less demanding occupation. The

changing nature of subjective evaluation must be emphasized.

Almost half of the patients had residual deformity, but only one fifth had other clinical defects. This does not indicate that residual deformity is of no importance, because residual deformity was strongly correlated with subjective evaluation and arthrosis. Radiographic arthrosis was found in slightly more than half of the patients, which accorded with the findings of others (Knirk and Jupiter 1986). The fact that both residual deformity and intraarticular step off are related to arthrosis, but not to each other, must imply that they represent two separate contributing factors to arthrosis.

Dorsal displacement and radial displacement were the only measurements found independently of each other in Colles' fractures; accordingly, they should provide a sufficient description of the bony displacement (Van der Linden and Ericson 1981). In my study, these radiographic measurements (Figure 1) did not correlate with subjective evaluation, arthrosis, and not even with clinical residual deformity. Intraarticular step off correlated only with arthrosis. Better radiographic measurements should be found.

The visually judged residual deformity correlated with both subjective evaluation and arthrosis; and although subjective, it is based on information from

two sources: namely, the bony displacement and the soft-tissue changes. Finally, more interest should be directed to the soft-tissue changes caused by trauma to the wrist.

References

- Bengner U, Johnell O. Increasing incidence of forearm fractures. A comparison of epidemiologic patterns 25 years apart. *Acta Orthop Scand* 1985; 56 (2): 158-60.
- Cooney W P, Dobyns J H, Linscheid R L. Complications of Colles' fractures. *J Bone Joint Surg (Am)* 1980; 62 (4): 613-9.
- Falch J A. Epidemiology of fractures of the distal forearm in Oslo, Norway. *Acta Orthop Scand* 1983; 54 (2): 291-5.
- Gartland J J, Werley C W. Evaluation of healed Colles' fractures. *J Bone Joint Surg (Am)* 1951; 33 (4): 895-907.
- Knirk J L, Jupiter J B. Intra-articular fractures of the distal end of the radius in young adults. *J Bone Joint Surg (Am)* 1986; 68 (5): 647-59.
- Smaill G B. Long term follow up of Colles' fracture. *J Bone Joint Surg (Br)* 1965; 47 (1): 80-5.
- Solgaard S, Petersen V S. Epidemiology of distal radius fractures. *Acta Orthop Scand* 1985; 56 (5): 391-3.
- van der Linden W, Ericson R. Colles' fracture. How should its displacement be measured and how should it be immobilized? *J Bone Joint Surg (Am)* 1981; 63 (8): 1285-8.