

# Staple fixation of osteotomy for cubitus varus

## A simple technique used in 11 children

Lars G. Danielsson<sup>1,2</sup>, Shaban Hussein<sup>1</sup>, Izzedin El-Haddad<sup>1</sup> and Rajendra P. Gupta<sup>1</sup>

Eleven children with a persistent varus deformity of 15° or more were operated on with a supracondylar lateral closing-wedge osteotomy. The osteotomy was stabilized with a staple after predrilling for the

legs of the staple. No displacement occurred in the osteotomy. The results were excellent in all the cases.

<sup>1</sup>Orthopedic Unit, Department of Surgery, Faculty of Medicine, Kuwait University, Kuwait, and

<sup>2</sup>Lund University Department of Orthopedics, Malmö General Hospital, S-214 01 Malmö, Sweden

Several methods of corrective osteotomy of the distal humerus have been described (Bellemore et al. 1984, DeRosa and Graziano 1988, Kanaujia et al. 1988). In many reported series, the complication rate was high (Bellemore et al. 1984).

Because of our previous experience with displacement in the osteotomy when using pins or wires for fixation, we changed our technique in 1981 and used a staple for fixation after predrilling for the legs of the staple.

### Patients and methods

Eleven patients (7 boys and 4 girls) were operated on for a persistent varus deformity secondary to the supracondylar or intracondylar Y-fracture of the humerus. The age at injury was 7 (3-12) years and at surgery 11 (5-17) years. The interval between fracture and osteotomy was 1-9 years. The preoperative complaints were more or less exclusively cosmetic.

The humeral-elbow-wrist angle was measured clinically with the elbow in full extension and supination. The preoperative varus deformity was 23° (16°-30°; Table 1).

Using a tourniquet, a 6-8-cm incision was made over the lateral epicondyle and the lateral intermuscular septum of the humerus. After subperiosteal dissection, the extensor and brachioradialis muscles were displaced anteriorly and the triceps muscle was displaced posteriorly. The supracondylar region was dissected free subperiosteally around the entire circumference of the humerus. The ulnar nerve was in 1 case (Case 7) explored through a small ulnar incision, because it was difficult to identify the nerve at the clinical examination. In all the other

cases the ulnar nerve was not explored. Using an oscillating saw, a supracondylar triangular wedge was then removed (Figure 1). The level and the angle of the osteotomy were determined by peroperative fluoroscopy. The angle of the wedge was preoperatively calculated after comparing the angle of the deformed elbow with the normal side. The goal was to obtain at least a straight elbow or a slight valgus angle not exceeding the valgus angle of the normal side. The distal osteotomy was cut parallel to the physis and extended medially just to the superior limit of the medial condyle. The proximal osteotomy was angulated proximally-radially and joined the distal osteotomy on the ulnar side. A medial cortical

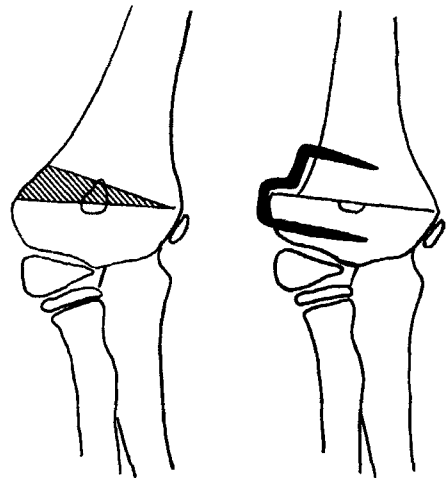


Figure 1. Subperiosteal supracondylar lateral closing-wedge osteotomy with preservation of a medial cortical hinge fixed with a step-shaped staple after predrilling for the legs.

Table 1. Clinical data for 11 patients with cubitus varus corrected with a supracondylar lateral closing-wedge osteotomy

| Case | Side | Sex | Age at |           | Carrying angle |               | Range of motion |         | Duration of postop follow-up (mo) |
|------|------|-----|--------|-----------|----------------|---------------|-----------------|---------|-----------------------------------|
|      |      |     | injury | osteotomy | preop varus    | postop valgus | preop           | postop  |                                   |
| 1    | L    | M   | 8      | 10        | 18             | 5 (7)         | 10-135          | 0-135   | 12                                |
| 2    | R    | M   | 9      | 11        | 24             | 3 (5)         | 10-120          | 0-135   | 7                                 |
| 3    | L    | F   | 4      | 6         | 26             | 4 (4)         | 5-130           | 0-130   | 12                                |
| 4    | L    | F   | 5      | 9         | 29             | 0 (4)         | 5-140           | 0-135   | 13                                |
| 5    | L    | M   | 10     | 13        | 30             | 0 (5)         | 0-125           | 0-135   | 14                                |
| 6    | L    | M   | 7      | 16        | 26             | 0 (5)         | 15-110          | 0-125   | 6                                 |
| 7    | R    | M   | 8      | 17        | 25             | 5 (5)         | 5-125           | 0-145   | 10                                |
| 8    | L    | F   | 3      | 5         | 21             | 5 (5)         | 5-135           | 0-135   | 20                                |
| 9    | L    | M   | 7      | 8         | 24             | 4 (6)         | 0-100           | -10-120 | 19                                |
| 10   | R    | M   | 6      | 7         | 16             | 6 (7)         | 10-125          | -10-135 | 96                                |
| 11   | R    | F   | 12     | 14        | 19             | 2 (6)         | 0-125           | 0-130   | 8                                 |

( ) Contralateral normal side.

hinge was preserved to allow control of the osteotomy fragments. The last 2-3 mm of bone were cracked by forcing the arm into valgus. The aim was to get the proximal osteotomy line as long as possible to prevent or minimize the step between the two fragments. If such a lateral step occurred, a step-shaped staple was used. The osteotomy was closed, and the fragments were stabilized using a staple after predrilling for the legs of the staple (Figure 2).

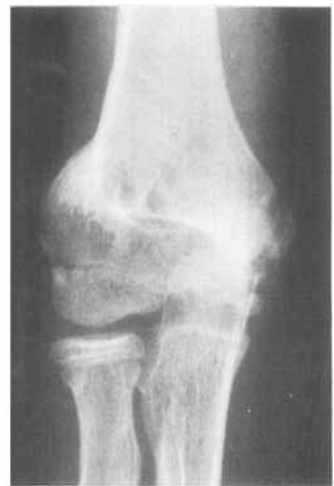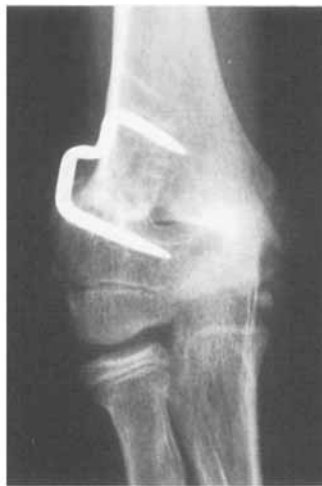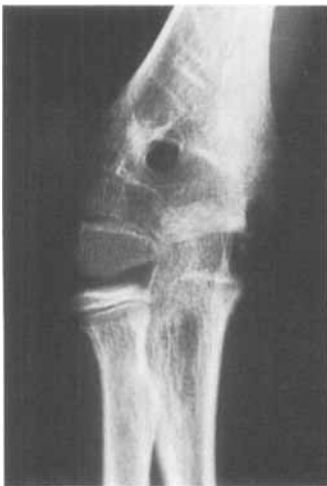The elbow was immobilized in a plaster of Paris cast for 3-5 weeks. The staples were removed after 11 (7-46) weeks.

The patients were followed for at least 6 months.

## Results

There were no surgical complications. Postoperatively, the Wiberg staple used in Case 1 had slid out 2 mm already in the plaster of Paris cast, but no displacement in the osteotomy occurred—neither before nor after the removal of the cast. In the other cases, there was no displacement of the staple or of the osteotomy; and there were no other complications.

At reexamination, all the patients were satisfied with the results. The varus deformity had been corrected 27° (21°-30°) to a valgus angle of 3° (0°-6°). The corresponding figure for the normal side was 5°



Before surgery.

Immediately after surgery.

Seven months after surgery. The cortical step has filled out with new bone.

Figure 2. Case 2.

(4°-7°). The osteotomized elbow was never in more valgus than the normal side. The range of motion was unchanged or improved in all the cases. Extension-flexion increased by 16° (0°-30°).

## Discussion

Several types of osteotomies have been advocated, such as lateral closing wedge (Langenskiöld and Kivilaakso 1967, Carlson and Rosman 1982), medial opening wedge (King and Secor 1951), or dome osteotomy (Kanaujia et al. 1988). Kanaujia et al. (1988) tried, if it was deemed necessary, to correct some rotational deformity, whereas most other authors feel that a rotational deformity is difficult to correct in the very thin supracondylar region and that the rotational component is of no consequence, and thus should be ignored (Carlson and Rosman 1982, Bellemore et al. 1984, Oppenheim et al. 1984).

Different methods of stabilizing the osteotomy have been described, such as screws joined by wire (French 1959), plate and screws (Langenskiöld and Kivilaakso 1967, Oppenheim et al. 1984), Kirschner wires (Bellemore et al. 1984, Kanaujia et al. 1988), screw (DeRosa and Graziano 1988, Laupattarakasem et al. 1989), and a staple (Carlson and Rosman 1982). Some of the techniques described are technically difficult; and several complications including loss of fixation, infection, neuropraxia, and cosmetically unacceptable scars have occurred (Rang 1974, Oppenheim et al. 1984).

The method used in our material—with a lateral wedge after careful preoperative planning, "green-sticking" of the medial cortex, and fixation with a staple after predrilling—gave excellent results in all the cases. The simple method probably favored the results more than the fact that all the operations were performed by the same surgeon. The Wiberg staple, used in 1 case, was not optimal; but the

Blount staples provided very good stability. Surprisingly, the range of motion in the elbow improved after osteotomy.

Carlson and Rosman (1982) used a barbed staple; but besides this, the two procedures were identical, and so were the results.

From the case records, no significant spontaneous improvement of the deformity occurred during growth. Because of this, our present policy is to operate as soon as no further improvement of elbow motion occurs, which means about 1 year after injury.

## References

- Bellemore M C, Barrett I R, Middleton R W, Scougall J S, Whiteway D W. Supracondylar osteotomy of the humerus for correction of cubitus varus. *J Bone Joint Surg (Br)* 1984; 66 (4): 566-72.
- Carlson C S Jr, Rosman M A. Cubitus varus: a new and simple technique for correction. *J Pediatr Orthop* 1982; 2 (2): 199-201.
- DeRosa G P, Graziano G P. A new osteotomy for cubitus varus. *Clin Orthop* 1988; 236: 160-5.
- French P R. Varus deformity of the elbow following supracondylar fractures of the humerus in children. *Lancet* 1959; II: 439-41.
- Kanaujia R R, Ikuta Y, Muneshige H, Higaki T, Shimogaki K. Dome osteotomy for cubitus varus in children. *Acta Orthop Scand* 1988; 59 (3): 314-7.
- King D, Secor C. Bow elbow (cubitus varus). *J Bone Joint Surg (Am)* 1951; 33: 572-6.
- Langenskiöld A, Kivilaakso R. Varus and valgus deformity of the elbow following supracondylar fracture of the humerus. *Acta Orthop Scand* 1967; 38: 313-20.
- Laupattarakasem W, Mahaisavariya B, Kowsuwon W, Saengnipanthkul S. Pentalateral osteotomy for cubitus varus. Clinical experiences of a new technique. *J Bone Joint Surg (Br)* 1989; 71 (4): 667-70.
- Oppenheim W L, Clader T J, Smith C, Bayer M. Supracondylar humeral osteotomy for traumatic childhood cubitus varus deformity. *Clin Orthop* 1984; 188: 34-9.
- Rang M. *Children's fractures*. J B Lippincott Co, Philadelphia 1974.