

Prognosis in postoperative discitis, A retrospective study of 111 cases

Elsebeth Iversen, Vivi Ann Herss Nielsen and Lena Gadegaard Hansen

111 cases of postoperative discitis during 1968–1986 were analyzed retrospectively. The diagnosis was confirmed by lumbar tomography. Low back pain appeared at an average of 16 days postoperatively. Laboratory findings were of minor value in the diagnosis since elevated ESR, white blood cell count, and body temperature were inconstant findings.

Compared with a matched control group, there was a higher incidence of chronic low back pain and vocational handicap in the discitis patients. There was no difference in the consumption of analgetics, the subjective evaluation of the final outcome, spinal mobility or neurologic findings.

University of Copenhagen, Department of Radiology, Glostrup Hospital, DK-2600 Glostrup, Denmark
Correspondence: Dr. E. Iversen, Bag Søndermarken 21, 4 DK-2000 Frederiksberg, Denmark
Tel +45-36 306328. Fax +45-36 309670
Submitted 90-10-20. Accepted 92-02-03

Postoperative discitis following lumbar disc surgery was first described by Giesekeing (1951). The incidence varies from 0.2 percent (Brussatis 1953) to 4 percent (Nielsen 1987). The radiographic findings are characteristic, with blurring of the endplate of the vertebral body, cavitations, narrowing of the disc space and subsequently healing with new bone formation, fusion or bony bridging (Lowman and Robinson 1966, Puranen et al. 1984, Nielsen et al. 1990).

We have retrospectively studied the postoperative course and long-term prognosis in 111 patients with radiographically verified discitis following lumbar disc surgery and compared it with a matched control group.

Patients and methods

209 patients referred to our hospital for lateral lumbar tomography because of clinically suspected postoperative discitis during the period January 1968 through July 1986 were studied retrospectively. Patients with characteristic radiographic lesions were included; the diagnosis had to be confirmed by at least two consecutive examinations. Patients who were dead at the time of follow-up were excluded leaving a total of 128 patients. The records were studied with reference to preoperative symptoms, level and method of surgery and postoperative course including symptoms of discitis, laboratory findings, and postoperative treat-

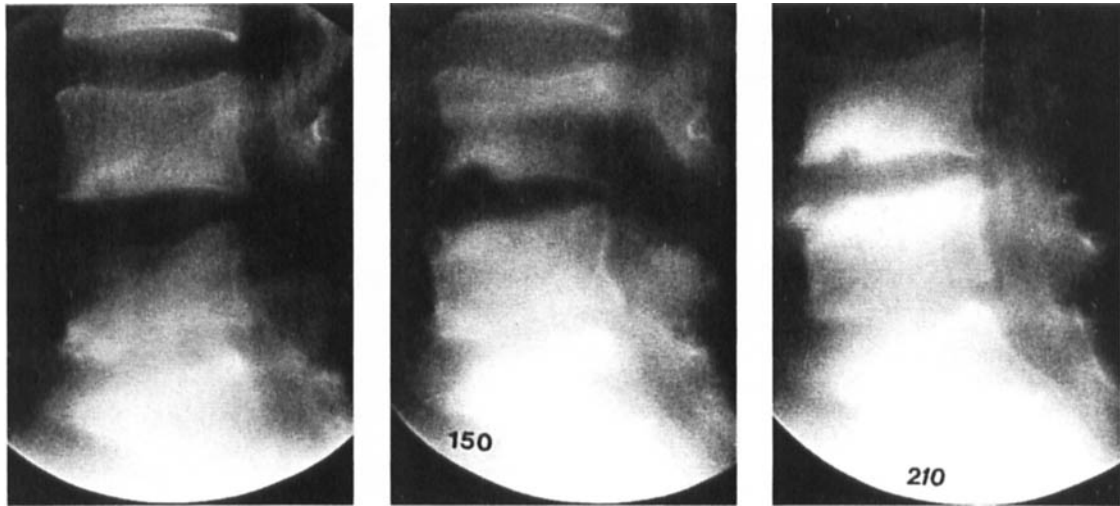
ment. 111 out of 128 patients answered a questionnaire concerning postoperative treatment, duration of symptoms and sick leave. There were 53 men and 58 women. The mean age at surgery was 44 (26–71) years. Patients living in the county (n 81) were asked to participate in a clinical follow-up, 53 accepted. The mean follow-up time was 13 (1–22) years. A control group consisting of 52 patients, matched for age, sex and time of operation, was selected. 34 of those patients participated in the clinical follow-up. The commonest type of surgery was hemilaminectomy with removal of disc prolapse; this was performed in 96 patients in the discitis group and 47 in the control group.

In the clinical follow-up examination, spinal mobility and neurology were evaluated and a plain lumbar radiogram was obtained. In both groups of patients, approximately one third refrained from participating. There was no statistical difference between them with regard to age, subjective evaluation of low back pain or sciatica or duration of symptoms.

The Mann–Whitney test and the chi-square test were used in the statistical analyses.

Results

There was a higher incidence of herniation at the L 4/5 level in the discitis group as compared with the control group (Table 1).



Minor destruction in the inferior margin of L4 (90 days after operation).

Maximal lesion in L4 with early signs of healing and anterior destructions in L5 (150 days after operation).

Diminishing cavitation in L4 with pronounced sclerosis in the margin and progressive destruction of L5 (210 days after operation).

Figure 1. A 57-year-old man, operated on at level L4/L5 developed severe low back pain 6 weeks postoperatively. At follow-up examination 11 years later, the patient still suffered from persistent low back pain.

Table 1. Operation level

	Discitis group	Control group
L3/L4	9	4
L4/L5	63	19
L5/S1	28	26
Operated on at more than one level	11	3
Total	111	52

$P < 0.05$, chi-square test

Table 2. Level of discitis in relation to operation level

	Operated on at one level	Operated on at more than one level
At operated level	85	11
At nonoperated level	13	0
At both levels	2	0
Total	100	11

Postoperative course

Clinical symptoms of discitis appeared on an average of 16 (0-90) days postoperatively. Pain, localized to the low back, gluteal region and/or lower extremities, was present in all 111 patients. 87 of these complained of constant low back pain. Half of them had intermittent pain of shooting character, 58 had radicular pain, in 11 cases bilateral. 8 patients had radicular pain in the contralateral leg as compared to preoperative symptoms. Pain was aggravated by movement in 100 patients. 6 patients had postoperative wound infection, all in the discitis group. A needle biopsy from the affected disc was performed in two cases, cultures revealed *Staphylococcus aureus*. Laboratory findings were not available in all records. Mean maximal ESR

(29 patients) was 64 (22-118) mm/h and in 21 of these patients ESR was 50 mm/h or higher. ESR was elevated for an average of 2.9 months and highest at an average of 31 days after operation. In another 13 patients, the mean maximal ESR was 70 (32-131) mm/h during the first two postoperative weeks, but it normalized within this period. In 21 patients, the ESR was normal. The white blood cell count was recorded in 87 out of 111 patients with discitis and was elevated in 16 patients. A body temperature above 37.5 °C was found in 38 patients; mean 38.0 (37.8-40.0) °C.

In lateral tomograms characteristic lesions (Figure 1) were found at an average of 2 (0.3-10) months postoperatively. The level of discitis in relation to the level of operation is listed in Table 2.

Table 3. Low back pain at the follow-up examination

	Discitis group	Control group
None	16	14
Periodically	48	24
Constantly	47	14
Total	111	52

 $P < 0.01$

Table 5. Subjective evaluation of pain in patients still suffering from low back pain

	Discitis group	Control group
Insignificant pain	4	1
Moderate pain	39	24
Disabling pain, unable to work	52	13
Total	95	38

 $P > 0.05$

Treatment

106 of the 111 patients with discitis were immobilized in bed. None of the patients from the control group were bedridden postoperatively during their hospital stay, but 6 patients had to stay in bed at home for a short period due to low back pain. 59 discitis patients and 6 patients in the control group were immobilized in a brace.

Weak analgetics were administered to 92 discitis patients, morphine to 50 patients and muscle relaxants to 24 patients. Local injection of anesthetics was tried in 60 patients. 12 patients in the discitis group received antibiotics. As judged by the patients, none of the above-mentioned forms of treatment had a striking effect. Sick leave was longer in the discitis group; mean 9 (0.5-48) months. 54 out of 111 discitis patients had a sick leave of more than one year.

Follow-up

At follow-up there were 95 out of 111 patients in the discitis group with low back pain as compared to 38 out of 52 in the control group (Table 3). Consumption of analgetics in the two groups is listed in Table 4. There was no difference between the two groups in the evaluation of low back pain severity (Table 5). Sleep-distressing pain was present in 49 out of 111 patients

Table 4. Current consumption of analgetics

	Discitis group	Control group
None	18	15
Periodic use of weak analgetics	16	12
Daily use of weak analgetics	13	7
Daily use of opiates	6	0
Total	53	34

 $P > 0.1$

Table 6. Change of work postoperatively because of low back pain

	Discitis group	Control group
No change	59	38
Temporary	5	1
Permanent	13	13
Disability pension	34	0
Total	111	52

 $P < 0.05$

in the discitis group and 19 out of 52 in the control group ($P > 0.10$, NS). Sciatica was more common in the discitis group ($P < 0.004$).

Preoperatively, 10 out of 111 patients in the discitis group and 9 out of 52 in the control group received a disability pension. In addition, another 34 patients in the discitis group received a disability pension postoperatively whereas all patients in the control group, working preoperatively, returned to work (Table 6). There was a significant decline in the economic standard of living according to the patients' judgment in the discitis group as compared with the control group ($P < 0.05$) postoperatively.

There was no difference in the appreciation of the patients in the two groups regarding a possible improvement in low back pain (Table 7).

Table 7. The patients' evaluation of the condition at the time of follow-up investigation compared with the preoperative condition

	Discitis group	Control group
Better	68	40
Unchanged	25	11
Worse	18	1
Total	111	52

 $P = 0.06$

Clinical examination regarding sensory or motor neurological findings showed no difference in the two groups, nor was there any difference in spinal mobility.

In plain lumbar radiographs, we found a substantial difference between the two groups with regard to degeneration of the intervertebral disc space, intercorporeal fusion and major osteophytes. In the discitis group, a decreased disc height was present in all cases, while intercorporeal fusion and major osteophytes were found in 9 and 21 patients, respectively. In the control group, decreased disc height was present in 12 patients. $P < 0.001$ in all findings.

Discussion

Several studies favor the occurrence of direct inoculation as the causative factor of postoperative discitis and needle biopsy or aspiration from discs have revealed a positive bacteriological diagnosis in 44 percent (Brussatis 1953, Turnbull 1953, Ford and Key 1955, Sullivan et al. 1958, Stern and Crandall 1959, Lang 1968, Thibodeau 1968, El-Gindi et al. 1976, Lester et al. 1978, Taylor and Dooley 1978, Twerdy 1978, Rawlings et al. 1983, Fernand and Lee 1986, Dall et al. 1987, Bircher et al. 1988). *Staphylococcus aureus* is the most common organism (62 percent), but other organisms, such as *Staphylococcus epidermidis*, *E. coli* and *diphtheroids*, have also been cultured (Lang 1968, El-Gindi et al. 1976, Rawlings et al. 1983, Dall et al. 1987, Bircher et al. 1988). Negative cultures do not, however, rule out a bacterial origin (Fraser et al. 1987). Many organisms cultured from discitis may be slowgrowing and low-virulent (Schoferman et al. 1989).

Another causative factor could be an infection following aseptic necrosis, possibly caused by traumatization of the disc during operation or by vascular disturbances (Stern and Crandall 1959, Reichenbach 1971, Twerdy 1978, Lindholm and Pylkkänen 1982). We found 15 cases of discitis at a nonoperated level which suggests a hematogenous spread of bacteria (Stern and Crandall 1959). We found a higher incidence of discitis at the L4/5 level as did Nielsen (1987) and Zink et al. (1989).

The cardinal symptom of postoperative discitis is low back pain occurring 0-8 weeks postoperatively (Thibodeau 1968, Lester et al. 1978, Twerdy 1978, Puranen et al. 1984). Pain is aggravated by movement (Sullivan et al. 1958, Lang 1968, Lester et al. 1978, Puranen et al. 1984). Referral of pain into the groin, testes or lower abdominal quadrant has been described (Brussatis 1953, Sullivan et al. 1958, Stern and

Crandall 1959, Pilgaard 1969, Reichenbach 1971). Pain in the lower extremity may be present but true sciatica is not common (Sullivan et al. 1958, Stern and Crandall 1959).

Most authors state that the only laboratory test of importance in indicating discitis is the ESR (Sullivan et al. 1958, Lang 1968, Thibodeau 1968), but a few cases with a normal ESR have been reported (Stern and Crandall 1959, Lester et al. 1978, Dall et al. 1987). We found an elevated ESR more than two weeks postoperatively in 29 out of 50 patients.

Computed tomography is nonspecific and insufficient to make the diagnosis (Dall et al. 1987, Frank and Trappe 1988, Ilkko et al. 1988), and so is scintigraphy (Frank and Trappe 1988). The diagnosis can be established by lumbar tomography, that may, however, be normal for weeks or even months. Magnetic resonance imaging is a superior method for diagnosing discitis (Modic et al. 1984, Modic et al. 1985).

Current treatment consists of bed-rest long enough to provide pain relief and antibiotics until the ESR is normal (Thibodeau 1968, Rawlings et al. 1983, Dall et al. 1987, Frank and Trappe 1988). In the absence of a bacteriological diagnosis a broadspectrum antibiotic treatment with gram-positive cocci coverage should be administered (Sullivan et al. 1958, Thibodeau 1968, Taylor and Dooley 1978, Rawlings et al. 1983, Dall et al. 1987).

Reports on the long-term prognosis in postoperative discitis vary. Some authors reported a slight back pain in almost all patients (Spangfort 1964, Dall et al. 1987) while others reported that more than 60 percent were completely free from pain at follow-up (Lester et al. 1978). On the other hand, Lindholm and Pylkkänen (1982) reported severe chronic back pain in 75 percent of the patients at follow-up.

In general, after disc surgery 50-88 percent of patients are completely free of pain (Weber 1983, Yde et al. 1984, Hurme 1985).

The majority of the discitis patients (67-88 percent) returned to their previous work, 12-25 percent received a disability pension postoperatively (Lester et al. 1978, Puranen et al. 1984, Nielsen 1987). These numbers are similar to those for disc surgery in general (Kirchheiner 1968, Yde et al. 1984, Hurme 1985). In Lindholm and Pylkkänen's study (1982) of discitis patients, however, 55 percent received a disability pension postoperatively, and only 18 percent resumed their previous work, while 27 percent returned to less strenuous work.

We found a substantial difference between the discitis group and the control group with regards to cumulated periods of low back pain, the presence of pain at the time of follow-up and inability to work. In spite of this, there was no difference between the two

groups with regard to the severity of pain when present, or in the consumption of analgetics. The duration of postoperative sick leave was prolonged in the discitis group, and the long-term prognosis was worse with greater risk of chronic low back pain and a vocational handicap, as compared to a control group.

References

- Bircher M D, Tasker T, Crawshaw C, Mulholland R C. Discitis following lumbar surgery. *Spine* 1988; 13 (1): 98-102.
- Brussatis F. Osteomyelitis nach Operation lumbaler Diskushernien. *Acta Neurochir* 1953; 3: 209-23.
- Dall B E, Rowe D E, Odette W G, Batts D H. Postoperative discitis. Diagnosis and management. *Clin Orthop* 1987; 224: 138-46.
- El-Gindi S, Aref S, Salama M, Andrew J. Infection of intervertebral discs after operation. *J Bone Joint Surg (Br)* 1976; 58 (1): 114-6.
- Fernand R, Lee C K. Postlaminectomy disc space infection. A review of the literature and a report of three cases. *Clin Orthop* 1986; 209: 215-8.
- Ford L T, Key J A. Postoperative infection of intervertebral disc space. *South Med J* 1955; 48: 1295-303.
- Fraser R D, Osti O L, Vernon-Roberts B. Discitis after discectomy. *J Bone Joint Surg (Br)* 1987; 69 (1): 26-35.
- Frank A M, Trappe A E. Die Spondylodisitis nach lumbaler Bandscheibenoperation. *Klinik Diagnostik Therapie. Neurochirurgia (Stuttg)* 1988; 31 (6): 205-9.
- Gieseking H. Lokalisierte Spondylitis nach operiertem Bandscheibenvorfall. *Zentralbl Chir* 1951; 21: 1470-7.
- Hurme M. Factors predicting the result of surgery for lumbar intervertebral disc herniation. *Publ Social Insurance Inst Finland* 1985, Ser: AL, P. 135-9.
- Ilkko E, Lahde S, Koivukangas J, Jalovaara P. Computed tomography after lumbar disc surgery. *Acta Radiol* 1988; 29 (2): 179-82.
- Kirchheiner B. Resultat af operativ behandling af lumbal discusprolaps. *Ugeskr Laeger* 1968; 131 (41): 1737-40.
- Lang E F. Postoperative infection of the intervertebral disc space. *Surg Clin North Am* 1968; 48 (3): 649-60.
- Lester J, Gylding Sabroe J, Jacobsen L, Ronde F. Lumbar discitis efter prolapsoperation. *Ugeskr Laeger* 1978; 140 (20): 1155-8.
- Lindholm T S, Pylkkänen P. Discitis following removal of intervertebral disc. *Spine* 1982; 7 (6): 618-22.
- Lowman R M, Robinson F. Progressive vertebral interspace changes following lumbar disk surgery. *Am J Roentgenol Radium Ther Nucl Med* 1966; 97 (3): 664-71.
- Modic M T, Pavlicek W, Weinstein M A, Bouthphey F, Ngo F, Hardy R, Duchesneau P M. Magnetic resonance imaging of intervertebral disk disease. Clinical and pulse sequence considerations. *Radiology* 1984; 152 (1): 103-11.
- Modic M T, Feiglin D H, Piraino D W, Bouthphey F, Weinstein M A, Duchesneau P M, Rehm S. Vertebral osteomyelitis: assessment using MR. *Radiology* 1985; 157 (1): 157-66.
- Nielsen A N. Postoperativ lumbal discitis efter prolapsoperation. *Ugeskr Læger* 1987; 149: 714-6.
- Nielsen V A, Iversen E, Ahlgren P. Postoperative discitis. Radiology of progress and healing. *Acta Radiol* 1990; 31 (6): 559-63.
- Pilgaard S. Discitis (closed space infection) following removal of lumbar intervertebral disc. *J Bone Joint Surg (Am)* 1969; 51 (4): 713-6.
- Puranen J, Mäkelä J, Lähde S. Postoperative intervertebral discitis. *Acta Orthop Scand* 1984; 55 (4): 461-5.
- Rawlings C E, Wilkins R H, Gallis H A, Goldner J L, Francis R. Postoperative intervertebral disc space infection. *Neurosurgery* 1983; 13 (4): 371-6.
- Reichenbach W. Aseptische Wirbelnekrosen nach Operationen lumbaler Diskushernien. *Schweiz Arch Neurol Neurochir Psychiatr* 1971; 108 (1): 61-74.
- Schofferman L, Schofferman J, Zucherman J, Gunthorpe H, Hsu K, Picetti G, Goldthwaite N, White A. Occult infections causing persistent low back pain. *Spine* 1989; 14 (4): 417-9.
- Spangfort E. Postoperativ discitis. *Nord Med* 1964; 71: 162.
- Stern W E, Crandall P H. Inflammatory ontervertebral disc disease as a complication of the operative treatment of lumbar herniations. *J Neurosurg* 1959; 16: 261-76.
- Sullivan C R, Bickel W H, Svien H J. Infections of vertebral interspaces after operations in intervertebral disks. *JAMA* 1958; 166: 1973-7.
- Taylor T K, Dooley B J. Antibiotics in the management of postoperative disc space infections. *Aust N Z J Surg* 1978; 48 (1): 74-7.
- Thibodeau A A. Closed space infection following removal of lumbar intervertebral disc. *J Bone Joint Surg (Am)* 1968; 50 (2): 400-10.
- Tumbull F. Postoperative inflammatory disease of lumbar discs. *J Neurosurg* 1953; 10: 469-73.
- Twerdy K. Die Spondylo Discitis nach Bandscheibenoperationen. *Zentralbl Neurochir* 1978; 39 (2): 155-76.
- Weber H. Lumbar disc herniation. A controlled, prospective study with ten years of observation. *Spine* 1983; 8 (2): 131-40.
- Yde J, Andersen H J, Emneus H. Efterundersøgelse af subjektive og sociale sequelae efter operation for lumbal discusprolaps (In Danish). *Nord Med* 1984; 99 (8-9): 213-5.
- Zink P M, Frank A M, Trappe A E. Prophylaxis of postoperative lumbar spondylodisitis. *Neurosurg Rev* 1989; 12 (4): 297-303.