Acta Orthop Scand 1992; 63 (1): 104–105

Simultaneous occurrence of trapezium-scaphoid-trapezoid dislocation and multiple carpo-metacarpal fracture dislocations

A case report

Morten B. Petersen, Poul T. Nielsen and Lone S. Nielsen

We report a case of simultaneous trapezioscaphoid luxation and fracture-dislocation of the three ulnar metacarpals that illustrates the difficulty in the detection of fractures and dislocations in the carpal bones.

Departments of Orthopedics and Radiology, Centralsygehuset Hillerød, DK-3400 Hillerød, Denmark
Correspondence: Dr. Morten Boye Petersen, Irisvej 3, DK-2970 Hørsholm, Denmark
Submitted 90-02-02. Accepted 91-08-23

Case report

A 22-year-old man was admitted to our casualty department after a motorcycle accident. He had sustained a comminuted dislocated supracondylar fracture of the left humerus, and his right hand and wrist were swollen and painful. Radiographs of the hand were inconclusive, but dislocation of the carpal bones was suspected (Figure 1). The hand and wrist were examined under fluoroscopy, which revealed a dorsoradial dislocation of the trapezium from the scaphoid and trapezoid. The first metacarpal bone and the carpometacarpal joint were without lesions. The luxation was reduced closed, and percutaneous Kirschner wires were used for fixation. Postoperative radiographs suggested further carpal dislocation, so supplementary tomography of the wrist was performed. This revealed a dorsal metacarpal dislocation of the III, IV, and V metacarpals, combined with fracture of the dorsal parts of the capitate and hamate bones.

At operation, rupture of the ulnar dorsal carpometacarpal ligament complex was revealed. The fracture-dislocations were reduced and transfixed with Kirschner wires and a AO screw.

Five months after the operation, the patient had regained good function in his right hand, with a normal painless range of movement of all the digits and only slight impairment of the wrist.

Discussion

Simultaneous multiple carpometacarpal fracture-dislocations and dislocations of the trapezium are rare (Henderson and Arafa 1987, Holdsworth and Shackleford 1987, Sherlock 1987). Dorsal luxation of the metacarpals is thought to be due to a longitudinal force along the metacarpal shafts or to a force applied directly to the carpometacarpal joints (Hartwig et al. 1979, Mueller 1986, de Beer et al. 1989). The base of the second and the third metacarpal both have multiple articular facets that are firmly attached to the carpus by strong ligaments; this means that a far greater force is required to produce dislocation (Mueller 1986). Carpometacarpal dislocations are normally associated with fracture of the base of the metacarpals (Hartwig et al. 1979); but in our case, the hamate and capitate bones were fractured.

Treatment of carpometacarpal dislocations by closed reduction is performed by longitudinal traction to the base of the metacarpals (Hartwig et al. 1979); but open reduction is often required, especially if the dislocations are more than 10 days old.

Transfixation with Kirschner wires is recommended for unstable fractures (Hartwig et al. 1979, Mueller 1986, de Beer et al. 1989). Immobilization should be continued for 4–6 weeks postoperatively (Hartwig et al. 1979, Mueller 1986, de Beer et al. 1989). Dislocations of the trapezium are normally difficult to reduce closed (Holdsworth and Shackleford 1987); but in our case, a firm pull on the thumb with simultaneous ulnar deviation and extension of the wrist reduced the dislocation.

Plain radiograph of the right hand at admittance.

Tomography. AP view. Note the absence of the three ulnar carpometacarpal joint spaces.

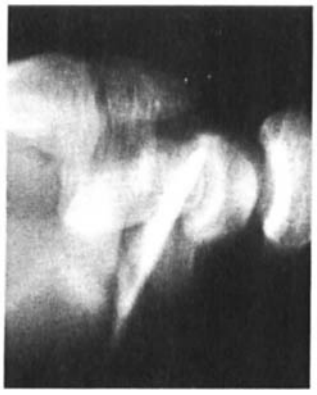

Lateral view showing a fracture in the hamate bone with dorsal dislocation of the metacarpals.

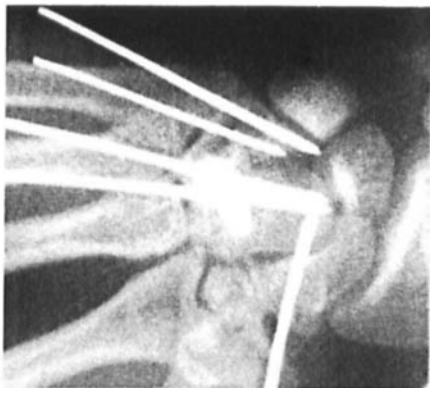

Peroperative radiograph after reduction and pinning with Kirschner wires. The carpometacarpal joint spaces are now visible.

Figure 1.

References

de Beer J D, Maloon S, Anderson P, Jones G, Singer M. Multiple carpo-metacarpal dislocations. *J Hand Surg* (Br) 1989; 14 (1): 105–8.

Gilula L A. Carpal injuries: analytic approach and case exercises. Am J Roentgenol 1979; 133 (3): 503–17.

Hartwig R H, Louis D S. Multiple carpometacarpal dislocations. A review of four cases. *J Bone Joint Surg* (Am) 1979; 61 (6): 906–8.

Henderson J J, Arafa M A. Carpometacarpal dislocation. An easily missed diagnosis. *J Bone Joint Surg* (Br) 1987; 69 (2): 212–4.

Holdsworth B J, Shackleford I. Fracture dislocation of the trapezio-scaphoid joint the missing link?. *J Hand Surg* (Br) 1987; 12 (1): 40–2.

Mueller J J. Carpometacarpal dislocations: report of five cases and review of the literature. *J Hand Surg* (Am) 1986; 11 (2): 184–8.

Sherlock D A. Traumatic dorsoradial dislocation of the trapezium. *J Hand Surg* (Am) 1987; 12 (2): 262–5.