

Osteochondral lesions and cruciate ligament injuries

MRI in 18 knees

Lars Engebretsen¹, Elizabeth Arendt¹ and Hollis M Fritts²

Magnetic resonance images were obtained prior to arthroscopy and surgery in 18 knees with acute anterior cruciate ligament injury. The incidence of osseous lesions was assessed and the findings were

compared with those at arthroscopy. A total of 28 osseous lesions were detected by MRI in 15 knees, but none of these were detected by radiographs or arthroscopy.

¹Department of Orthopedics, University of Minnesota, Minneapolis MN, and ²Center for Diagnostic Imaging, St. Louis Park, MN, U.S.A. Correspondence: Dr. Lars Engebretsen, Department of Orthopedics, University of Minnesota, Mayo Building, 420 Delaware Street, S.E., Minneapolis, MN 55455, U.S.A. Tel +1-612 625 1177. Fax -612 626 6032
Submitted 92-08-29. Accepted 93-01-24

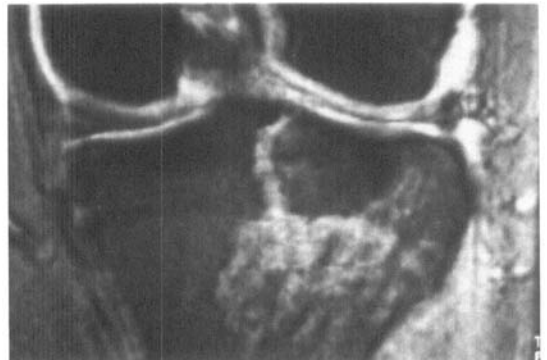
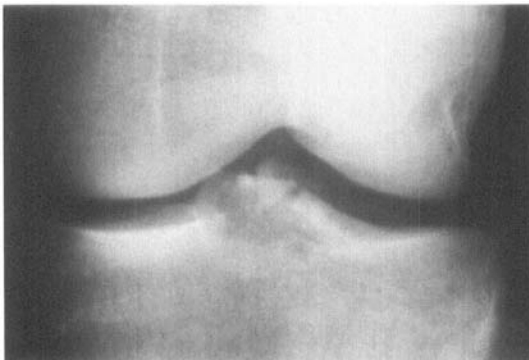
Recent studies using magnetic resonance imaging technique (MRI) have shown a high frequency of subcortical and osteochondral lesions although the radiographs were normal (Rosen et al. 1991, Vellet et al. 1991). We report the frequency of osseous lesions according to MRI correlated with the arthroscopic findings in patients with acute anterior cruciate ligament injuries.

Patients and methods

During the period from August 1990 to May 1991, 49 patients were operated for an acute rupture of the ante-

rior cruciate ligament. In 18 patients with either a locked knee or an extension deficit, MRI was obtained before the operation to rule out a reparable meniscal injury. T1- and T2-weighted images were used in the coronal and sagittal planes. The MRI was read by an experienced radiologist (HF), and the readings were known to the 2 arthroscopists (LE, EA) before surgery. The cartilage surface immediately subjacent to the documented site of osteochondral injury was evaluated in particular. Radiographic evaluations of these knees did not show bony alterations, with the exception of 1 patient who had sustained an anterior cruciate ligament bony avulsion from the tibial plateau (Figure 1).

Figure 1. Case 9. A 20-year-old woman who sustained tibial avulsion of the anterior cruciate ligament while playing soccer.



T2 MRI. Note the large tibial osseous lesions, as shown by an increase in the T2 signal.

Table 1. Observations in 18 patients with acute anterior cruciate ligament injury

A	B	C	D	E	F	G	H	I	J	K	L	M	N	O
1	F	16	1	0	3	3	2	1	0	0	2	1	0	2
2	F	20	4	0	2	2	2	1	0	1	2	1	0	1
3	M	26	1	0	2	3	2	0	1	0	1	0	1	0
4	F	22	1	0	3	3	2	0	0	0	2	0	0	1
5	F	19	3	0	2	2	2	1	0	0	2	0	1	1+2+5
6	M	57	6	0	2	3	2	1	1	0	2	1	1	0
7	M	21	1	0	3	2	2	0	1	0	2	0	1	1+2
8	M	20	1	0	2	2	2	1	1	0	2	1	1	1
9	F	22	5	1	2	0	3	0	1	5	2*	0	0	2+4+5
10	F	20	4	0	3	2	2	1	0	0	2	1	0	1+2
11	F	44	4	0	2	2	2	1	0	0	2	1	0	1+2
12	M	22	1	0	3	2	2	1	0	0	2	1	0	1+2
13	F	31	7	0	3	3	2	1	0	0	2	1	1	1+2
14	M	22	1	0	3	3	2	0	0	0	2	0	0	1+2
15	F	21	4	0	2	1	2	1	0	0	2	1	1	0
16	M	27	4	0	3	3	2	1	0	1	2	1	0	1+2
17	M	22	2	0	1	2	1	1	0	2	1	1	0	1+2+5
18	M	22	1	0	2	0	1	1	1	2	0	0	1	1+2+3

A Case

B Sex

C Age at the time of injury

D Sport when the injury occurred

- 1 basketball
- 2 American football
- 3 gymnastics
- 4 skiing
- 5 soccer
- 6 tug of war
- 7 work-related

E Radiography

- 0 normal
- 1 fracture

F Lachman exam under anesthesia

- 1-3 +

G Pivot shift exam under anesthesia

- 0 normal
- 1-3 +

H Arthroscopic ACL evaluation

- 1 partial tear
- 2 total tear
- 3 avulsion

I Arthroscopic lateral meniscal evaluation

- 0 normal
- 1 tear

J Arthroscopic medial meniscal evaluation

- 0 normal
- 1 tear

K Arthroscopic cartilage changes

- 0 normal
- 1 lateral femoral condyle
- 2 lateral tibial plateau
- 5 other

L MRI ACL evaluation

- 0 normal
- 1 partial tear
- 2 total tear

M MRI lateral meniscal evaluation

- 0 normal
- 1 tear

N MRI medial meniscal evaluation

- 0 normal
- 1 tear

O MRI osseous lesion

- 0 normal
- 1 lateral femoral condyle
- 2 lateral tibial plateau
- 3 medial femoral condyle
- 4 medial tibial plateau
- 5 cortical depression

Results

MRI detected 16 complete anterior cruciate tears, 1 partial tear and 1 normal ligament (Table 1). All 16 total ruptures were confirmed by arthroscopy. In addition, arthroscopy showed 2 partial anterior cruciate ligament lesions, 1 of which was classified as normal according to MRI. MRI diagnosed 28 bony lesions in the 18 patients; only 3 patients had normal bony signals. 27 of the lesions were located in the lateral compartment (Figure 2). 3 patients had cortical depression on the MRI (Figure 3). 5 patients showed cartilage injuries according to arthroscopy, including the 3 patients with cartilage depression shown on MRI.

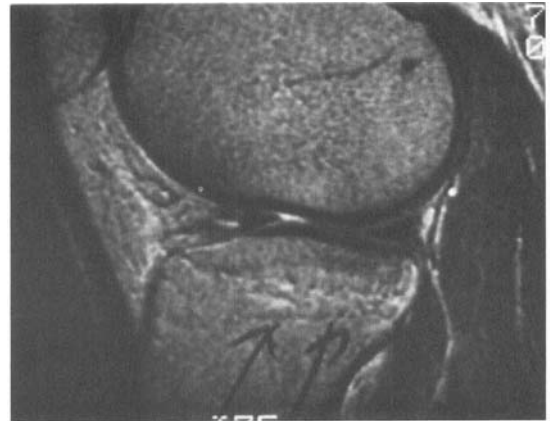

Figure 2. Case 1. T2 signal increase representing a lesion of the lateral tibial plateau in an anterior cruciate ligament-injured patient.

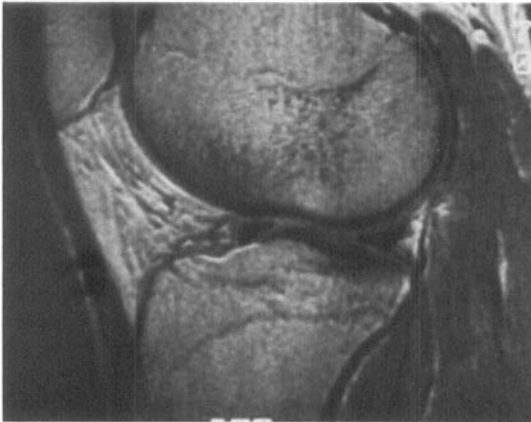


Figure 3. Case 17. Impaction in the lateral femoral condyle of a football player with an acute anterior cruciate ligament.

Discussion

The accuracy of diagnosis by MRI of the knee compared to arthroscopy has been reported to range from 64 to 95 percent for the medial meniscus, from 83 to 94 percent for the lateral meniscus, and from 78 to 97 percent for the anterior cruciate ligament (Jackson et al. 1988, Lee et al. 1988, Fischer et al. 1991). The study by Rosen et al. (1991) implies that when the anterior ligament is torn, there is an 85 percent chance that the patient also has sustained an osseous lesion seen on the MRI. This was confirmed by our study where only 3 of the 18 patients had no osseous lesions. An exact understanding of what these abnormal MRI signals represent is not available. The areas of low signal intensity on T1-weighted images are felt to represent areas of trabecular compression, edema or hemorrhage, whereas the somewhat increased signal intensity on T2-weighted images represents areas of edema and hemorrhage. A biopsy from the lesion site showed edema and hemorrhage, which was interpreted by the pathologist as consistent with a recent fracture (Rosen et al. 1991). In an animal study on subchondral damage following acute transarticular loading, MRI, histologic and scanning electronmicroscopic findings were correlated (Vener et al. 1992). They concluded that changes identified on MRI in their animals appeared similar to those described in humans following trauma; the changes probably represent subchondral cracking, with granulation tissue that may lead to arthrosis.

Vellet et al. (1991) classified bony lesions according to MRI in humans into reticular, geographic, linear, impaction and osteochondral fractures. At follow-up 6-12 months post-injury, two thirds of their patients had evidence of osteochondral sequelae corresponding

to the site of their geographic fractures. Resolution with no apparent sequelae at the site of the associated reticular fracture was demonstrated in all cases. Consequently, it seems that only certain types of osseous lesions create subchondral and thereafter chondral changes.

In our study, the dominant mechanism of injury probably involved rotation of the femur and tibia relative to each other, resulting in the anterior cruciate ligament tear. This subjected the femoral condyle and the tibial plateau to high forces, resulting in osseous lesions. The preponderance of osseous lesions within the lateral compartment is consistent with the increased valgus forces with or without rotation seen at the time of injury. As suggested by Vener et al. (1992) this type of injury may increase the risk of arthrosis. Thus, the damage seems to occur during the acute phase and may lead to arthrosis, even if the anterior ligament is reconstructed and the knee stabilized.

References

- Fischer S P, Fox J M, Del Pizzo W, Friedman M J, Snyder S J, Ferrel R D. Accuracy of diagnoses from magnetic resonance imaging of the knee. A multicenter analysis of one thousand and fourteen patients. *J Bone Joint Surg (Am)* 1991; 73 (1): 2-10.
- Jackson D W, Jennings L D, Maywood R M, Berger P E. Magnetic resonance imaging of the knee. *Am J Sports Med* 1988; 16 (1): 29-38.
- Lee J K, Yao L, Phelps C T, Wirth C R, Czajka J, Lozman J. Anterior cruciate ligament tears: MR imaging compared with arthroscopy and clinical tests. *Radiology* 1988; 166 (3): 861-4.
- Rosen M A, Jackson D W, Berger P E. Occult osseous lesions documented by magnetic resonance imaging associated with anterior cruciate ligament ruptures. *Arthroscopy* 1991; 7 (1): 45-51.
- Vellet A D, Marks P H, Fowler P J, Munro T G. Occult post-traumatic osteochondral lesions of the knee: prevalence, classification, and short-term sequelae evaluated with MR imaging. *Radiology* 1991; 178 (1): 271-6.
- Vener M J, Thompson R C, Griffiths H, Lewis J L, Oegema T R, Wallace L. Subchondral damage following acute transarticular loading: Correlation of MRI, histologic and SEM changes in a canine model. *Proc 59th Meeting AAOS Spec Day, Washington* 1992: 169.