

Discitis in childhood

12–35-year follow-up of 35 patients

Bernard R H Jansen¹, Wimpeter Hart¹ and Oene Schreuder²

We report a follow-up of 35 children, on average 17 years after they had intervertebral discitis. 15 patients still complained of backache. Flexion of the low back was normal in 32 patients, while extension was mark-

edly restricted in 30. 26 patients had a block vertebra, and 28 patients had narrowing of the vertebral canal. Mode of treatment did not appear to affect the outcome.

¹Reinier de Graaf Gasthuis, Reiner de Graafweg 3, 2625 AD Delft, The Netherlands, ²St. Franciscus Gasthuis, Rotterdam, The Netherlands. Tel +31-15 603060. Fax -15 603599
Submitted 91-11-28. Accepted 92-06-16

In 1977 one of us (BJ) reported the results of a retrospective analysis of 40 children and 45 adults with spondylodiscitis. It appeared that bloodborne infections can start in the intervertebral disc and that the difference in outcome between adults and children is due to the difference in blood supply and the condition of the endplates of the adjacent vertebrae. In the literature there is no consensus about the regeneration of the disc. Chappuis et al. (1969) thought that repair was possible if the spondylodiscitis had started before the age of three. Spiegel et al. (1972) reported a 7-year follow-up in 28 children; one quarter had partial or complete bony fusion. This study was carried out to investigate the fate of the intervertebral disc in 35 cases followed up for an average of 17 years.

Patients and methods

In 1986 we examined 35 patients in the original group of 40 children, 20 women and 15 men, who had suffered discitis at the age of 5 (1–15) years and whose conditions were primarily described by Jansen (1977) at an average of 7 years after onset of the disease. Biopsy of the disc was never performed. In 1986 the mean age of this group was 22 (17–43) years.

The mean follow-up was 17 (12–35) years. 5 children were lost to follow-up. All patients except one had initially bedrest for an average of 5 (2–12) weeks; 24 in a plaster jacket and 10 without. 28 patients were given broad-spectrum antibiotics for 2 weeks to 6 months, while 7 had no antibiotics. Mobilization was started in 23 patients with a support such as a Jewett brace which was used for 7 (3–18) months. In 12 children no support was used.

All 35 patients completed an extensive questionnaire regarding occupation, sports and backache problems. Functional analysis was done according to the method of Moll and Wright (1971), measuring the difference between two marks, 5 cm below and 10 cm above the lumbosacral junction, in flexion the distraction, in extension the attraction. AP and lateral radiographs were taken while the patients were standing. The heights were measured of the affected disc and of the disc above. As to the development of a vertebra magna, we measured the lengths of the proximal and distal endplates of the vertebral body proximal to the affected disc. To establish the possible narrowing of the vertebral canal, we measured the largest diameter of the vertebral foramen at the site of the affected disc and compared this to the same measurement of the foramen of the disc above. On the AP-projection, scoliosis was measured according to Cobb (1948), and on the lateral projection any marked lordosis or marked kyphosis was recorded. We further investigated the correlation between therapy administered and final outcome.

Results

Questionnaire

13 patients had no complaints, 7 seldom, 11 now and then, 3 frequently, and 1 daily. 15 patients had seen their family doctor for backache problems, and 8 had been referred to a specialist (Table 1). Only one patient had had to stop working due to back-problems and another had to change her occupation. 13 patients engaged in sports on a competitive level, and 15 on a recreational basis. Only one girl gave up sports because of backache.

Table 1. Observations in 35 patients with spondylodiscitis

| Case | A | B | C | D | E | F | G | H | I | J | K | L | M | N | O | P | Q | R |
|------|---|------|----|---|---|---|----------------|----|-----|----|---|---|---|---|---|---|---|---|
| 1 | M | 6.4 | 26 | c | 2 | 2 | L1-L2 | 15 | +7 | 17 | 2 | 3 | 1 | 2 | d | 0 | 0 | - |
| 2 | F | 14.4 | 23 | c | 2 | 0 | L1-L2 L2-L3 | - | - | 30 | 0 | 3 | 1 | 0 | d | 0 | 2 | - |
| 3 | F | 4.4 | 16 | c | 1 | 1 | L4-L5 | 6 | +8 | - | 2 | 3 | 2 | 3 | d | 1 | 1 | - |
| 4 | M | 2.3 | 28 | e | 5 | 0 | L4-L5 | 6 | +14 | - | 0 | 3 | 3 | 4 | f | 0 | 1 | - |
| 5 | F | 2.0 | 16 | b | 1 | 0 | L2-L3 | 6 | +12 | 52 | 0 | 3 | 2 | 2 | d | 1 | 0 | + |
| 6 | F | 1.8 | 15 | a | 1 | 2 | L3-L4 | 6 | 6 | - | 2 | 3 | 1 | 2 | a | 1 | 0 | - |
| 7 | F | 4.3 | 17 | b | 3 | 2 | L4-L5 | 4 | 4 | - | 1 | 3 | 2 | 3 | d | 0 | 0 | - |
| 8 | F | 7.4 | 20 | a | 1 | 1 | L4-L5 | - | 6 | 52 | 1 | 3 | 2 | 3 | d | 0 | 0 | - |
| 9 | F | 12.1 | 26 | b | 1 | 0 | T11-T12 | 8 | 8 | - | 1 | 2 | 0 | 0 | a | 1 | 1 | - |
| 10 | F | 3.4 | 30 | a | 3 | 1 | L5-S1 | 4 | +7 | - | 0 | 3 | 2 | 1 | a | 1 | 1 | - |
| 11 | F | 3.0 | 19 | b | 3 | 0 | T6-T7 | 12 | 4 | 16 | 0 | 2 | 0 | 0 | a | 0 | 0 | - |
| 12 | M | 6.9 | 23 | a | 3 | 2 | L3-L4 | 8 | +22 | - | 2 | 3 | 0 | 1 | a | 1 | 0 | - |
| 13 | F | 12.3 | 36 | d | 3 | 1 | T11-T12 | 4 | +8 | 20 | 0 | 3 | 0 | 0 | d | 0 | 0 | - |
| 14 | F | 4.9 | 26 | c | 4 | 1 | L5-S1 | 6 | +26 | 20 | 0 | 3 | 1 | 1 | a | 1 | 0 | - |
| 15 | M | 5.6 | 18 | a | 1 | 2 | L5-S1 | 8 | +4 | - | 0 | 3 | 1 | 1 | a | 0 | 0 | - |
| 16 | F | 3.5 | 16 | d | 1 | 3 | L3-L4 | 4 | +10 | 22 | 3 | 2 | 3 | d | 3 | 0 | + | - |
| 17 | F | 1.7 | 17 | a | 1 | 2 | L4-L5 | - | 5 | - | 0 | 3 | 3 | 3 | d | 1 | 0 | - |
| 18 | F | 14.2 | 35 | c | 3 | 1 | L4-L5 | - | +22 | - | 0 | 3 | 1 | 1 | c | 3 | 0 | - |
| 19 | F | 11.2 | 22 | c | 3 | 2 | L2-L3 | 4 | 2 | - | 2 | 2 | 2 | 2 | a | 0 | 2 | - |
| 20 | M | 2.2 | 18 | a | 1 | 2 | L2-L3 | 11 | 10 | - | 2 | 3 | 1 | 1 | d | 0 | 0 | - |
| 21 | F | 2.9 | 22 | c | 2 | 2 | L3-L4 | 8 | 22 | 78 | 0 | 3 | 2 | 3 | d | 1 | 0 | + |
| 22 | M | 4.5 | 22 | c | 2 | 1 | L4-L5 | - | +8 | - | 3 | 4 | 3 | 3 | c | 0 | 0 | - |
| 23 | M | 4.9 | 27 | b | 2 | 1 | L2-L3 | 18 | +18 | - | 0 | 3 | 0 | 0 | d | 0 | 0 | - |
| 24 | M | 9.8 | 27 | c | 1 | 1 | L4-L5 | 22 | 131 | - | 0 | 3 | 2 | 2 | c | 0 | 0 | - |
| 25 | M | 3.1 | 21 | a | 3 | 2 | L1-L2 | - | +28 | 30 | 0 | 3 | 1 | 1 | d | 0 | 0 | + |
| 26 | F | 3.9 | 22 | c | 3 | 1 | L3-L4 | 18 | +18 | - | 0 | 3 | 2 | 1 | c | 0 | 0 | - |
| 27 | M | 2.1 | 17 | b | 1 | 2 | L4-L5 | 18 | +18 | 18 | 2 | 2 | 0 | 0 | a | 0 | 1 | - |
| 28 | M | 14.8 | 32 | c | 3 | 1 | L1-L2 | 3 | +3 | 78 | 2 | 3 | 0 | 0 | c | 0 | 1 | - |
| 29 | F | 5.2 | 19 | a | 3 | 1 | L3-L4 | 4 | +4 | - | 1 | 3 | 2 | 1 | c | 3 | 0 | - |
| 30 | F | 2.1 | 22 | a | 2 | 1 | L3-L4 | 5 | +6 | 18 | 0 | 3 | 2 | 2 | d | 3 | 0 | - |
| 31 | F | 6.9 | 21 | a | 3 | 1 | L1-L2 | - | +18 | - | 0 | 2 | 1 | 1 | d | 0 | 1 | - |
| 32 | F | 8.1 | 26 | a | 1 | 2 | L4-L5 | 6 | +14 | - | 0 | 3 | 2 | 3 | b | 0 | 1 | - |
| 33 | F | 5.2 | 20 | d | 2 | 1 | L5-S1 | 14 | +14 | 14 | 3 | 1 | 1 | a | 1 | 1 | - | - |
| 34 | M | 2.9 | 17 | a | 1 | 2 | L4-L5 | 4 | 6 | - | 1 | 4 | 2 | 3 | d | 0 | 1 | - |
| 35 | M | 4.9 | 19 | b | 2 | 2 | L1-L2 | 2 | 31 | - | 1 | 3 | 2 | 2 | d | 0 | 0 | - |

A Sex

B Age at onset disease

C Age at follow-up

D Complaints

a never

b seldom (2-5 times since sickness)

c now and then (a few days per year)

d frequent (a few days per month)

e daily

E Occupation

1 school, housewife, no work

2 sedentary work

3 ambulant work

4 changed work due to backache

5 stopped working due to backache

F Sport

0 none

1 recreational

2 competitive

3 changed sport due to backache or stiffness

G Localization

H Antibiotics, number is total of weeks administered

I Bedrest

+ with jacket, number is total weeks

- no bedrest

J Mobilization

+ with jacket

- without jacket, number is total weeks

K, L, M, N and O see Figure 1

P Lateral curve according to Cobb

0 0°

1 0-5°

2 5-10°

3 > 10°

Q Discopathy

0 none

1 1 level

2 2 levels

R Spondylolysis (bilateral arch defect)

- not seen

+ present

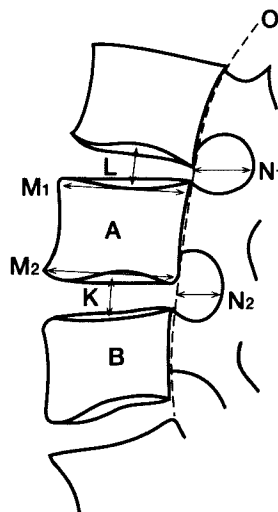
Physical examination

In 21 patients there were no abnormal findings. 4 patients had an accentuated lumbar lordosis and 4 a diminished lumbar lordosis. Lumbar scoliosis was found in 2 patients and a marked kyphosis in 3. 2 patients reported localized pain at the level of the

affected disc. In the age group 15-25 years, the normal range in flexion is 5-9 cm. Only 3 patients had a diminished flexion, 32 patients had a normal range with an average of 7 cm. The normal extension at this age is 1-7 cm, average 5 cm. In our group the range of motion was 1-5 cm with an average of 2.3 cm.

Figure 1. Measurements taken on the lateral view.

- K. The height of the affected disc
 0 0 mm
 1 1-5 mm
 2 5-10 mm
 3 10-15 mm
 4 more than 15 mm
- L. The height of the proximal disc
 0 0 mm
 1 1-5 mm
 2 5-10 mm
 3 10-15 mm
 4 more than 15 mm
- M. The difference between the length of the proximal endplate and the distal endplate of A, the vertebra lying proximal to the affected disc
 0 0 cm
 1 0-0.5 cm
 2 0.5-1 cm
 3 1-1.5 cm
 4 more than 1.5 cm
- N. The difference in percentage in the narrowing of the vertebral canal on the affected side and one level higher
 1 0-10 percent
 2 10-25 percent
 3 25-50 percent
 4 more than 50 percent
- O. The line drawn along the posterior ends of 3 vertebrae
 a normal line
 b lordosis
 c marked lordosis
 d kyphosis

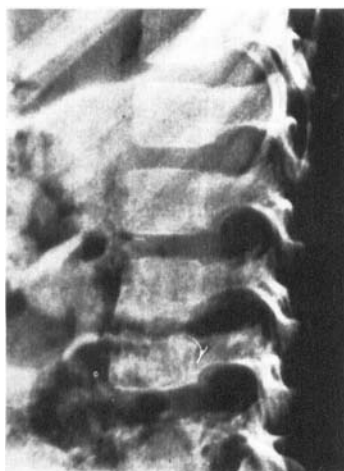

- A. Proximal vertebra
 B. Distal vertebra of the affected disc.

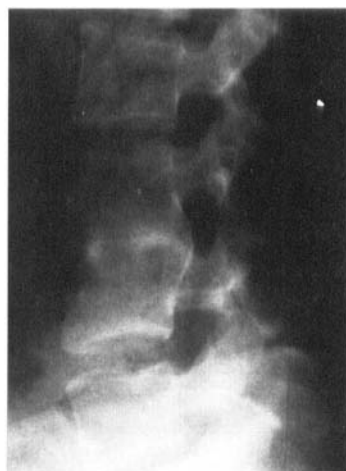Radiographic evaluation

The location of discitis was L1-L2 in 5, L2-L3 in 4, L3-L4 in 7, L4-L5 in 11 and L5-S1 in 4 patients. One patient had an affected disc at Th6-7 and 2 patients at Th11-12. One patient had two affected discs, L1-L2 and L2-L3. We found a block vertebra at the site of the original discitis in 26 patients, a marked disc space narrowing in 8 patients, and a nearly normal disc height in only one patient. In Case 2 with two levels affected there was a block of three vertebrae. In 4 patients we saw a decrease in the height of the disc one level above the affected disc, in 6 patients a decrease below the affected level, and in 2 patients a decrease in height of the disc at more than two levels. In 4 patients a spondylolysis was found while earlier there had been no bilateral arch defect. In 28 cases the length of the proximal endplate was less than the length of the distal endplate near the affected disc, indicating a vertebra magna. In 28 patients a narrowing of the vertebral canal could be seen on the lat-

Figure 2. Case 21.



Acute stage of spondylodiscitis in a 2.9-year-old girl.



19 years later, block vertebra with stenosis of vertebral canal.

eral view, compared with the diameter of the canal one level higher (Figure 2). 23 patients had a kyphosis at the level of the affected disc space. In 13 cases there was a lateral curve, in 4 cases of more than 10°. In 2 cases we found an unrelated transitional vertebra L5.

Discussion

Wenger et al. (1978) reported a follow-up of 7 years of 38 cases. They found 9 patients with recurrent backache, and 5 patients who needed new treatment in hospital. Spiegel et al. (1972) found complaints of backache in 14 of their 28 patients. Menelaus (1964) reported more patients having backache after a longer period since the onset of the disease. We found frequent or daily backache in one tenth of our patients. In the age group of 30-45 years this incidence is about 25 percent (Andersson 1981). Older patients appear to complain more frequently of backache. In our series with an average age of 22 years we may expect more backache problems as patients grow older.

Our most important finding was a disturbance of the normal growth of the vertebrae, giving rise to a block vertebra in 26 cases and vertebrae magna in 28 patients. Doyle (1960) saw 2 patients who recovered completely. Veraart (1988) thought that recovery was possible. Chappuis et al. (1969) stated that a complete recovery before the age of 3 was possible, but Matthews and Wiltse (1957), Childe and Tucker (1961). Jamison et al. (1961) and Rigault and Blanchard (1970) never saw a completely normal growth of the disc. Spiegel et al. (1972) reported partial recovery in 15 patients, partial fusion in 6 and complete fusion in 7. Wenger et al. (1978) found all grades of disc narrowing and 5 patients with spontaneous fusion. Considering the long-term follow-up in our series, it appears justified to state that a block vertebra will be nearly always the final outcome.

As Junghans (1965) found in congenital block vertebra, we also found that due to higher stress, arch defects will occur. The stress fractures of the arch support the idea that spondylolysis might be caused by mechanical forces. Mechanical stress can cause fissuring of the disc and decrease in disc height (Kricun 1988). This could be the cause of the high percentage of disc degeneration in this series.

Spiegel et al. (1972) found a lateral curve in the AP-view in 22 cases of their original 28. In our series 13 patients had a curve, and 4 a curve of over 10°. In the literature there is no report of narrowing of the vertebral canal, as was found in our study. In 2 patients this narrowing gave rise to symptoms of vertebral stenosis (Verbiest 1976) and in 1 patient a laminectomy was performed.

References

- Andersson G B. Epidemiology aspects on low back pain in industry. *Spine* 1981; 6 (1): 53-60.
- Chappuis J P, Daudet M, Lerat J L, Fournier P, Korkmaz G. Prépondérance des spondylodiscites à pyogènes dans la pathologie vertébrale de l'enfant. A propos 15 observations. *Ann Chir Infant* 1969; 10 (6): 475-94.
- Childe A E, Tucker F R. Spondylarthritis in infants and children. *J Can Ass Radiol* 1961; 12: 47-51.
- Cobb J R. TI. *Amer Acad Orthop Surg* 1948, Lect: 5: 261.
- Doyle J R. Narrowing of the intervertebral disc in children. *J Bone Joint Surg (Am)* 1960; 42: 1191-2000.
- Jamison R C, Heimlich E M, Miethke J C, O'Loughlin B J. Non-specific spondylitis of infants and children. *Radiology* 1961; : 225-367.
- Jansen B R H. *Spondylodiscitis*. Thesis Rotterdam University, Delft, The Netherlands 1977.
- Junghans H. Die funktionelle Röntgenuntersuchung der Wirbelsäule. *Dtsch Med Wschr* 1965; 90: 156-215.
- Kricun, M. E. (Ed.) *Imaging Modalities in Spinal Disorders*. W B Saunders Company, Philadelphia 1988.
- Matthews S S, Wiltse L L. Destructive lesion involving intervertebral disc in children. *Clin Orthop* 1957; 9: 162-8.
- Menelaus M B. Discitis, an inflammation affecting the intervertebral discs in children. *J Bone Joint Surg (Br)* 1964; 46: 16-23.
- Moll J M, Wright V. Normal range of spinal mobility. An objective clinical study. *Ann Rheum Dis* 1971; 30 (4): 381-6.
- Rigault P, Blanchard J P. Spondylodiscites à germes banaux chez l'enfant. *Rev Chir Orthop* 1970; 56 (4): 367-82.
- Spiegel P G, Kengla K W, Isaacson A S, Wilson J C Jr. Intervertebral disc space inflammation in children. *J Bone Joint Surg (Am)* 1972; 54 (2): 284-96.
- Veraart B E. Backache in children and adolescents. *Tijdschr Kindergeneeskde* 1988; 56 (6): 279-88.
- Verbiest H. Fallacies of the present definition, nomenclature and classification of the lumbar vertebral canal. *Spine* 1976; 1: 217-25.
- Wenger R W, Walter P B, Gilday D L. The spectrum of intervertebral disc space infection in children. *J Bone Joint Surg (Am)* 1978; 60: 100-8.