

# Free flaps in the reconstruction of foot injury

## 4 (1–7) year follow-up of 24 cases

Astor Reigstad, Karl R Hetland, Kjell Bye, Svein Waage, Magne Røkkum and Torstein Husby

We reconstructed in 24 patients, traumatic tissue loss in the foot with 10 lateral arm flaps and 14 scapular flaps. The mean follow-up was 4 (1–7) years. There was 1 flap loss, and 1 patient was amputated

because of septic ankle arthrodesis. Healing with stable skin and scar was achieved in the remaining patients. Only patients with additional serious skeletal injury had reduced walking ability.

National Orthopedic Center, Kronprinsesse Märthas Institutt, N-0570 Oslo, Norway. Tel +47-22 954300. Fax -22 954523  
Submitted 93-03-07. Accepted 93-08-19

The reconstruction of traumatic soft tissue and bone defects of the weight-bearing surface of the foot is difficult. Conventional flaps (Morris and Buchan 1978) can hardly provide coverage of the heel and the sole, and reconstruction by free flaps is often the only alternative to amputation in cases with gross tissue loss. However, the durability of the flaps in foot surgery has been questioned (McCraw and McInnis 1982). We present our experience of free tissue transfer for traumatic gross tissue defects of the foot.

### Patients and methods

During 1985–1991 we used free flaps to reconstruct traumatic gross tissue defects of the foot in 20 men and 4 women, aged 30 (5–69) years (Table 1). In 20 cases the injury was a result of blunt trauma, crushing or avulsion, in 2 of a gun shot, in 1 of burn, and in 1 case of frost bite.

Lateral arm flaps were used in 10 cases, and scapular flaps in 14; and the average sizes of the flaps were 52 cm<sup>2</sup> and 129 cm<sup>2</sup>, respectively. The arm flap was transferred with the sensory posterior nerve of the arm and forearm in 3 cases. 2 scapular flaps were raised as compound skin and bone flaps (Figure 1), and another scapular flap as a double skin flap covering 2 separate defects.

The mean delay between the injury and the flap transfer in 7 patients referred for longstanding post-traumatic problems was 11 (3–33) years versus 69 (4–330) days for 17 patients who had been under continuous treatment after the injury. Prior to the flap transfer, most patients had wound revision, split skin grafting, bone resection, partial amputation, osteosyn-

thesis, and/or bone transplantation.

The procedures for raising the flaps were as described by Katsaros et al. (1984) and Nassif et al. (1982), respectively. The receptor vessels were the posterior tibial vessels in 13 cases, the anterior tibial vessels in 3 cases, the dorsal vessels of the foot in 6 cases and the fibular vessels in the remaining 2 cases. The donor defects were sutured directly after 8 arm flaps and 10 scapular flaps, and covered with split skin grafts in the other cases. The mean follow-up was 4 (1–7) years.

### Results

No substantial donor site problems were seen. All but 1 flap healed eventually.

*Complications.* Revision of the anastomoses had to be performed in 6 cases, 5–52 hours after completion of the transfer.

In Case 12 the compound scapular flap failed due to arterial thrombosis. The flap was removed, the 4th toe ray was removed, and its skin was mobilized for partial coverage.

In a diabetic and alcoholic patient with a defect in the lateral malleolar area following a trimalleolar fracture (Case 8), an ankle arthrodesis was performed after the flap transfer. The arthrodesis became infected and a below-knee amputation was performed.

*Skin and scar stability.* In 5 patients, prolonged wound healing occurred. After revision and resuture the wounds healed. In 10 patients, one or multiple reduction operations of the flap, some of them in combination with scar revisions and Z-plasties, were carried out. In some of the loaded flaps which had to be

Table 1. Observations in 24 free flap transfers after injury

A	B	C	D	E	F	G	H	I	J	K	L	M	N	O	P	Q	R
1	18/M	4d	1	1	2,3	1	9×24	0	1	0	7.4	1	0	1	1	1	-
2	28/M	35d	2	5	2,3,4	1	12×24	0	1	3	7.3	3	0	0	1	1	1
3	33/F	33y	5	1	2,3	1	8×15	0	2	0	7.2	1	0	1	1	1	-
4	20/M	22d	1	1	3	3	2×6×6	0	0	1	7.2	1	0	1	1	1	-
5	17/F	4d	3	1	2,3	1	6×12	1	0	2	6.6	2	0	1	1	1	-
6	5/M	26d	2	5	2,3	1	6×10	0	0	4	6.5	2	2	1	1	1	-
7	29/F	9y	3	5	2,3	1	6×16	0	0	2	6.3	2	1	1	2	1	2
8	58/M	91d	4	1	3	4	5×12	0	2	0	5.6	1	0	0	3	2	3
9	10/M	245d	2	4	1	5	6×8	1	0	0	5.6	1	2	1	1	1	-
10	24/M	19y	6	4	1	5	5×6	0	0	1	4.7	2	2	1	1	1	-
11	45/M	73d	2	5	2,3	1	8×30	1	3	2	4.7	2	0	1	1	2	2
12	20/M	33d	3	1,5	2,3	2	5×8	1,2	4	-	4.5	1	0	-	1	2	-
13	26/M	7d	0	1,5	2,3	1	8×15	1	0	0	4.5	1	0	1	1	1	4
14	18/M	90d	5	5	1	1	8×10	0	0	1	3.8	2	0	1	1	1	-
15	37/M	59d	3	1	2,3	1	5×12	0	2	0	3.6	1	0	1	1	1	-
16	15/M	49d	2	4	2	4	5×7	0	0	0	3.6	1	1	1	1	1	-
17	54/M	80d	2	4	4	4	4×8	1	0	0	3.4	2	0	1	1	1	-
18	59/M	3y	4	5	1	1	7×14	0	0	3	3.4	2	0	1	1	1	-
19	24/M	330d	4	1,3	3	4	5×15	0	1,2	0	2.3	1	0	1	2	2	5
20	44/M	3y	4	4	3	4	5×9	0	3	0	1.9	1	0	1	2	2	5
21	69/M	5y	5	4	2	4	5×12	0	0	0	1.8	1	0	1	1	1	-
22	35/F	8y	2	1	3	4	5×12	0	0	0	1.4	1	0	1	1	1	-
23	24/M	22d	3	4	2,3,4	2	15×28	1	0	3	1.3	2	0	1	2	2	5
24	15/M	4d	1	1,5	3	5	5×12	0	0	0	1.2	1	2	1	1	1	-

A Case	5 sensory lateral arm	1 some
B Age/sex	H Flap size (cm × cm)	2 excellent
C Delay injury-flap transfer	I Complications	O Deep sensation
D No. of operations prior to the transfer	0 none	0 none
E Site of defect	1 revision of anastomoses	1 good
1 dorsum/anterior ankle	2 necrosis of the flap	P Foot wear
2 lateral malleolus	J Secondary procedures	1 normal
3 medial malleolus	0 none	2 special
4 calcaneum/Achilles	1 triple arthrodesis	3 amputated
5 planta	2 ankle arthrodesis	Q Ambulatory status
F Covered tissue	3 bone resection	1 normal
1 skin only	4 amputation of 4th toe ray	2 reduced
2 tendon	K No. of operative flap reductions	R Comments
3 bone/bone graft/joint	L Follow-up (years)	1 coverage of replanted foot
4 nerve	M Flap and scar stability	2 primary partial foot amputation
G Type of flap	1 excellent	3 diabetes and alcoholism
1 simple scapular	2 excellent after flap reduction/Z-plasty	4 coverage of Lisfranc' amputation
2 compound scapular (including 5 cm bone)	3 fissure occasionally	5 coverage of serious skeletal foot injury
3 double scapular	N Skin sensation	
4 simple lateral arm	0 none	

reduced, the subcutaneous fat layer did not attach the flap firmly enough to the tissue underneath. Shear forces between the loose flap and the firmly-fixed original skin created scar problems. After removal of the subcutaneous flap fat and excision of the hypertrophied scar in combination with Z-plasty, the situation stabilized (Figure 2). Older patients achieved the same flap stability as younger ones.

**Sensibility.** The 3 sensory flaps had good superficial sensation at follow-up; the patients were able to discriminate between touch and pain, warm and cold, and the static 2-point discrimination test varied between 10 and 25 mm. 1 additional flap in a 5-year-old boy with no nerve supply to the flap had surprisingly achieved 6 mm 2-point discrimination, hardly

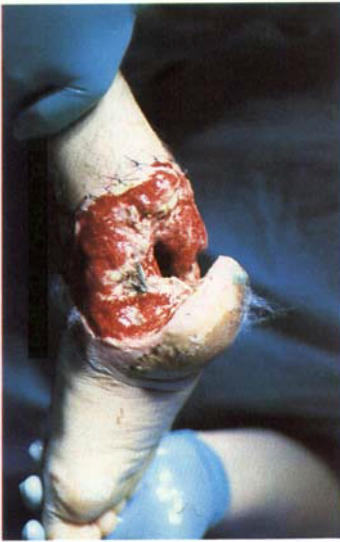
different from the contralateral foot sole. Deep sensation, tested by pressing the flap with a finger (Rautio et al. 1989), was present in 21 flaps.

**Foot-wear and walking ability.** 14 patients were able to wear a normal shoe on the reconstructed foot and 8 needed special foot-wear. Reduced walking ability in 6 patients was due to serious skeletal foot injuries or different types of partial foot amputations.

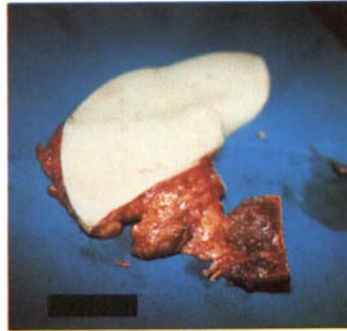
## Discussion

In foot injuries with gross tissue loss, split skin grafts may not provide adequate coverage for weight bearing

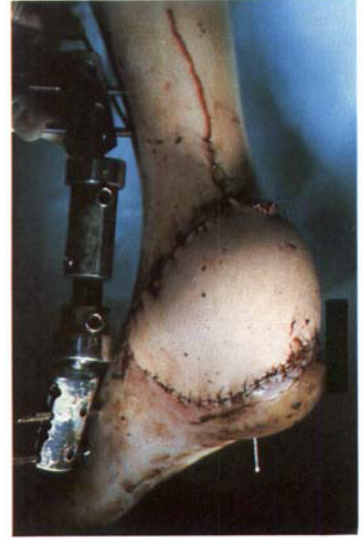
Figure 1. Case 23. A 24-year-old man who sustained a traffic crush injury resulting in partial loss of the calcaneum and necrosis of the heel and Achilles tendon.



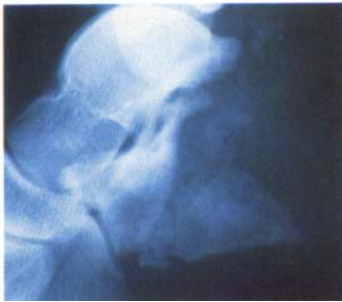Defect after serial revisions.



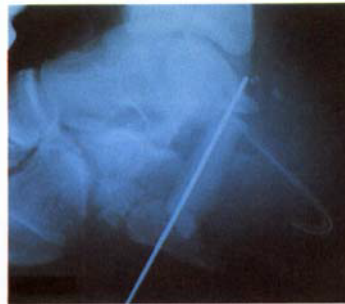Compound scapular flap. White arrow: the bone transplant. Black arrow: the vascular pedicle.



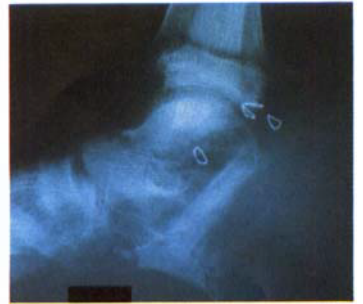Coverage by the scapular flap.



The calcaneal defect.



Postoperatively, arthrodesis with the lateral margin of the scapula.



Solid subtalar fusion 11 weeks after surgery.

or tendon gliding, and they cannot be used where joint or bone are exposed. The limitation of local flaps (Giordano et al. 1989, Gumener et al. 1991) is their size and mobility, and the fact that raising the flap inflicts an additional injury to the foot. The advantage of microvascular flaps to distant pedicle flaps, like the cross-leg flap (Morris and Buchan 1978), is that the former may solve the problem of coverage in one single stage in a more convenient way with less donor site problems (May et al. 1985, Stevenson and Mathes 1986, Rautio et al. 1990).

Before providing coverage it is vital that the complex wound in the foot is converted into surgically clean excised areas with a stable bone structure. The timing of the transfer is a matter of controversy. No patient in our series was treated by an emergency free flap, and we believe that serial debridements and

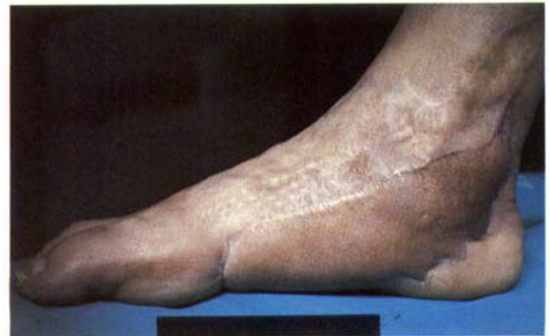

Figure 2. Result after reduction of a bulky scapular flap, scar revision and Z-plasties (Case 18).

delayed reconstruction is a safer method in foot surgery than one-stage coverage (Figure 1).

The ideal flap for reconstruction of the foot should include thin, durable hairless skin with potential for reinnervation (Hentz and Pearl 1987). The lateral arm flap may meet all these demands, whereas the scapular flap cannot be raised as a neurosensory flap. Our experience with both flaps is good, even when they were used in the weight-bearing foot sole and in the hind-foot (Colen et al. 1990, Suominen et al. 1992). The occasional fissuring at the edges, due to shear forces in somewhat bulky flaps, was solved by flap thinning and tightening in combination with scar excision and Z-plasties (Noever et al. 1986). The lateral arm flap can be raised with sizes up to  $7 \times 15$  cm, and the scapular flap can have a maximum size of  $15 \times 30$  cm. They can both be performed as osteocutaneous flaps using the lateral edge of the humerus or the lateral margin of the scapula. Musculocutaneous composite free flaps should not be used in plantar surface coverage due to the thickness and the multiple shear planes within the composite tissue transfer (Hentz and Pearl 1987, Meland 1990). However, tailored simple muscle flaps covered by split skin grafts seem to provide stable coverage of the plantar aspect of the foot and the calcaneum (May et al. 1985, Suominen et al. 1992).

The need for sensible coverage of the weight-bearing area of the foot has been discussed by several authors (Stock and Biemer 1984, Chang et al. 1986, Rautio et al. 1989, Sinha et al. 1989). If the nerve supply to the reconstructed foot is intact, the deep pressure sensation from the underlying tissue may have a protective effect (Hermanson et al. 1987). According to Lähteenmäki et al. (1989), free skin flaps have, in addition, a potential for developing sufficient protective touch and pain sensation, and even some superficial sensation, by nerve ingrowth from the edges. This was clearly demonstrated in Case 6 in our study.

## References

- Chang K N, DeArmond S J, Buncke H J Jr. Sensory reinnervation in microsurgical reconstruction of the heel. *Plast Reconstr Surg* 1986; 78 (5): 652-64.
- Colen L B, Reus W F, Kalus R. Posterior hindfoot reconstruction. *J Reconstr Microsurg* 1990; 6 (2): 143-9.
- Giordano P A, Argenson C, Pequignot J P. Extensor digitorum brevis as an island flap in the reconstruction of soft-tissue defects in the lower limb. *Plast Reconstr Surg* 1989; 83 (1): 100-9.
- Gumener R, Zbrodowski A, Montandon D. The reversed fasciocutaneous flap in the leg. *Plast Reconstr Surg* 1991; 88 (6): 1034-41.
- Hentz V R, Pearl R M. Application of free tissue transfers to the foot. *J Reconstr Microsurg* 1987; 3 (4): 309-20.
- Hermanson A, Dalsgaard C-I, Armander C, Lindblom U. Sensibility and cutaneous reinnervation in free flaps. *Plast Reconstr Surg* 1987; 79: 422-5.
- Katsaros J, Schusterman M, Beppu M, Banis J C Jr, Acland R D. The lateral upper arm flap: anatomy and clinical applications. *Ann Plast Surg* 1984; 12 (6): 489-500.
- Lähteenmäki T, Waris T, Asko Seljavaara S, Sundell B. Recovery of sensation in free flaps. *Scand J Plast Reconstr Surg Hand Surg* 1989; 23 (3): 217-22.
- May I W, Hall M I, Simon S R. Free microvascular muscle flaps with skin graft reconstruction of extensive defects of the foot: A clinical and gait analysis study. *Plast Reconstr Surg* 1985; 75: 627-41.
- McCraw J B, McInnis W D. Plastic surgery of the foot and ankle. In: *Disorders of the foot* (Ed. Jahss M H). W B Saunders Co. Philadelphia 1982; 1: 939-63.
- Meland N B. Microsurgical reconstruction: the weightbearing surface of the foot. *Microsurgery* 1990; 11 (1): 54-8.
- Morris A M, Buchan A C. The place of the cross-leg flap in reconstructive surgery of the lower leg and foot: a review of 165 cases. *Br J Plast Surg* 1978; 31 (2): 138-42.
- Nassif T M, Vidal L, Bovet J L, Baudet J. The parascapular flap: a new cutaneous microsurgical free flap. *Plast Reconstr Surg* 1982; 69 (4): 591-600.
- Noever G, Bruser P, Kohler L. Reconstruction of heel and sole defects by free flaps. *Plast Reconstr Surg* 1986; 78 (3): 345-52.
- Rautio J, Asko Seljavaara S, Laasonen L, Harma M. Suitability of the scapular flap for reconstructions of the foot. *Plast Reconstr Surg* 1990; 85 (6): 922-8.
- Rautio J, Kekoni J, Hamalainen H, Harma M, Asko Seljavaara S. Mechanical sensibility in free and island flaps of the foot. *J Reconstr Microsurg* 1989; 5 (2): 119-25.
- Sinha A K, Wood M B, Irons G B. Free tissue transfer for reconstruction of the weight-bearing portion of the foot. *Clin Orthop* 1989; 242: 269-71.
- Stevenson T R, Mathes S J. Management of foot injuries with free-muscle flaps. *Plast Reconstr Surg* 1986; 78 (5): 665-71.
- Stock W, Biemer E. Sensible Transplantate an der Fusssohle. *Handchir Mikrochir Plast Chir* 1984; 16 (4): 215-7.
- Suominen E, Tukiainen E, Asko Seljavaara S. Reconstruction of the Achilles tendon region by free microvascular flaps. 9 cases followed for 1-9 years. *Acta Orthop Scand* 1992; 63 (5): 482-6.