

# Carpal bossing with capitate-trapezoid fusion

## A case report

Guido Geutjens

Department of Hand Surgery, University Hospital Queen's Medical Centre, Nottingham, U.K.

Correspondence: Dr. G Geutjens, Institut Français de La Main, 15 Rue Benjamin Franklin, F-75116 Paris, France

Tel +33-1 428 88888. Fax -1 452 70009

Submitted 93-05-15. Accepted 93-07-23

Carpal bossing appears as a bony prominence between the base of the second or third metacarpal or both, and its articulation with the trapezoid or capitate bone. Its etiology is poorly understood, and it is often mistaken for a ganglion.

### Case report

A 33-year-old Asian man presented with pain on the back of his dominant right hand. In the last 6 months he had noticed a hard prominence in the painful area. He had a bony prominence over the base of the second and third metacarpal which was painful to palpation; he had a full range of wrist and finger movements, but his pain was reproduced at the extremes of wrist movements. Radiography showed carpal bossing, but also suggested the presence of a fusion between the capitate and the trapezoid. The fusion was confirmed by CT (Figure 1). His other hand was normal and showed no radiographic evidence of a capitate-trapezoid fusion.

The patient was offered operative treatment of his carpal bossing but declined.

### Discussion

Carpal coalitions are rare (Zielinski and Gunther 1981, Simmons and McKenzie 1985), and a fusion between capitate and trapezoid is one of the rarest (O'Rahilly 1953). Various explanations have been offered for the occurrence of carpal bossing or *carpe bossu*, as it was originally named by the French physician Fiolle (1931), such as childhood fracture (Fiolle 1931), rupture of the dorsal ligament (Menegaux 1934), congenital predisposition (Imbert 1932), traumatic periostitis secondary to pulling of the extensor carpi radialis bre-

vis insertion (Bunnell 1944), or an os styloideum (Hultgren and Lugnegård 1986).

Repeated minor trauma does appear to contribute to the development of carpal bossing, and some authors think it is a physiologic overgrowth of bone in response to stress factors (Larson et al. 1958, Lamphier 1960, Artz and Posch 1973).

There is little motion at the normal trapezoid-capitate-second-third metacarpal joint, as it is the fixed unit of the hand. In our case, no movement could occur between the capitate and the trapezoid and, therefore, a compensatory increase of movement at the joint between the synostosis and the bases of the second and third metacarpal may occur. This extra stress on the joint may have been responsible for the development of carpal bossing.

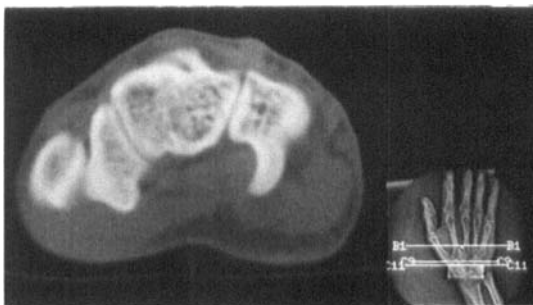


Figure 1. CT shows carpal bossing and fusion between the capitate and trapezoid bones. From left to right the structures shown are base of trapezium, fused trapezoid-capitate, and hamate.

### References

- Artz T D, Posch J L. The carpometacarpal boss. *J Bone Joint Surg (Am)* 1973; 55 (4): 747-52.

- Bunnell S. Surgery of the hand. 2nd Ed, J B Lippincott, Philadelphia 1944.
- Fiolle J. Le "carpe bossu". Bull Mem Soc Natl Chir 1931; 57: 1687-90.
- Hultgren T, Lugnegard H. Carpal boss. Acta Orthop Scand 1986; 57 (6): 547-50.
- Imbert R. A propos du carpe bossu. Considérations pathogéniques. Soc Chir Marseille 1932; 9: 337-8.
- Lamphier T A. Carpal bossing. Arch Surg 1960; 81: 1013-5.
- Larson R L, Lazcano M A, Janes J M. Carpal bossing. A common clinical entity. Proc Staff Meet Mayo Clin 1958; 33: 337-43.
- Menegaux G. Deux cas de carpe bossu. Rev Orthop 1934; 21: 231-3.
- O'Rahilly R. A survey of carpal and tarsal anomalies. J Bone Joint Surg (Am) 1953; 35: 626-43.
- Simmons B P, McKenzie W D. Symptomatic carpal coalition. J Hand Surg (Am) 1985 Mar; 10 (2): 190-3.
- Zielinski C J, Gunther S F. Congenital fusion of the scaphoid and trapezium. Case report. J Hand Surg 1981; 6 A: 220-2.