

Lower limb soft tissue reconstruction using microsurgical techniques

Othon N Papadopoulos and Nikolaos J Tsakoniatis

Trauma is the main cause of lower limb soft tissue defects followed by tumor resection, vascular disease and osteomyelitis. 17 patients were operated on using microsurgical techniques during the last 10 years. 9 of the patients had traumatic defects, 5 had various malignant tumors, 2 patients had arterial insufficiency and finally 1 patient had chronic osteomyelitis. The latissimus dorsi either as muscle flap with a split thickness skin graft or as a musculocutaneous flap was used the most frequently in our series. Other flaps, including the radial forearm neurovascular flap, the rectus abdominis flap, the scapular flap, the groin and the dorsalis pedis flaps were used less often. Delayed primary cover was used, except in 1 case with an opened knee joint trauma, where emergency repair was performed. Complications included: 2 partial skin graft necroses which required revision and 2 flap necroses caused by venous thrombosis. With follow-up more than 4 years in all but 2 patients, functional results were found satisfactory. Cosmetic results, however, were less satisfactory.

rovascular flap, the rectus abdominis flap, the scapular flap, the groin and the dorsalis pedis flaps were used less often. Delayed primary cover was used, except in 1 case with an opened knee joint trauma, where emergency repair was performed. Complications included: 2 partial skin graft necroses which required revision and 2 flap necroses caused by venous thrombosis. With follow-up more than 4 years in all but 2 patients, functional results were found satisfactory. Cosmetic results, however, were less satisfactory.

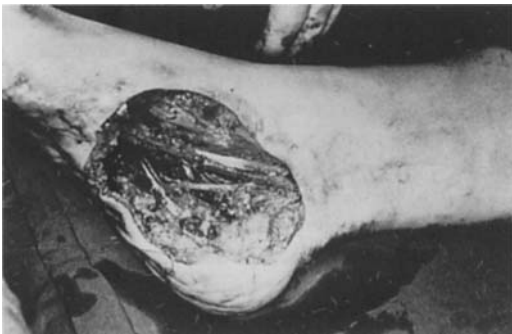Second Propedeutique Surgical Department, Athens University, School of Medicine, Athens, Greece.
Correspondence: Othon N. Papadopoulos, M.D., Assistant Professor in Plastic Surgery, 2 Lykiou Str, Athens 10674 Greece. Tel +30-1-7211159. Fax +30-1-7214414.

Trauma is the main cause of lower limb soft tissue defects followed by tumor resections, vascular disease and osteomyelitis. The ample skin and soft tissue of the thigh can be used to repair even large defects, so that free tissue transfer is rarely indicated in this region. In contrast, the skin of the lower leg and the foot has minimal laxity, relatively poor vascularity which lends poorly to surgical manipulations. Free tissue transfer to these areas is strongly indicated when local flaps are not available or not large enough to provide stable healing with good motor function, protective sensibility and contour correction for cosmesis.

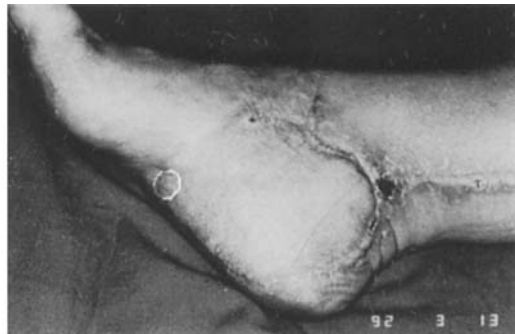Patients and methods

During the last 10 years, 17 patients with soft tissue defects of the lower limb were treated using microsurgical techniques. Among these patients, 9 had traumatic defects, 5 had malignant tumors, 2 patients had arterial insufficiencies and 1 patient had osteomyelitis of the lower leg. A latissimus dorsi flap either as a muscle flap combined with a split thickness skin graft or as musculocutaneous flap was used in a total of 11 patients (Figure 1). The radial forearm neurovascular flap was used in 2 cases to provide protective sensibility in the heel area. Other free

Figure 1. Case 14.



The defect following wide local resection of a hemangiosarcoma on the right foot.

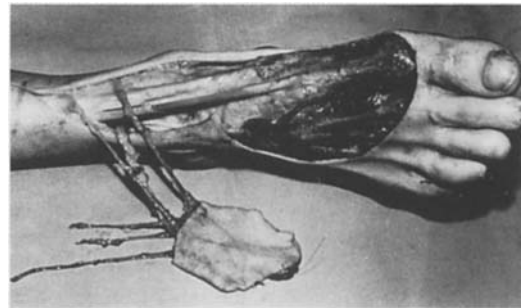
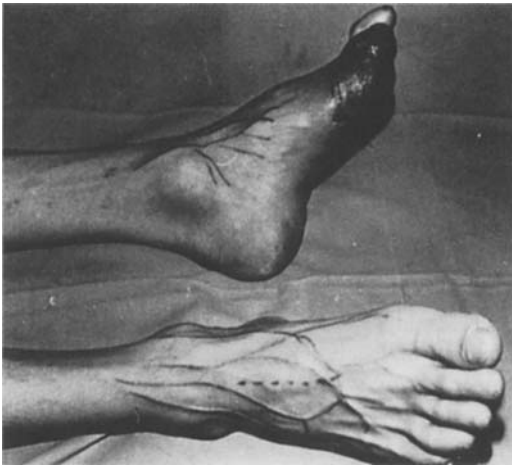


Stable coverage was achieved with a latissimus dorsi muscle flap and a split thickness skin graft.

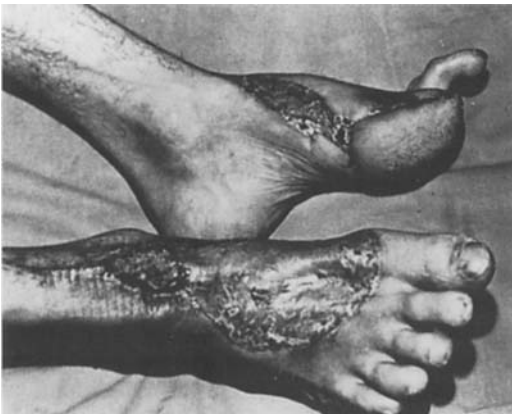Case	Age	Sex	Diag.	Defects	Treatment	Outcome
1	25	F	1	Anteromedial lower leg	Latissimus dorsi + skin graft	Lost
2	22	M	1	Knee and upper leg	Rectus abdominis MCF	Stable coverage
3	48	M	1	Entire leg	Latissimus dorsi + skin graft	Partial skin graft necrosis
4	52	M	1	Upper posterior leg	Latissimus dorsi MCF	Lost
5	19	M	1	Entire posterior leg	Latissimus dorsi MCF	Stable coverage
6	65	F	1	Anterior lower leg and dorsal foot	Latissimus dorsi + skin graft	Partial skin graft necrosis
7	48	F	1	Posterior lower leg	Scapular flap	Stable coverage
8	52	M	1	Big toe	Dorsalis pedis NVF	Stable coverage
9	8	M	1	Lateral ankle and dorsal foot	Groin flap	Stable coverage
10	72	F	1	Lateral ankle and lateral foot	Latissimus dorsi MCF	Stable coverage
11	61	M	2	Posterior heel, diabetic	Latissimus dorsi + skin graft	Flap necrosis. Cross leg flap
12	68	M	2	Entire heel	Radial forearm NVF	Stable protective coverage
13	78	M	2	Medial ankle and foot	Latissimus dorsi MCF	Stable coverage. Tumor recurrence
14	34	F	2	Medial ankle and sole of foot	Latissimus dorsi + skin graft	Stable coverage
15	69	M	3	Entire heel	Radial forearm NVF	Flap necrosis. Amputation.
16	73	M	3	Dorsal foot	Latissimus dorsi + skin graft	Stable coverage
17	48	M	4	Lower leg	Latissimus dorsi + skin graft	Stable coverage

MCF Musculocutaneous flap. NVF neurovascular flap

Figure 2. Case 8.



A contra lateral dorsalis pedis neurovascular free flap was elevated for the repair of the big toe defect.



Appearance of the donor site and the reconstructed big toe

flaps, such as the scapular, dorsalis pedis (Figure 2), rectus abdominis and the groin flap, were used in 1 case each (Table 1). The posterior or the anterior tibial vessels and the saphenous veins were used as recipient vessels, depending on the location of the defect. End-to-end or end-to-side anastomoses were used for arteries and end-to-end anastomoses were always used for veins. The sural nerve was used as a recipient nerve for suturing with the lateral cutaneous nerve of the radial forearm flap in 2 cases (Cases 12 and 15) to provide protective sensibility of the heel area. Immediate reconstruction was performed following all tumor resections and in the case (Case 2) with an opened knee joint. No regular anticoagulants were used in this series, with the exception of Cases 2 and 5 who were associated with severe avulsion injuries.

Results

As far as complications were concerned, we observed 2 partial skin graft necroses (Cases 3 and 6) which required debridement and regrafting. In addition, 2 flaps underwent necrosis (Cases 11 and 15) which was caused by venous thrombosis and required additional procedures. Follow-up was more than 4 years in all, except for 2 patients (Cases 1 and 4). Stable coverage was achieved with satisfactory functional results. Cosmetic results, on the other hand, were less satisfactory (Table 1).

Discussion

Lower limb reconstructive surgery has significantly improved and expanded with the use of microsurgical techniques. Evaluation of the recipient vessels is always of first priority (O'Brien 1987). The choice of the flap, particularly regarding the length and size of the pedicle and its bulk, is also very important in order to achieve a good result. Skin coverage of the foot has many peculiarities, especially the weight-bearing metatarsal head and heel regions which pose unique non-shearing and padding properties. Any reconstruction of these specialized zones of the foot requires replacement with a similar tissue. Depending on the location of the defect, the latissimus dorsi as muscle flap combined with a split thickness skin graft or as musculocutaneous flap is usually the flap of choice in lower leg soft tissue reconstruction because

of its size and the length of its pedicle (Bailey and Godfrey 1982).

The radial forearm neurovascular flap is indicated to repair areas of the foot, which needs protective sensibility. This flap can also be used to reconstruct an arterial deficiency in anterior lower leg defects as the radial artery courses through the flap. The dorsalis pedis flap can also be used as a neurovascular one (Case 8). The other flaps, such as the groin, scapular, and the rectus abdominis can be indicated for special defects. The particular choice of flap requires a balance between safety of transfer, aesthetics of the flap and acceptability of secondary defects. Delayed primary reconstruction following debridement and control of post-traumatic swelling was done in all of our trauma cases with the exception of Case 2, where the knee joint was opened. This is probably the only circumstance where emergency flap coverage was essential to prevent infection and desiccation of cartilaginous surfaces and to preserve joint function. Lower limb reconstructive microsurgery is a demanding, but often rewarding surgery, which requires correct patient selection, evaluation of the recipient vessels, flap choice and timing.

References

- Bailey B and Godfrey A. Latissimus dorsi muscle free flaps. *Br J Plast Surg* 1982; 35: 47-52
- O'Brien B and Morrison W. *Reconstructive Microsurgery*. Churchill Livingstone, New York 1987.