

Stem loosening more common with ITH than Lubinus prosthesis

A 5-year clinical and radiographic follow-up of 142 patients

Sven-Arne Jacobsson, Ingemar Ivarsson, Krister Djerf and Ola Wahlström

Out of a consecutive series of 169 cemented total hip arthroplasties, 77 Lubinus SP 2 and 65 ITH prostheses, were followed-up after 5 years with clinical and radiographic assessments. Radiolucencies were commoner around the ITH titanium stem than around the Lubinus cobalt-chrome stem. 6 of the ITH stems were considered as definitely loose, as

compared to none of the Lubinus stems. Hitherto, 5 patients in the ITH group have had revisions and 2 need revision because of loosening. The poorer performance of the cemented ITH stem may be due to an unfavorable combination of design and material properties.

Department of Orthopedics, University Hospital of Linköping, University Hospital, S-581 85 Linköping, Sweden
Tel +46 13-222000. Fax -224503
Submitted 94-12-13. Accepted 95-07-21

In 1986 we started to use a newly designed total hip prosthesis, the ITH (International Total Hip; Smith and Nephew Richards, Memphis, TN, U.S.A.), in order to lower our costs for THA. It was used parallel to the Lubinus SP Mark II, (Link, Hamburg, Germany) which we had used since 1985. The ITH prosthesis has a straight femoral component of titanium-aluminum-vanadium alloy. Because of the more elastic titanium alloy, it has been given a larger proximal volume to increase its strength against fatigue failure and to compensate for increased shear forces at the stem-cement interface. The broad intertrochanteric design might also increase rotational stability. These factors seemed favorable in regard to loosening. In contrast to the ITH, the Lubinus prosthesis has a femoral stem that is curved in two planes to fit the medullary canal. It is made of cobalt-chrome alloy.

To date, we have found no published study on results with the ITH prosthesis. We evaluated our 5-year results obtained using the ITH prosthesis, with emphasis on the performance of the femoral component, and compared them with those of the Lubinus prosthesis.

Patients and methods

During 1987, we performed 169 primary cemented total hip arthroplasties because of arthrosis (150) or rheumatoid arthritis (19). 2 prostheses were used, the new ITH (78) and the Lubinus SP Mark II (91). The

choice of prosthesis was made by the surgeon. 20 patients (10 ITH and 10 Lubinus) who died prior to the time of follow-up were excluded. In the ITH group, 1 patient was excluded because he refused to undergo a radiographic follow-up examination. 3 patients (2 ITH, 1 Lubinus) had a bilateral operation on 2 occasions in 1987 with the same type of prosthesis. Only their first-operated hip was included in the study. In the Lubinus group, 3 patients were revised because of infection. After exclusion of these cases, 142 arthroplasties, 65 ITH and 77 Lubinus, remained for the clinical and radiographic follow-ups. The patients in the ITH group were 71 (60–82) years of age and comprised 39 women and 26 men, and those in the Lubinus group were 68 (52–83) years of age and comprised 40 women and 37 men. The age difference was significant, p 0.03.

The stem of the ITH prosthesis was available in 5 sizes of varying length, 120–200 mm, and width. The Lubinus stem we used had 4 different sizes, all of the same length, 170 mm. Both prostheses had a 32 mm modular head of cobalt-chrome. The ITH stem had a small medial collar and the Lubinus a larger collar. None of the stems was provided with a centralizer.

The operations were performed with a standard dorsal approach. Conventionally ventilated as well as down-flow air system rooms were used. At that time, we used femoral plugging, retrograde filling of the cement (CMW® without gentamicin) and lavage. No pressurization or vacuum-mixing of the cement was used. Prophylactic intravenous antibiotics (dicloxa-

cillin) and subcutaneous heparin were administered. The patients received no routine prophylaxis against ectopic bone formation. Wound drainage was used for 1-2 days. The patients were mobilized on the day after the operation. A total of 23 surgeons performed 2-16 operations each, either alone or with the assistance of a more experienced colleague.

At the 5-year review, the patients underwent a clinical examination, including a Harris hip score (1969). Pain in the hip region was estimated by the patients using the visual analogue scale (maximum pain 100 mm). No statistical differences regarding these factors were found between the ITH and the Lubinus series (84 ± 15 points and 8 ± 11 mm, vs. 85 ± 16 points and 10 ± 15 mm). Nor did the 2 groups differ statistically regarding hospital stay (15 ± 6 vs. 14 ± 4 days) or occurrence of complications.

Standard anterior-posterior (AP) and lateral radiographs were obtained. The quality of the cementation in the AP view was graded according to Barrack et al. (1992) in 4 categories: A) representing a highly successful anchorage with so-called white-out at the cement-bone interface, and D) representing grossly defective cementation, with either a 100% radiolucency at the cement-bone interface or failure to fill the canal. The occurrence of direct stem-bone contact in the lateral view was also recorded. Varus/valgus was defined as ≥ 5 degrees from the neutral position. Any radiolucencies appearing since the first postoperative examination were measured in the AP plane in the different regions described by Gruen et al. (1979). Criteria of loosening were defined as: 1) the occurrence of a radiolucent line >2 mm around 50 percent or more of the component, 2) varus/valgus change of the stem, 3) any discernible radiolucency at the metal-cement interface, or 4) migration ≥ 5 mm. Ectopic bone formation, classified according to Brooker et al. (1973), showed no difference between the two groups.

Multiple regression analysis was used for statistical evaluation of the occurrence of radiolucencies. Group differences in continuous variables were tested, using the Student's *t*-test. Wilcoxon's rank sum test and Fischer's exact test were employed to analyze the qualitative data. Two-tailed tests were used throughout. $P < 0.05$ was considered significant.

Results (Table 1)

Direct bone-stem contact in the proximal anterior area of the femur was seen more often in the ITH group, 26 hips, than in the Lubinus group, 5 hips ($p < 0.001$). Failure to obtain a surrounding cement

mantle in the lateral view correlated to the occurrence of radiolucency, $p 0.03$. Varus positioning of the stem was found to be more common in the ITH group, 13/65 as compared to 1/77 ($p \leq 0.001$) in the Lubinus group. In the ITH group, a correlation was found between varus positioning and the shorter stem lengths which were used ($p \leq 0.001$), but not between varus positioning and radiolucency or loosening.

The ITH stem showed more frequent and more extensive surrounding radiolucencies than the Lubinus stem (Figure 1). The widths of the radiolucent lines in zones 1-7 were summed up for each patient. A significant difference emerged between the ITH and Lubinus groups, 3.1 ± 7.8 and 0.9 ± 1.7 mm, respectively ($p 0.02$). When the statistical analysis was adjusted for group differences concerning gender, age, weight, diagnosis and surgeon, the difference was still found to be significant ($p 0.02$; Table 2). 6 stems showed radiographic signs of loosening in the ITH group, all having migrated >5 mm. None of the Lubinus stems had signs of loosening ($p 0.016$).

The primary hospital expenses calculated per patient were SEK 3,000 lower (8%) for the ITH than for the Lubinus arthroplasty. As a consequence of the increased need for revision in the ITH group, the estimated total costs per patient over a 5-7-year period increased by SEK 7,000, i.e., 6% higher than those in the Lubinus group of patients (Table 3).

Discussion

Our 5-year results with the Lubinus prosthesis seem to be in line with those reported by Malchau et al. (1993). There are hitherto no studies published on the ITH prosthesis comparing its performance with other modern hip implant systems. Other prostheses with cemented titanium stems are reported as having a high rate of early loosening (Agins et al. 1988, Lombardi et al. 1989, Robinson et al. 1989, Witt and Swann 1991, Salvati et al. 1993, Ebramzadeh 1995). The ITH prosthesis has a modular head made of cobalt-chrome alloy, in contrast to titanium used in these series.

The different results with the 2 prostheses in our series may be explained by factors of design, by material or by statistical bias. We cannot draw any conclusions as to the specific effects of the former 2 factors, because the 2 femoral components differed both in design and material. The results using a straight, femoral titanium stem with a head of cobalt-chrome appear to be clearly less favorable than those obtained with the Lubinus prosthesis.

It should be pointed out that these different clinical

Legends Table 1.

A Code	3 infection	M Visual pain scale
B Gender	4 urinary tract	N Zone 1 (mm)
f female	5 cardiovascular	O Zone 2
m male	6 thrombosis	P Zone 3
C Days in hospital	7 miscellaneous	Q Zone 4
D Age at operation	8 pulmonary embolus	R Zone 5
E Diagnosis	H Stem position	S Zone 6
o osteoarthritis	0 ordinary	T Zone 7
r rheumatoid arthritis	1 varus	U Sum of zones 1-7
F Stem size	2 valgus	V HBF according to Brooker
1 Lub normal	I Quality of cementation	0 no
2 Lub small	1 white-out	1 islands
3 Lub large	2 slight radiolucency	2 > 1 cm
4 ITH 120 mm	3 extensive radiolucency	3 < 1 cm
5 ITH 140	4 defective cementation	4 bridging
6 ITH 160	J Direct bone-stem contact	W Stem-loosening
7 ITH 180	0 no	0 stable
8 ITH 200	1 yes	1 loose
G Complications	K Harris hip score	X Date of reoperation/revision
0 none	L Functional grade	Y Reason for reoperation
1 dislocation	1 unilateral	
2 nerve damage	2 bilateral	
	3 multiple joint disease	

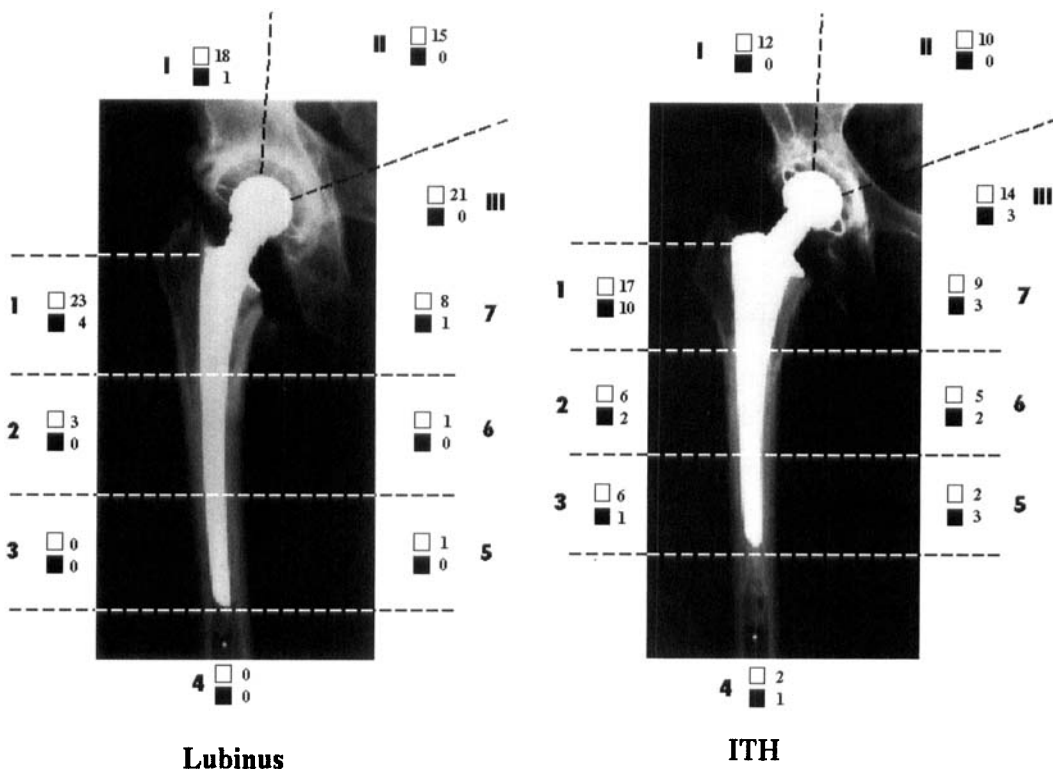


Figure 1. Radiolucent lines in the zones described by Gruen et al. White square 1-2 mm and black square >2 mm.

results were not obtained in a controlled, randomized study. The choice of prosthesis for each patient was made individually by the surgeon, which might have led to a selection bias. We found no difference between the Lubinus and ITH groups as to the quality of cementation. The same technique was used for both prostheses. The combination of a broad proxi-

mal design and a straight form, without any centralizing devices, seems to make the ITH stem more likely to come into direct contact with the femur in the proximal/anterior area, despite the reaming procedure. This defective cement mantle may have contributed to the high rate of early stem loosening of the ITH prosthesis.

Table 2. Multiple regression analysis of various factors and the occurrence of radiolucency around the femoral component. The variability due to different surgeons being involved in the study is accounted for in the regression model. The analysis indicated less tendency to develop radiolucent lines in females (0.3 mm), in elderly patients (0.1 mm per year of age), in patients with osteoarthritis (2.1 mm), and in patients with the Lubinus stem (1.6 mm). A young patient and a patient with an ITH stem were significantly more likely to develop radiolucent lines (*)

	Coefficient	P-value
Gender	-0.332	0.631
Age	-0.129	0.025*
Weight	0.009	0.765
Diagnosis	-2.072	0.109
Prosthesis	-1.561	0.018*

Table 3. Estimated costs (SEK; 1992) in the series of ITH and Lubinus arthroplasties. Figure in parentheses indicates the accumulated costs calculated per patient over a 5-7 year period, including the 7 patients in need of revision surgery due to aseptic loosening

Primary THA - ITH	51,013	(58,336)
- Lubinus	55,030	
Revision surgery	68,000	

When the results were adjusted for group differences related to gender, age, weight, diagnosis and surgeon, the difference in radiolucencies between the 2 types of prosthesis was still significant. Other kinds of bias not accounted for in the regression analysis might have been introduced by other criteria of selection. However, we found no plausible explanation for the different outcomes other than the differences in design and material.

Joint prosthetic loosening has many causes. Varus positioning of the ITH stem did not correlate statistically with loosening. Carlsson and Gentz (1980) also failed to demonstrate any influence of this stem's malpositioning with the Charnley prosthesis. Generation of particulate debris from cement and prosthetic surfaces, both plastic and metallic, is another important cause of loosening. The wear debris induces a biologic response, characterized by recruitment of macrophages and release of potent inflammatory mediators, which leads to progressive bone resorption (Lombardi et al. 1989, Ohlin et al. 1990, Amstutz et al. 1992, Horowitz et al. 1993). Titanium alloys belong to the most biocompatible materials, but can be particularly susceptible to fretting wear, and thus generate metallic debris that might promote aseptic loosening of the implant (Akins et al. 1988, Salvati et al. 1993). In the case of

loosening, a titanium stem used in combination with cement might cause severe abrasion between the cement mantle and the stem (Buly et al. 1992). This may cause high levels of metal in the periprosthetic tissues (Brien et al. 1992). In our study, 3 cases showed disruption of the stem-cement interface. Serious concern regarding the use of relatively elastic titanium-alloy implants in combination with cement has been expressed (Brien et al. 1992, Salvati et al. 1993). Further, Collier et al. (1992) pointed out the risk of galvanically-accelerated crevice corrosion between a modular head of cobalt-chromium alloy and a stem of titanium alloy. The titanium-oxide particles, formed either through abrasive or corrosional wear, are very stable and may act as three-body abrasives, thus increasing the wear of the bearing surfaces (Davidson 1993).

Rapidly increasing implant costs have been highlighted recently (Clark 1994, Healy and Finn 1994, Zuckerman et al. 1994). One reason for our use of the ITH prosthesis was to reduce hospital costs for THA. We have learned that a cheaper product does not necessarily reduce the total costs.

Although the factory documentation of the technical quality of the ITH prosthesis was satisfactory, the clinical results obtained in our study were unacceptable. This emphasizes the importance of follow-up of any new system for routine use and of not introducing new designs on the market without sufficient clinical documentation. Central registers are important for gathering clinical results, so that products of lower quality can be sorted out at an early stage.

References

- Akins H J, Alcock N W, Bansal M, Salvati E A, Wilson P D, Pellicci P M, Bullough P G. Metallic wear in failed titanium-alloy total hip replacements. A histological and quantitative analysis. *J Bone Joint Surg (Am)* 1988; 70 (3): 347-56.
- Amstutz H C, Campbell P, Kossovsky N, Clarke I C. Mechanism and clinical significance of wear-debris-induced osteolysis. *Clin Orthop* 1992; 276: 7-18.
- Barrack R L, Mulroy Jr R D, Harris W H. Improved cementing techniques and femoral component loosening in young patients with hip arthroplasty. A 12-year radiographic review. *J Bone Joint Surg (Br)* 1992; 74 (3): 385-9.
- Brien W W, Salvati E A, Betts F, Bullough P, Wright T, Rimnac C, Buly R, Garvin K. Metal levels in cemented total hip arthroplasty. A comparison of well-fixed and loose implants. *Clin Orthop* 1992; 276: 66-74.
- Brooker A, Bowerman J W, Robinson R A, Riley H L. Ectopic ossification following total hip replacement. Incidence and a method of classification. *J Bone Joint Surg (Am)* 1973; 55 (8): 1629-32.

- Buly R L, Huo M H, Salvati E A, Brien W, Bansal M. Titanium wear-debris in failed cemented total hip arthroplasty. An analysis of 71 cases. *J Arthroplasty* 1992; 7: 315-23.
- Carlsson Å S, Gentz C F. Mechanical loosening of the femoral head prosthesis in the Charnley total hip arthroplasty. *Clin Orthop* 1980; 147: 262-70.
- Clark C R. Editorial. Cost containment: total joint implants. *J Bone Joint Surg (Am)* 1994; 76 (6): 799-800.
- Collier J P, Surprenant V A, Jensen R E, Mayor M B, Surprenant H P. Corrosion between the components of modular femoral hip prostheses. *J Bone Joint Surg (Br)* 1992; 74 (4): 511-7.
- Davidson J A. Characteristics of metal and ceramic total hip-bearing surfaces and their effect on long-term ultra-high molecular weight polyethylene wear. *Clin Orthop* 1993; 294: 361-78.
- Ebramzadeh E. On factors affecting the long-term outcome of total hip replacement. Thesis, Biomaterials Group, University of Gothenburg, Sweden 1995.
- Gruen T A, McNiece G M, Amstutz H C. "Modes of failure" of cemented stem-type femoral components. A radiographic analysis of loosening. *Clin Orthop* 1979; 141: 17-27.
- Harris W H. Traumatic arthritis of the hip after dislocation and acetabular fractures: treatment by mold arthroplasty. *J Bone Joint Surg (Am)* 1969; 51 (4): 737-55.
- Healy W L, Finn D. The hospital cost and the cost of the implant for total knee arthroplasty. *J Bone Joint Surg (Am)* 1994; 76 (6): 801-6.
- Horowitz S M, Doty S B, Lane J M, Burstein A H. Studies of the mechanism by which the mechanical failure of polymethylmethacrylate leads to bone resorption. *J Bone Joint Surg (Am)* 1993; 75 (6): 802-24.
- Lombardi A V, Mallory T H, Vaughn B K, Drouillard P. Aseptic loosening in total hip arthroplasty secondary to osteolysis induced by wear debris from titanium-alloy modular femoral heads. *J Bone Joint Surg (Am)* 1989; 71 (9): 1337-42.
- Malchau H, Herberts P, Ahnfelt L. Prognosis of total hip replacement in Sweden. Follow-up of 92,675 operations performed 1978-1990. *Acta Orthop Scand* 1993; 64 (5): 497-506.
- Ohlin A, Johnell O, Lerner U H. The pathogenesis of loosening of total hip arthroplasties. The production of factors by the periprosthetic tissues that stimulate in vitro bone resorption. *Clin Orthop* 1990; 253: 287-96.
- Robinson R P, Lovell T P, Green T M, Bailey G A. Early femoral component loosening in DF-80 total hip arthroplasty. *J Arthroplasty* 1989; 4 (1): 55-64.
- Salvati E A, Betts F, Doty S B. Particulate metallic debris in cemented total hip arthroplasty. *Clin Orthop* 1993; 293: 160-73.
- Witt J D, Swann M. Metal wear and tissue response in failed titanium alloy total hip replacements. *J Bone Joint Surg (Br)* 1991; 73 (4): 559-63.
- Zuckerman J D, Kummer F J, Frankel V H. The effectiveness of a hospital-based strategy to reduce the cost of total joint implants. *J Bone Joint Surg (Am)* 1994; 76 (6): 807-11.