

Technical note

Congenital hip dislocation and subtrochanteric pseudoarthrosis

Hip replacement based on computer-aided analysis

Alexandros E Beris, Ioannis D Gelalis, Theodore A Xenakis,
Alexandros N Mavrodontidis and Panayotis N Soucacos

Department of Orthopaedic Surgery, University of Ioannina, School of Medicine, Ioannina 45100, Greece
Tel +30 651-45 731. Fax -46 222
Submitted 96-01-14. Accepted 96-09-16

A 57-year-old woman with neglected high congenital dislocation of the right hip (Figure 1) and a severe dysplasia of the left hip had progressive pain in both hips, leg-length discrepancy and limitation of motion. On the right side there was a subtrochanteric pseudoarthrosis after an osteotomy performed when the patient was 10 years of age.

The patient was admitted to our department and the physical examination revealed a healthy woman, 75 kg, 167 cm tall. On the d'Aubigné and Postel scale (1954), pain was 3, range of motion 2 (60°) and walking capacity 3. Radiographs of the lumbar spine disclosed degenerative changes and hyperlordosis secondary to an anterior pelvic tilt. The right leg was 4 cm longer than the left (scanography).

A CT scan of the right hip and proximal right femur was obtained using a Philips Tomoscan LX whole-body scanner (2.9 sec. scanning time, 0° angle of the gantry).

Continuous transverse 5 mm slices were obtained through the true acetabulum to the level of the lesser trochanter. At that point, the scans were spaced at 10 mm increments to a level approximately 12 cm below the lesser trochanter.

Scans through the true acetabulum were used to determine its dimensions by measuring anteversion (25°), its depth (19 mm), and the diameter available for the acetabular implant (40 mm).

The CT scans of the proximal femur were used for the Computer-Aided Design (CAD) process. Initially, the CT image data were transferred into the computer workstation from a data diskette. The inner and outer contours of the bone in each CT slice were determined, using a system of points and by marking the x, y coordinates into the software of a computer (Risc

system 6000; IBM). With the aid of the computer program CATIA (Computer-Aided Three-dimensional Interactive Analysis) (CAD/CAM/CAE; Computer-Aided Design/Computer-Aided Manufacturing/Computer-Aided Engineering) (Technical Scientific Transfer, LTD), the proximal femur was reconstructed in 3 dimensions, so that a surface and solid model could be created.

By creating the 3D model of the proximal femur, the angulation and rotation of the proximal and distal parts of the area of the pseudoarthrosis could be determined by a two-axes grid (x, y axis) and a z axis for the orientation of the femur which were obtained from the CT data. A simulated osteotomy at an angle of 20° to the 3 D model was performed at the area of the pseudoarthrosis by removing an exact amount of bone (4 cm), so that the alignment of the proximal femur and the leg-length discrepancy could be restored (Figure 2).

When the computer model of the femur had been prepared, a computer-assisted implant selection was performed from a group of 6 standard femur cementless prostheses which were analyzed graphically and installed in the software of the computer. A conical prosthesis that provided good implant bone apposition, while requiring only minimal bone removal, was selected. A Wagner (Protek) prosthesis (190mm/18mm) had the best contact with the bone at the proximal and distal parts of the femur.

The CT findings for the true acetabulum and the information obtained from the CAD analysis were confirmed at surgery. The CAD preselected femoral prosthesis, without cement, was used. According to the acetabular dimensions, a noncemented acetabular component Duralock 44 mm (Depui) was installed.

After positioning of the acetabulum, prior to implantation of the femoral component, derotation and shortening osteotomy at the level of the subtrochanteric pseudarthrosis were performed. Derotation of the proximal part was required to restore the anatomic position of the greater trochanter, which was located posteriorly due to the malunion of the previous subtrochanteric osteotomy.

Postoperatively, the patient had a painless hip, range of motion was improved from 2 to 4 (flexion 90° , internal and external rotation 20° , adduction 10° , abduction 20°), walking capacity from 3 to 5 and the leg-length discrepancy was abolished.

At 2 years' follow-up, radiographs show solid healing of the subtrochanteric osteotomy, with satisfactory orientation of the acetabular and femoral components (Figure 3). The patient is free from pain and has markedly improved walking ability.

Discussion

In joint replacement surgery, the selection of standard artificial joint replacements for individual patients and the design and manufacture of custom-made prostheses are the two principal areas of application of 3-dimensional reconstructions from CT data (Reuben et al 1992, Sutherland et al. 1994, Thomas et al 1986, Murphy et al. 1986, 1988, Bargar 1989, Xenakis et al. 1995).

The wide spectrum of pathologic anatomy found in a dislocated hip makes its treatment with a total hip replacement difficult (Hartofilakides et al. 1988, Xe-

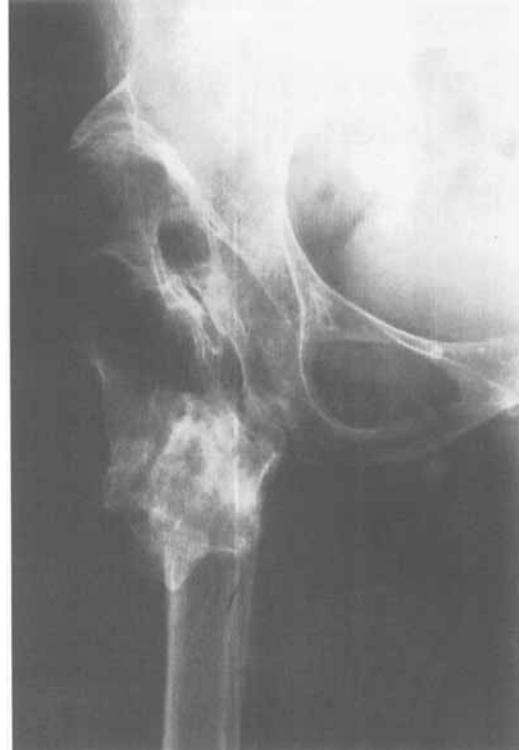

Figure 1. Preoperatively. High congenital dislocation of the right hip associated with a subtrochanteric pseudarthrosis.

nakis et al. 1995). One of the main problems is to choose the optimal femoral implant and to determine its fit and location preoperatively.

In our case, the preoperative planning and surgical

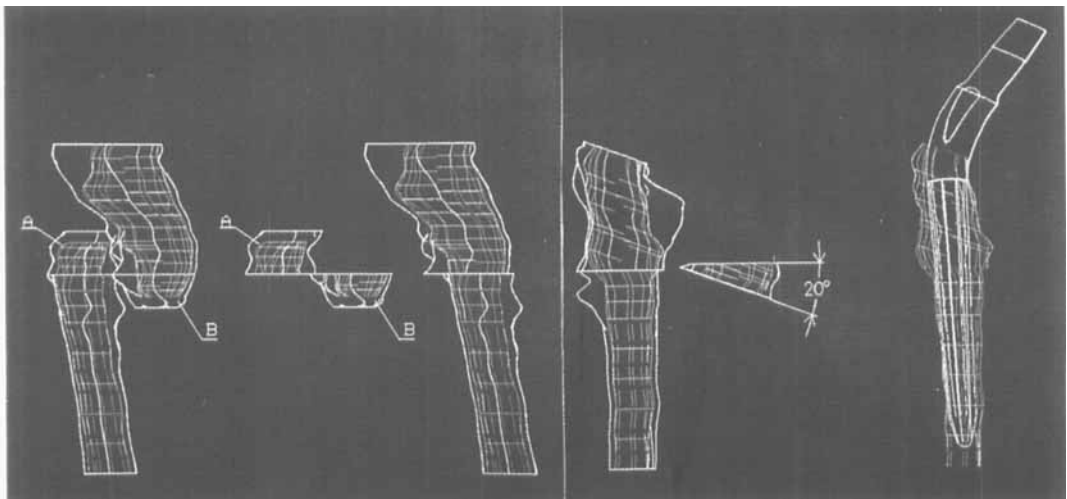


Figure 2. 3 D computer models of the proximal femur. Simulated osteotomy (parts A and B were removed) of the pseudoarthrosis. Simulated angulation osteotomy (20°) of the prepared 3 D computer model and simulated implantation of the selected femoral prosthesis (the outer contour of the bone has been removed during the simulated implantation).

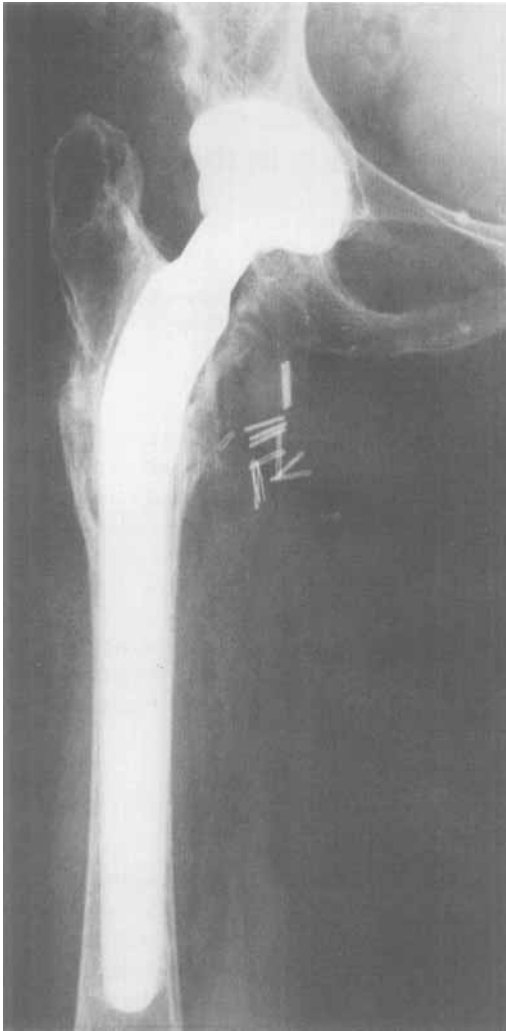

Figure 3. 2 years after surgery.

correction were complex. The main problems included: 1) correct placement of an optimally-sized acetabular component at the true acetabulum, 2) derotation and shortening osteotomy at the level of the subtro-

chanteric pseudoarthrosis and 3) alignment of both parts, proximal and distal to the osteotomy, restoring the axis of the femur. By using the described preoperative planning, we easily dealt with these problems intraoperatively.

With the aid of CT and CAD, we could predetermine the technical problems described by creating a surgical plan graphically and achieving the desired objective by restoring the mechanics of the diseased hip.

References

- Bargar L W. Shape the implant to the patient. A rationale for the use of custom-fit cementless total hip implants. *Clin Orthop* 1989; 249: 73-8.
- d'Aubigné R M, Postel M. Functional results of hip arthroplasty with acrylic prosthesis. *J Bone Joint Surg (Am)* 1954; 36: 451-76.
- Hartofilakidis G, Stamos K, Ioannidis T. Low-friction arthroplasty for old untreated congenital dislocation of the hip. *J Bone Joint Surg (Br)* 1988; 70: 182-6.
- Murphy B S, Kijewski K P, Simon R S, Chandler P H, Griffin P P, Reilly T D, Penenberg L B, Landy M M. Computer-aided simulation, analysis and design in orthopaedic surgery. *Orthop Clinics N Am* 1986; 17 (4): 637-49.
- Murphy B S, Kijewski K P, Millis B M, Hall E J, Simon R S, Chandler P H. The planning of orthopaedic reconstructive surgery, using computer-aided simulation and design. *Comput Med Imaging Graph* 1988; 12 (1): 33-44.
- Reuben D J, Chang H C, Akin E J, Lionberger R D. A knowledge-based computer-aided design and manufacturing system for total hip replacement. *Clin Orthop* 1992; 285: 48-56.
- Sutherland J C, Bresina J S, Gayou E D. Use of general-purpose mechanical computer-assisted engineering software in orthopaedic surgical planning. Advantages and limitations. *Comput Med Imaging Graph* 1994; 187 (6): 435-42.
- Thomas J B, Salvati A E, Small D R. The CAD hip arthroplasty. *J Bone Joint Surg (Am)* 1986; 68: 640-6.
- Xenakis T, Gelalis J, Mavrodontidis A, Vartziotis D, Vartziotis C, Tatsis C. CT-CAD preoperative study and planning of a total hip replacement in neglected congenital dislocation of the hip. *Acta Orthop Hellenica* 1995; 46 (3): 187-94.