

With our method, correction of soft-tissue balance is unnecessary, and a standard tibial component can be used.

## References

Brand M G, Daley R J, Ewald F C, Scott R D. Tibial tray augmentation with modular metal wedges for tibial bone stock deficiency. *Clin Orthop* 1989; 248: 71-9.

Krackow K A, Holtgrewe J L. Experience with a new technique for managing severely overcorrected valgus high tibial osteotomy at total knee arthroplasty. *Clin Orthop* 1990; 258: 213-24.

Windsor R E, Insall J N, Vince K G. Technical considerations of total knee arthroplasty after proximal tibial osteotomy. *J Bone Joint Surg (Am)* 1988; 70 (4): 547-55.

## 3 deep-seated glomus tumors in the lower arm

Hitoshi Kogure, Kenji Shirakura, Nobuyoshi Arisawa, Tetsuo Aramaki and Atsushi Shimegi

Department of Orthopedic Surgery, Gunma University School of Medicine, 3-39-22 Showa-machi, Maebashi-shi, Gunma-ken, Japan 371. Tel +81 272 20-7111. Fax -8275  
Submitted 95-07-17. Accepted 95-10-28

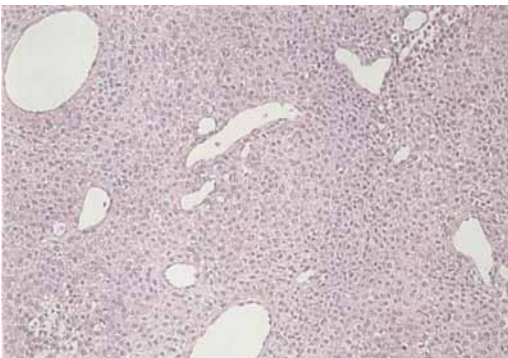
A 34-year-old right-handed man had a 10-year history of tenderness on the ulnar dorsal aspect of the left wrist and on the dorsal aspect just distal to the elbow. No mass could be felt. Pronation was restricted by 20 degrees because of pain. Laboratory examinations, plain radiographs and angiographs were normal. The pain disappeared temporarily after the injection of a local anesthetic agent.

Exploratory incisions over the tender spots were performed under local anesthesia. Distally, between the extensor carpi ulnaris tendon and the extensor digitorum communis tendon, a 1 × 1.5 cm dark red mass covered with connective tissue was found. It had 3 draining vessels which were coagulated and the mass was excised. Proximally, between the ulna and the flexor carpi ulnaris muscle, there was a 1 × 2 cm yellowish

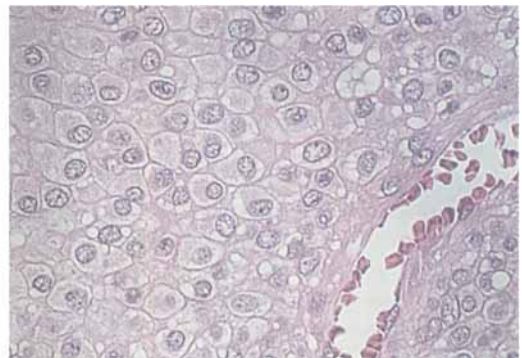
encapsulated mass with 3 draining vessels, which was excised. Light microscopy revealed similar findings in the 2 tumors. They consisted of sheets of uniform polygonal to round cells with distinct cell boundaries. The cell bodies were eosinophilic-stained and/or water-bubbled, and the nuclei were round or oval. There were many capillary-sized vessels surrounded by plump, regular-appearing cells within these tumors. The tumors were considered to be glomus tumor proper, in accordance with Enzinger's subclassification (Enzinger and Weiss 1983).

3 months after the first operation, another tender point appeared about 6 cm proximal to the wrist crease, just under the flexor carpi ulnaris tendon. Exploration 1 year after the first operations revealed a yellowish smooth-surfaced mass in the muscle bellies

Light microscopic findings of the tumor resected at first operation.



Solid sheets of cells interrupted by vessels of varying sizes are shown (HE, × 120).



The cell body is eosinophilic-stained and/or water-bubbled, and the nucleus is round or oval, large, and sharply punched out (HE, × 560).

of the flexor digitorum profundus. The mass was about  $0.5 \times 1$  cm and was marginally excised. Light microscopy revealed that it was the same type of tumor as in the first operation. 6 months after the second operation, the pain had disappeared completely.

## Discussion

The normal glomus body is a specialized form of an arteriovenous shunt concerned with thermal regulation, that is located throughout the body, being especially common on the distal parts of the extremities. Glomus tumors are most often encountered in the subungual region, the digit, and the palm, and are considered to be a hyperplasia of a normal glomus body. They are most often solitary. The incidence of multiple tumors in adults has been reported in up to 25% of cases (Kohout and Stout 1961, Shugart 1963, Maxwell et al. 1979, Heys et al. 1992). In many cases, an autosomal dominant pattern of inheritance has been noted (Conant and Wiesenfeld 1971). In our case, there was no family history of glomus tumors.

Ectopic occurrence of this tumor outside the dermis or subcutaneous tissue has rarely been detected (Tang et al. 1978, Rozmaryn et al. 1987, Kline et al. 1990). Deep-seated tumors, intra- or extramuscular, without the normal glomus apparatus, have not been reported before.

On the basis of certain morphological similarities found in tissue cultures and the patterns of distribution, the cell of origin of glomus tumors was originally considered to be a pericyte. Recently, more extensive electron microscopic and histochemical studies of glomus tumor cells, however, have found more

similarities with the smooth muscle myocyte (Goodman and Abele 1971, Tsuneyoshi and Enjoji 1982). A hypothesis accounting for this problem considers the myocyte, pericyte and glomus cell as separate entities, but interrelated cell types (Enzinger and Weiss 1983). The occurrence of ectopic glomus tumors where normal glomus bodies may not be present would support this theory.

## References

- Conant M A, Wiesenfeld S L. Multiple glomus tumors of the skin. *Arch Dermatol* 1971; 103: 481-5.
- Enzinger F M, Weiss S W. *Soft-tissue tumors*. The C.V. Mosby Company, St Louis 1983; 450-62.
- Goodman T F, Abele D C. Multiple glomus tumors. *Arch Derm* 1971; 103: 11-23.
- Heys S D, Britenden J, Atkinson P, Eremin O. Glomus tumor: an analysis of 43 patients and review of the literature. *Br J Surg* 1992; 79: 345-7.
- Kline S C, Moore J R, deMente S H. Glomus tumor originating within a digital nerve. *J Hand Surg (Am)* 1990; 15 (1): 98-101.
- Kohout E, Stout A P. The glomus tumor in children. *Cancer* 1961; 14: 555-66.
- Maxwell G P, Curtis R M, Wilgis E F S. Multiple digital glomus tumors. *J Hand Surg* 1979; 4 (4): 363-7.
- Rozmaryn L M, Sadler A H, Dorfman H D. Intraosseous glomus tumor in the ulna. *Clin Orthop* 1987; 220: 126-9.
- Shugart R R, Soule E H, Johnson E W Jr. Glomus tumor. *Surg Gynecol Obstet* 1963; 117: 334-40.
- Tang C K, Toket C, Foris N P, Trump B F. Glomangioma of the lung. *Am J Surg Pathol* 1978; 2: 103.
- Tsuneyoshi M, Enjoji M. Glomus tumor: a clinicopathologic and electron microscopic study. *Cancer* 1982; 50: 1601-7.