

# Trochanteric hip fractures

## Fixation failure commoner with femoral medialization, a comparison of 101 cases

Martyn J Parker

The radiographic characteristics of 27 patients with a trochanteric fracture treated with a sliding hip screw in which fixation failure occurred, were compared with 74 cases having uneventful fracture union. Femoral medialization was commoner in specific fracture types, particularly if there was comminution of the lateral femoral cortex at the site of in-

sertion of the lag screw. Femoral medialization was strongly associated with fixation failure, with a 7-fold increase in the risk of failure if medialization at more than one third occurred. These observations indicate that the value of implants preventing femoral medialization in specific types of trochanteric fracture merit further evaluation.

Department of Orthopedics, Peterborough District Hospital, Peterborough PE3 6DA, UK. Tel +44 733-874000. Fax -891082  
Submitted 95-11-20. Accepted 96-04-28

Femoral medialization refers to the medial displacement of the distal fracture surfaces in relationship to the proximal fragment, during the healing of a trochanteric hip fracture. The sliding hip screw (SHS) has a sliding action that allows for collapse at the fracture site, but with specific fracture configurations, the SHS will also allow femoral medialization to occur.

Femoral medialization results in a reduced area of bone-to-bone contact at the fracture surfaces, which may delay fracture healing (Figure 1). Other possible adverse effects are due to the excessive slide of the SHS that occurs with medialization and can cause the SHS to run out of slide, with subsequent fixation failure. Furthermore, the increased movement at the fracture surface may increase the pain and shorten the limb.

Recently, new implants have been developed for trochanteric hip fractures which prevent medialization. However, no study has determined the incidence and degree of femoral medialization or whether it is associated with an increased risk of fixation failure. Furthermore, no study has determined which of the different fracture configurations will allow medialization to occur. This study concerns these issues.

### Patients and methods

From a consecutive series of 1,039 patients with an extracapsular hip fracture treated with a SHS, the radiographic characteristics of those patients who developed fixation failure were studied. These radiographs were reviewed and compared with those of the

last 100 patients treated in which a minimum of 90 days radiographic follow-up was achieved. 30 radiographs were not available for review, leaving 27 cases of fixation failure and 74 cases of uneventful fracture union. Fixation failure was defined as cut-out of the implant from the femoral head or detachment of the plate from the femur.

Fractures were subdivided into 7 types (Figure 2). For the purpose of this study, the term pertrochanteric

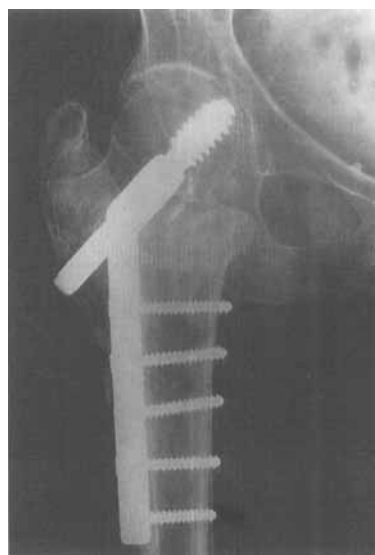

Figure 1. Femoral medialization occurring in a trochanteric fracture, in which the lag screw was inserted directly into the fracture site. The distal femur has displaced medially, reducing the area of bone-to-bone contact at the fracture site and the lag screw has run out of slide.

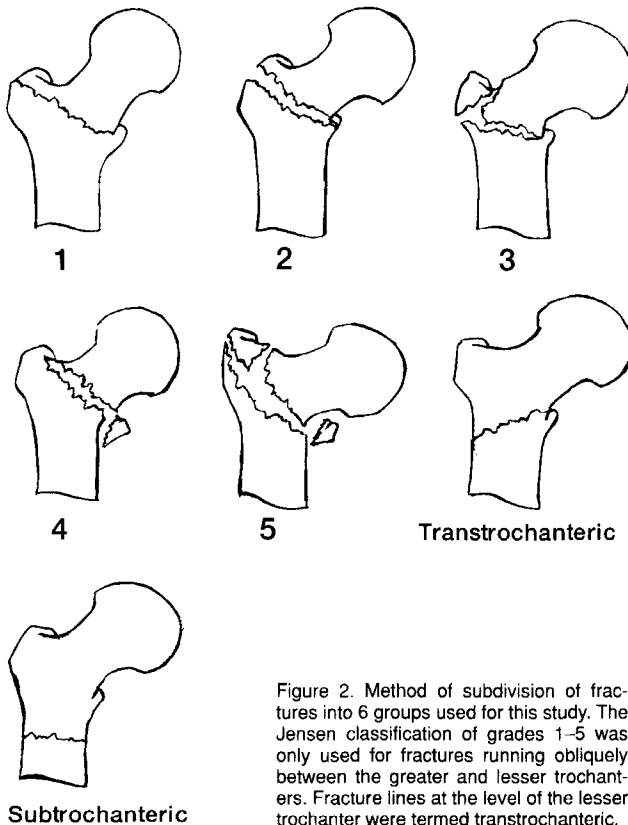


Figure 2. Method of subdivision of fractures into 6 groups used for this study. The Jensen classification of grades 1-5 was only used for fractures running obliquely between the greater and lesser trochanters. Fracture lines at the level of the lesser trochanter were termed transtrochanteric.

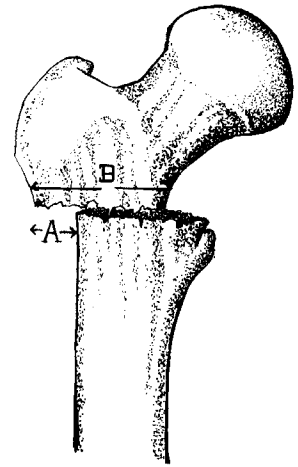


Figure 3. Method of measuring femoral medialization.

fracture was used exclusively for fracture lines running obliquely in an inferior medial direction, from the greater to the lesser trochanter. These fractures were classified according to Jensen (1980). Transtrochanteric fractures were defined as those cases in which the fracture line traversing the femur was predominantly situated at the level of the lesser trochanter. These fractures were generally transverse or of a reversed fracture line type (Wright 1947). While such transtrochanteric fractures can be subdivided by the method described by Jensen, for the purpose of this study they were classified into a separate group. Subtrochanteric fractures were defined as cases in which the fracture line traversing the femur was mainly within the 5 cm of femur distal to the lower margin of the lesser trochanter.

In addition, an assessment was made on the preoperative radiographs to determine whether the fracture line involved the lateral femoral cortex at the site of insertion of the lag screw. Postoperative radiographs were used to determine the occurrence of fixation failure and the extent of femoral medialization (Figure 3).

## Results

For the 74 patients with uneventful fracture union, 34 had no medialization and 10 had more than one third medialization. Among patients with fixation failure, only 4 had no medialization and 21 had more than 30% medialization. Statistically, the difference in the medialization between these two groups was highly significant ( $p < 0.0001$ , Mann-Whitney U test).

The incidence of fixation failure for fractures which had no medialization was 4/51 cases. For the 15 patients with between 1-30% medialization, the incidence of fixation failure was 2/15. When the degree of medialization was between 31-60%, fixation failure occurred in 14/25 of cases. For medialization of 61-90%, failure occurred in 4/6 of cases and in the 3 cases of medialization exceeding 90%, fixation failure occurred in all cases.

Medialization was commonest in Jensen type 4 and 5 fractures, and in transtrochanteric fractures (Table 1). Using fracture comminution at the lag screw insertion site, 48/83 of fractures were correctly predicted as not medializing, but in 15/18 of fractures, femoral medialization was correctly predicted.

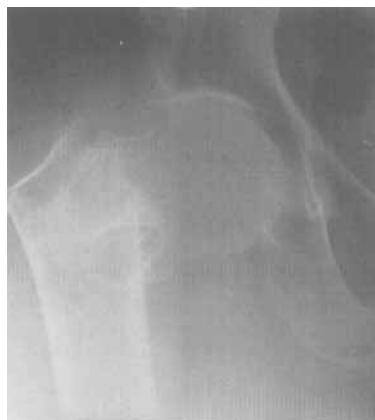**Table 1.** Comparison of the fixation failures against cases without fixation failure (controls) related to the different fracture types, the mean degree of medialization (%) and number of cases with some degree of medialization and exceeding 30% medialization (fraction)

	Number patients	Medialization		
		Mean	Any	> 30%
<i>All fractures</i>				
Failures	27	12	23 (0.9)	22 (0.8)
Controls	74	47	26 (0.4)	13 (0.2)
Total	101	21	49 (0.5)	35 (0.4)
<i>Pertrochanteric fractures</i>				
<i>Undisplaced 2-part (1)</i>				
Failures	0	–	–	–
Controls	10	1	1 (0.1)	0
<i>Displaced 2-part (2)</i>				
Failures	1	0	0	0
Controls	12	10	3 (0.3)	2 (0.2)
Total	13	10	3 (0.2)	2 (0.2)
<i>3-part loss lateral support (3)</i>				
Failures	3	20	2 (0.7)	1 (0.3)
Controls	12	8	4 (0.3)	1 (0.1)
Total	15	11	6 (0.4)	2 (0.1)
<i>3-part loss medial support (4)</i>				
Failures	5	43	4 (0.8)	4 (0.8)
Controls	7	8	2 (0.3)	1 (0.1)
Total	12	23	6 (0.5)	5 (0.4)
<i>4-part fracture (5)</i>				
Failures	15	58	13 (0.9)	13 (0.9)
Controls	24	18	12 (0.5)	7 (0.3)
Total	39	33	25 (0.6)	20 (0.5)
<i>Transtrochanteric</i>				
Failures	3	47	3 (1)	3 (1)
Controls	3	19	2 (0.7)	0
Total	6	29	5 (0.8)	3 (0.5)
<i>Subtrochanteric</i>				
Failures	0	–	–	–
Controls	6	22	4 (0.7)	3 (0.5)
<i>Fracture line at site of lag screw insertion</i>				
Failures	10	52	9 (0.9)	8 (0.8)
Controls	8	26	6 (0.8)	5 (0.6)
Total	18	41	15 (0.8)	13 (0.7)

## Discussion

Most extracapsular fractures show no medialization. This is because the fracture lines run obliquely between the trochanters, and while some collapse can occur at the fracture site, medial displacement is prevented by the intact bone of the superior-lateral part of the distal fragment resting against the proximal fragment. The fracture pattern that was the most reliable predictor of the occurrence of medialization was comminution of the lateral femoral cortex at the site of insertion of the lag screw. These fracture patterns signify a lack of lateral bony support to oppose the strong pull of the adductor muscles on the distal fragment, thereby allowing the distal fragment to displace medially.

Direct insertion of the lag screw into the fracture site occurred in most transtrochanteric fractures and



**Figure 4.** An intertrochanteric fracture in which there is comminution of the lateral femoral cortex at the site of insertion of the lag screw.

some high subtrochanteric fractures. In addition, some of the pertrochanteric fractures had comminution extending distally from the greater trochanter to the level of the insertion of the lag screw (Figure 4). This fracture pattern is similar to that classified as a Type II trochanteric fracture by May and Chacha (1968) or as internal rotation fractures by Pogrud et al. (1987). In addition to comminution of the lateral femoral cortex, these fractures frequently have a short horizontal proximal fragment and angulation of the fracture on the lateral radiograph. Both previous studies on this type of fracture had noted a high risk of fixation failure.

Although specific fracture types were associated with medialization, it was not possible to predict medialization with complete certainty. The reason for this may be due to changes in the fracture configuration occurring at the time of surgery. If the lateral femoral cortex is weak, it may fracture at the time of reaming for the SHS lag screw, or occasionally further comminution of the fracture may occur in the postoperative period, which results in medialization.

We used cut-out of the lag screw and detachment of the plate from the femur as indicators of fixation failure. Fixation failure for other reasons is exceptionally rare with the SHS (Parker 1993). Cut-out of the lag screw is strongly associated with malpositioning of the lag screw (Davis et al. 1990, Parker 1992, Baumgaertner et al. 1995). However, not all incorrectly placed lag screws will cut out, which indicates that other factors should be considered. This study demonstrates that fracture configuration and femoral medialization contribute significantly to the risk of cut-out.

The fracture patterns that allow femoral medialization are similar to those created by a medial displace-

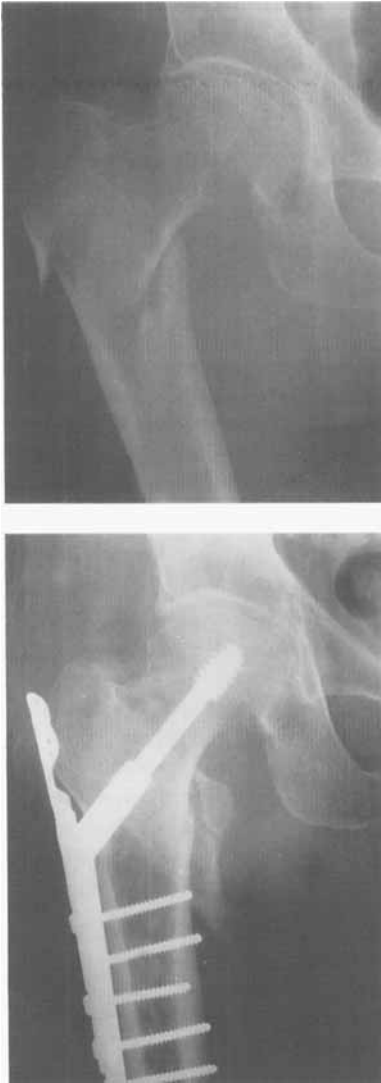

Figure 5. An intertrochanteric fracture where the fracture line is at the level of the lesser trochanter. A SHS supplemented with a trochanteric stabilizing plate has been used which prevents any medial displacement of the distal fragment by resting against the greater trochanter.

ment osteotomy. Medial displacement osteotomy has been used with the SHS fixation of trochanteric fractures and found to be detrimental, with a greatly increased risk of fixation failure (Nunn 1988, Gargan et al. 1994). Our study provides further evidence of the potential disadvantages of medial displacement osteotomy.

Recent developments in implants for trochanteric fractures have resulted in a number of newer implants that prevent femoral medialization. Intramedullary

nails, such as the Gamma nail (Howmedica), prevent medialization due to the proximal part of the nail being in direct contact with the proximal fracture. The trochanteric stabilizing plate (Stratec Medical) resists medialization by resting against the greater trochanter (Figure 5). The Medoff plate (Medoff and Maes 1991) will resist medialization, if the locking mechanism is used to prevent sliding along the line of the lag screw. The Resistance-Augmented Baixauli (RAB) plate (Uhlen et al. 1995) has an oblique strut, which is placed within the femoral neck just touching the calcar and thereby preventing medialization.

Our study indicates that femoral medialization is more prevalent in specific fracture types and is closely associated with SHS fixation failure. Further studies are required to indicate whether these specific fracture types are better treated with an implant that resists medialization.

## References

- Baumgaertner M R, Curtin S L, Lindskog D M, Keggi J M. The value of the tip-apex distance in predicting failure of fixation of pertrochanteric fractures of the hip. *J Bone Joint Surg (Am)* 1995; 77: 1058-64.
- Davis T R C, Sher J L, Horsman A, Simpson M, Porter B B, Checketts R G. Intertrochanteric femoral fractures: mechanical failures after internal fixation. *J Bone Joint Surg (Br)* 1990; 72: 26-31.
- Gargan M F, Gundle R, Simpson A H R W. How effective are osteotomies for unstable intertrochanteric fractures? *J Bone Joint Surg (Br)* 1994; 76: 789-92.
- Jensen J S. Classification of trochanteric fractures. *Acta Orthop Scand* 1980; 51: 803-10.
- May J M B, Chacha P B. Displacements of trochanteric fractures and their influence on reduction. *J Bone Joint Surg (Br)* 1968; 50: 318-23.
- Medoff R J, Maes K. A new device for the fixation of unstable pertrochanteric fractures of the hip. *J Bone Joint Surg (Am)* 1991; 73: 1192-9.
- Nunn D. Sliding hip screws and medial displacement osteotomy. *J R Soc Med* 1988; 81: 140-2.
- Parker M J. Cutting-out of the Dynamic Hip Screw related to its position. *J Bone Joint Surg (Br)* 1992; 74: 625.
- Parker M J. Valgus reduction of trochanteric fractures. *Injury* 1993; 24: 313-6.
- Poggrund H, Kenan S, Franki U, Amir D. Another look at the pertrochanteric fracture of the femur: the relationship to osteoporosis. *Injury* 1987; 18: 36-9.
- Uhlen B, Hammer R, Buciuto R. A pilot study describing a new device for the fixation of unstable trochanteric fractures of the hip. *Int J Orthop Trauma* 1995; 5: 69-71.
- Wright L T. Oblique subcervical (reverse intertrochanteric) fractures of the femur. *J Bone Joint Surg* 1947; 29: 707-10.