

Biaxial dynamization in unstable intertrochanteric fractures

Good experience with a simplified Medoff sliding plate in 94 patients

Ola Olsson¹, Leif Ceder¹, Karl Lunsjö¹ and Anders Hauggaard²

In a prospective study, 94 consecutive patients with unstable intertrochanteric fractures were treated by 16 surgeons, using a modified 4-hole Medoff sliding plate and followed clinically and radiographically for 1 year. Weight bearing after surgery was allowed as tolerated.

This new device is smaller and uses a simpler technique of insertion than the original 6-hole Medoff sliding plate. The modification of the plate makes biaxial sliding along both the shaft and the neck of the femur obligatory.

All fractures united and no postoperative lag screw penetration occurred. The use of a shorter side-plate with 4 cortical bone screws was sufficient for fixation and no plate loosening or breakage was observed.

On the basis of this experience, biaxial dynamization seems to facilitate fracture impaction and stability, and the simplified 4-hole Medoff sliding plate appears to be a suitable method for the treatment of unstable intertrochanteric fractures.

Departments of ¹Orthopedics and ²Radiology, Helsingborg Hospital, S-251 87 Helsingborg, Sweden.
Tel +46 42-10 00 00. Fax -10 24 50
Submitted 96-10-15. Accepted 97-02-11

A new device for treatment of unstable extracapsular hip fractures was introduced in 1991 by Medoff (Medoff and Maes 1991). By permitting sliding along the femoral shaft and optional sliding along the axis of the neck, it represents an alternative fixation principle to a conventional sliding hip screw device. In the original report, the Medoff plate was used in 25 patients with unstable intertrochanteric and high subtrochanteric fractures and no technical failure was observed. Compression was allowed only in the direction of the femoral shaft.

We used the Medoff sliding plate in the same way in a series of 104 patients with unstable intertrochanteric fractures (Lunsjö et al. 1995), but could not reproduce the good results in the series of Medoff and Maes (1991); we observed 7 postoperative technical failures, all lag screw penetrations. The complication rate was in accordance with that reported for the sliding hip screw as well as for the Gamma nail (Bannister et al. 1988, Davis et al. 1990, Flores et al. 1990, Larsson et al. 1990, Boriani et al. 1991, Bridle et al. 1991, Leung et al. 1992, Goldhagen et al. 1994).

In order to facilitate fracture impaction further and thus enhance fracture stability, compression with the Medoff sliding plate was allowed along both the shaft and the neck of the femur in a second series of 108 patients having displaced intertrochanteric fractures and with identical inclusion criteria (Lunsjö et al.

1996). When dual compression was allowed, only 1 postoperative technical failure, a lag screw penetration, was recorded.

The advantages of biaxial dynamization led us to develop a simpler version of the original Medoff sliding plate. The present study concerns the performance of this new Medoff sliding plate, designed only for 2-way compression in intertrochanteric fractures, and compares the outcome with that we obtained using dual sliding of the original Medoff sliding plate (Lunsjö et al. 1996).

Methods and patients

From the concept of the original Medoff sliding plate, a simpler version was developed for intertrochanteric fractures (Figures 1 and 2). The length of the side-plate was shortened from 6 to 4 holes. The distal compression screw was omitted and the distal end of the sideplate left open, in order to allow axial sliding of the compression slide beyond the bottom of the sideplate. In addition, the locking set screw was removed from the design, which makes dynamic compression in a biaxial pattern obligatory, when this implant is used. The sliding capacity of the plate is still 2.5 cm and identical with the original Medoff sliding plate.

The operative technique is similar to that of a stan-



Figure 1. The original 6-hole Medoff sliding plate (right) and the simplified 4-hole Medoff sliding plate (left) demonstrating equal sliding capacity of 2.5 cm. The locking set screw and the distal compression screw of the 6-hole plate have been omitted in the 4-hole plate. The holding set screw of the 4-hole plate is only used temporarily to keep the two parts of the sliding plate together during insertion and fixation of the device.




Figure 2. The simplified Medoff sliding plate with biaxial sliding capacity. The cortical bone screws are oriented in a biplanar direction.

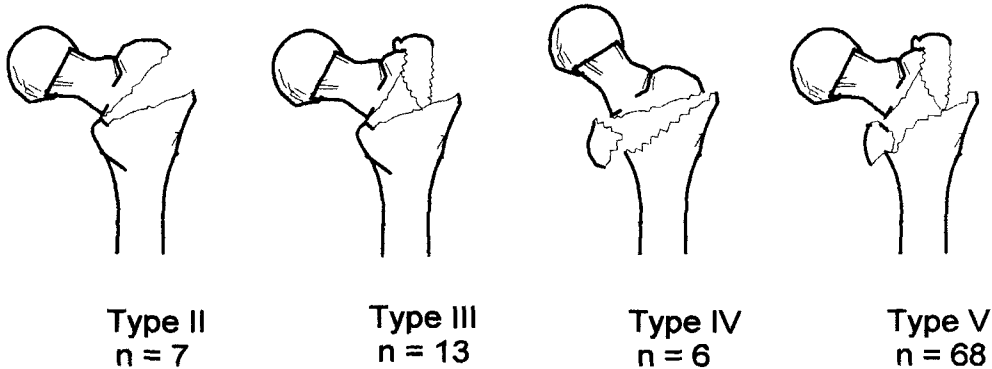


Figure 3. Distribution of the intertrochanteric fractures in the classification system of Jensen and Michaelsen (1975). Type 1, the undisplaced 2-part fracture, was excluded.

standard sliding hip screw, but two important differences must be recognized:

1) If the fracture is located proximal to or in the lag screw entry site on the lateral femoral cortex, the lag screw entry hole should be enlarged up to 2.5 cm distally. The barrel of the sliding element will otherwise impinge on the lateral cortex of the femoral shaft, preventing fracture compression.

2) Overdistraction of the fracture must be avoided. The sliding capacity of the plate may otherwise be dissipated immediately after the traction has been released.

During 1994, 94 consecutive patients (66 women) with intertrochanteric fractures were treated with the simplified Medoff sliding plate. The mean age of the patients was 80 (51-102) years. The operations were performed by 16 surgeons. The fractures were classified according to the Jensen and Michaelsen (1975) modification of the Evans system (Figure 3). The un-

displaced 2-part fracture (type 1) is considered stable and was not included. Patients with pathological fractures or earlier surgery of the proximal femur on the same side were excluded. 6 patients had other concomitant fractures, which delayed their mobilization. Before the injury, 52 patients were able to walk without any support and 72 patients were living in their own homes.

On admission, tibial pin traction was applied and the patients were given Dextran 70 (0.5 L Macrodex) as prophylactic anticoagulant therapy. Intravenous prophylactic antibiotic therapy (750 mg Cefuroxime) was started during the operation, with 3 subsequent doses given at 8-hour intervals. Subcutaneous low molecular heparin (40 mg Enoxaparin) was administered daily until the patient was mobilized.

93 patients were allowed weight bearing as tolerated immediately postoperatively. 1 patient was not allowed weight bearing until 6 weeks after the opera-

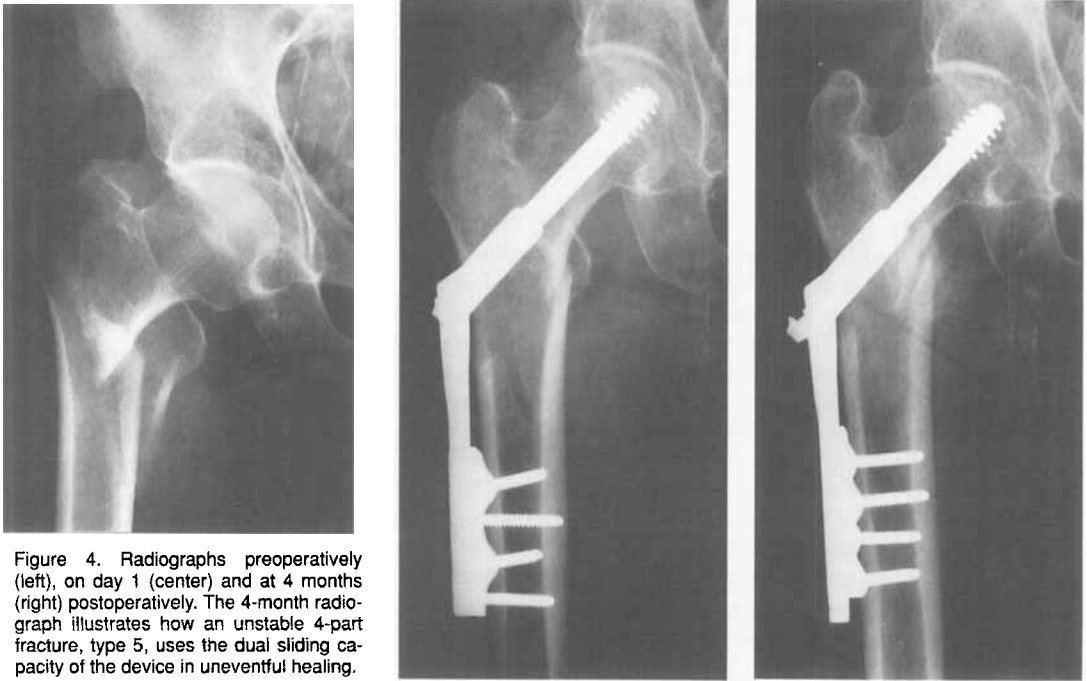


Figure 4. Radiographs preoperatively (left), on day 1 (center) and at 4 months (right) postoperatively. The 4-month radiograph illustrates how an unstable 4-part fracture, type 5, uses the dual sliding capacity of the device in uneventful healing.

tion, since the fracture was considered extremely unstable.

Radiographic examinations were performed on the first and 7th days after the operation. Clinical and radiographic follow-ups were done after 4 months and 12 months (Figure 4). Technical failures, defined as lag screw penetration or superior cut-out, breakage or loosening of the implant or nonunion, were recorded. Migration of the lag screw within the femoral head or varus angulation without penetration or cut-out was not considered a technical failure. The degree of sliding of the device along the shaft and the neck of the femur was assessed.

Results

The mean operating time was 67 (30-170) min and the estimated intraoperative bleeding 0.4 (0.02-2) L. The standard operative procedure was not followed in 3 patients, in whom additional cerclage wiring was used. The mean hospitalization time was 15 (2-47) days for 89 discharged patients; 5 patients died during the hospital stay.

During the hospital stay, no postoperative infection, no pulmonary emboli, but 1 postoperative deep venous thrombosis (phlebography) were diagnosed.

17 patients died within the first 4 months after the operation and of the remaining 77 patients, 76 attended the 4-month control. 1 year after the injury a fur-

ther 7 patients had died, and 63 of the 70 survivors were evaluated clinically and radiographically at 1 year. For the remaining 7 patients, we obtained information about residential status, need of support for walking and pain on weight bearing. All 7 patients had a radiographic examination 4 months after the operation and no signs of healing disturbances were recorded.

Of the 43 survivors who were able to walk without any support prior to the fracture, 25 regained their prefracture ambulatory status during the follow-up year. 49 of the 61 survivors, who lived in their own homes before the injury, still did so 1 year later.

1 year after the operation, 61 patients felt no pain on weight bearing, while 2 patients had slight pain. No information could be obtained about the remaining 7 patients, who were not ambulatory or suffering from dementia.

The plate slid a median of 8 (1-25) mm. All axial sliding occurred during the first 4 postoperative months, and no further sliding was recorded between the 4- and 12-month follow-ups. Maximal sliding of the plate occurred in 6 patients, in whom 1 fracture was of type 3 and 5 of type 5. In most of the cases, the sliding of the lag screw was minor. It was major in only 7 patients, who all had type 5 fractures. The sliding capacity of the lag screw was not fully utilized in any patient.

No postoperative technical failure occurred, and evaluation of the radiographs at 12 months demon-

strated union of all fractures. No patient required further surgery during the follow-up. In the 24 patients who died within one year of the injury, no technical failure was noted.

Discussion

The inclusion criteria in our study were the same as in the 2 series of Lunsjö et al. (1995, 1996), and hence age, sex and fracture type distribution were similar. One fourth of the patients died within 1 year of the injury, which is in accordance with other studies (Larsson et al. 1990, Leung et al. 1992, Lunsjö et al. 1995, 1996). 80% of the patients returned home, as in the study by Larsson et al. (1990).

We observed no adverse effects from use of the shorter simplified plate. 4 cortical bone screws appear to provide sufficient fixation to the femoral shaft and, theoretically, the biplanar orientation of the screws should improve the holding capacity, an assumption that however needs to be confirmed by mechanical testing. A prerequisite for dynamization along the femoral shaft in intertrochanteric fractures is distal enlargement of the entry hole of the lag screw, as already pointed out by Jarrett et al. (1984). No complication related to this procedure has been noted in clinical experience with the Medoff sliding plate (Medoff and Maes 1991, Lunsjö et al. 1995, 1996) or in this study.

The distal compression screw of the original Medoff sliding plate provides static axial fracture compression when tightened during surgery, but the dynamic vertical fracture compression that occurs postoperatively during ambulation does not differ between the 2 devices. Previous clinical experience (Lunsjö et al. 1995, 1996) and the results of this study suggest that the dynamic sliding properties of the plate are a more important feature than the ability to tighten the distal compression screw at the time of the operation. Animal experiments have also shown that the postoperative dynamic compression during ambulation is important for optimal fracture healing (Goodship and Kenwright 1985).

Several authors have emphasized that the load-sharing capacity of the implant is important (Jarrett et al. 1984, Chang et al. 1987, Larsson et al. 1988, Mahomed et al. 1994). In unstable intertrochanteric fractures, the sliding hip screw and the Gamma nail unload the proximal medial cortex of the femur with more than 90% of the load on the intact instrumented femur (Mahomed et al. 1994), thus not allowing sufficient fracture impaction to unload the implant and to transfer the loading forces to the fracture site. The

dual sliding provided by the Medoff sliding plate should facilitate fracture impaction and offer improved interfragmentary stress transfer, which theoretically will favor fracture stability and the healing process, thereby reducing the risk of cut-out, lag screw penetration and other types of mechanical failures.

Our findings support the principle of biaxial dynamization in the treatment of unstable intertrochanteric fractures. The rate of postoperative technical failures was 1% in the series of Lunsjö et al. (1996) and no postoperative technical failure was recorded in the present series. The complication rate is lower than that reported for the sliding hip screw and the Gamma nail. When Lunsjö et al. (1995) used 1-way compression along the femoral shaft, the complication rate was 7%. They found a statistically significant reduction in the complication rate, when 2-way compression was used. Based on the clinical experience of uniaxial and biaxial dynamization, respectively, we consider 2-way compression along both the shaft and the neck of the femur preferable to 1-way compression along the femoral shaft alone, when the Medoff sliding plate is used for the treatment of intertrochanteric fractures.

We found biaxial dynamic compression with the simplified 4-hole Medoff sliding plate to be a reliable and consistent method of treatment. Immediate weight bearing was allowed and no postoperative lag screw penetration, implant failure or nonunion occurred. The possible clinical advantage of biaxial dynamization in the treatment of unstable intertrochanteric fractures needs to be analyzed in randomized trials, comparing the Medoff sliding plate to other fracture fixation systems.

Acknowledgements

This study was supported by grants from the Clinical Research Foundation of Malmöhus County Council. The authors wish to thank Mr Henrik Hansson, Linköping, Sweden, who contributed to the simplification of the original Medoff sliding plate.

References

- Bannister G C, Gibson A G, Ackroyd C E, Newman J H. The fixation and prognosis of trochanteric fractures. A randomized prospective controlled trial. *Clin Orthop* 1988; 254: 242-6.
- Boriani S, Bettelli G, Zmerly H, et al. Results of the multicentric Italian experience on the Gamma nail: A report on 648 cases. *Orthopedics* 1991; 14: 1307-14.

- Bridle S H, Patel A D, Bircher M, Calvert P T. Fixation of intertrochanteric fractures of the femur; a randomized prospective comparison of the Gamma nail and the dynamic hip screw. *J Bone Joint Surg (Br)* 1991; 73: 330-4.
- Chang W S, Zuckerman J D, Kummer F J, Frankel V H. Bio-mechanical evaluation of anatomic reduction versus medial displacement osteotomy in unstable intertrochanteric fractures. *Clin Orthop* 1987; 225: 141-6.
- Davis T R C, Sher J L, Horsman A, et al. Intertrochanteric femoral fractures: mechanical failure after internal fixation. *J Bone Joint Surg (Br)* 1990; 72: 26-31.
- Flores L A, Harrington I J, Heller M. The stability of intertrochanteric fractures treated with a sliding screw-plate. *J Bone Joint Surg (Br)* 1990; 72: 37-40.
- Goldhagen P R, O'Connor D R, Schwarze D, Schwartz E. A prospective comparative study of the Compression Hip Screw and the Gamma nail. *J Orthop Trauma* 1994; 5: 367-72.
- Goodship A E, Kenwright J. The influence of induced micro-movement upon the healing of experimental tibial fractures. *J Bone Joint Surg (Br)* 1985; 67: 650-5.
- Jarrett P J, Fleming L L, Whitesides Jr T E. The stable internal fixation of peritrochanteric hip fractures. In *Fractures of the hip. 1984 AAOS Instructional course lectures Vol XXXIII*: 203-17.
- Jensen J S, Michaelsen M. Trochanteric femoral fractures treated with McLaughlin osteosynthesis. *Acta Orthop Scand* 1975; 46: 795-803.
- Larsson S, Elloy M, Hansson L I. Fixation of unstable trochanteric hip fractures. A cadaver study comparing three different devices. *Acta Orthop Scand* 1988; 59 (6): 658-63.
- Larsson S, Friberg S, Hansson L I. Trochanteric fractures of the femur. Analysis of mobility, complications and mortality in 607 cases operated by the sliding screw technique. *Clin Orthop* 1990; 260: 232-41.
- Leung K S, So W S, Shen W Y, Hui P W. Gamma nails and dynamic hip screws for peritrochanteric fractures. A randomized prospective study in elderly patients. *J Bone Joint Surg (Br)* 1992; 74 (3): 345-51.
- Lunsjö K, Ceder L, Stigsson L, Hauggaard A. One-way compression along the femoral shaft with the Medoff sliding plate. The first European experience of 104 intertrochanteric fractures with a 1-year follow-up. *Acta Orthop Scand* 1995; 66 (4): 343-6.
- Lunsjö K, Ceder L, Stigsson L, Hauggaard A. Two-way compression along the shaft and the neck of the femur with the Medoff sliding plate. One-year follow-up of 108 intertrochanteric fractures. *J Bone Joint Surg (Br)* 1996; 78: 387-90.
- Mahomed N, Harrington I, Kellam J, Maistrelli G, Hearn T, Vroemen J. Biomechanical analysis of the Gamma nail and sliding hip screw. *Clin Orthop* 1994; 304: 280-8.
- Medoff R, Maes K. A new device for the fixation of unstable peritrochanteric fractures of the hip. *J Bone Joint Surg (Am)* 1991; 73: 1192-9.