

Open reduction and internal fixation of displaced intraarticular fractures of the distal radius

31 patients followed for 3–7 years

Leiv M Hove¹, Per T Nilsen¹, Ove Furnes¹, Hans E Oulie², Eirik Solheim¹ and Anders O Mølster¹

We have used open reduction and internal fixation with a T-plate in 31 displaced, intraarticular fractures of the distal radius which were judged irreducible or in which closed reduction failed. The mean follow-up time was 4 (3–7) years. The dorsal angulation, the radial length, the articular step-off and the intraarticular gap between fragments were substantially improved after surgery. 30 patients had excellent or

good extraarticular alignment, and only 1 patient had a postoperative intraarticular step-off of 2 mm. The function was excellent or good in 26 patients at follow-up. Complications occurred in 6 patients: 1 compartment syndrome, 1 postoperative wound infection, 2 ruptures of the extensor pollicis longus tendon, and 2 patients had median nerve paresthesias.

Departments of ¹Orthopaedics and ²Diagnostic Radiology, Haukeland University Hospital, N-5021 Bergen, Norway
Tel +47 55-29 80 60. Fax -97 49 34/-97 27 61
Submitted 96-01-27. Accepted 96-10-07

Difficulties in achieving and maintaining a congruent articular surface by closed means in distal radius fractures may be an indication for open reduction (Mellone 1984, 1986, Knirk and Jupiter 1986, Bradway et al. 1989, Fernandez and Geissler 1991). We assessed the articular congruity, the extraarticular alignment, and the functional end-results in 31 patients treated with open reduction and internal fixation of intraarticular fractures of the distal end of the radius.

Patients and methods

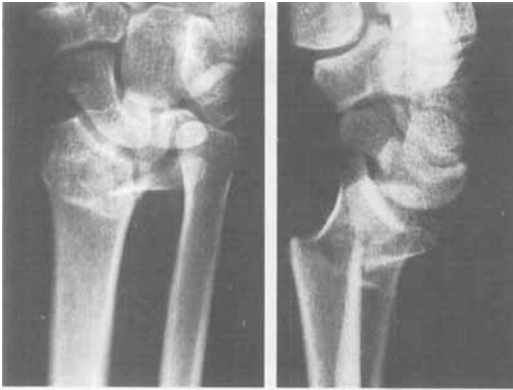
We studied 31 consecutive patients (10 women), mean age 43 (15–69) years, operated between 1987 and 1991 because of displaced intraarticular fractures of the distal radius. The indication for surgery was a displaced intraarticular fracture with unsuccessful closed reduction or fractures judged irreducible from the primary radiographs. A persistent articular step-off of 2 mm or more after closed reduction indicated surgery. Elderly and severely osteoporotic patients with reduced functional requirements of the wrist were not operated on.

According to the classification by Older et al. (1965) and the AO classification (Müller et al. 1990), 20 patients had comminuted fractures (Older type 4; AO types C2 and C3), 4 patients had multifragmentary forms of chauffeur's fracture (AO type B1.2), 6

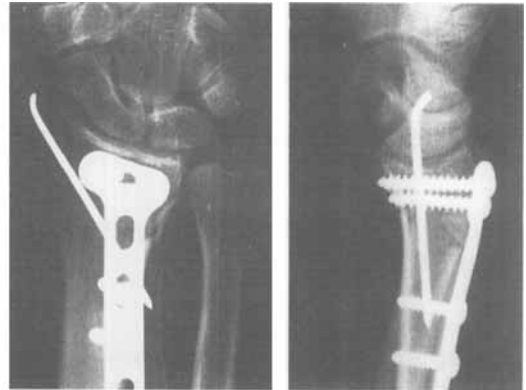
patients had comminuted Smith's fracture (AO types C2 and C3), and 1 patient had a palmar articular lip fracture with a large fragment (palmar Barton's fracture; AO type B3). All fractures were closed, and there were no tendon or nerve lesions. 3 patients (2 women, 1 man) were initially treated with closed reduction and external fixation, but were reoperated on next day with open reduction and internal fixation because of a persistent articular step-off. The mean time interval from injury to operation was 5 (0–12) days, and the mean follow-up time after injury was 4 (3–7) years.

Technique

Regional anesthesia was used in most cases. 20 wrists had primarily dorsal displacement and comminution (comminuted Colles' fractures, Older type 4; AO types C2 and C3) and were approached through a dorsal, longitudinal incision, between the third and fourth extensor compartments. The joint was opened along the joint line, and reduction and visualization were aided by distraction of the joint by manual traction. The fragments were manipulated into correct position with small elevators. Once a satisfactory reduction had been achieved, a T-plate was fixed with small fragment screws. In several patients, additional fixation of small fragments with fine Kirschner wires was necessary, and in 4 cases (AO type B1.2) a large radial styloid fragment was fixed with a lag screw



A 46-year-old man with a fracture from a sports trauma.



After open reduction and internal fixation. Excellent anatomical and functional result.

through a small separate incision. Lister's tubercle was osteotomized to achieve optimal plate apposition and was used as a small graft beneath the elevated dorsoulnar (die-punch) fragment. In 2 patients with a large metaphyseal bone loss that persisted after reduction, bone graft from the iliac crest was used. In most cases the extensor retinaculum was split and interposed between the plate and the external tendons.

For palmar displacement (comminuted Smith and Barton's fractures; AO types C2, C3, and B3), a palmar approach was used (n 7). Carpal tunnel release, mobilization of the median nerve, loosening of the pronator quadratus muscle, and fixation of the fracture fragments by a short T-plate was performed.

Postoperative treatment

A plaster splint was applied for 1-2 weeks; passive and active range-of-motion exercises started during the next 1-3 weeks, depending on the stability of the fractures. The dorsal T-plates were removed after a mean of 11 (6-16) months, the volar plates in only 2 cases.

Anatomical and functional assessments

The dorsal angulation, the radial length (Van der Linden and Ericson 1981, Solgaard 1984, Metz and Gilula 1993), the articular step-off (Knirk and Jupiter 1986), and the intraarticular gap between major fragments (Trumble et al. 1994) were assessed before and after reduction, at 2 and 6 weeks, 3, 6, and 12 months, and at follow-up on anteroposterior and lateral radiographs. The extraarticular alignment (Lidström 1959) and the articular incongruity (Knirk and Jupiter 1986) were graded, and arthrosis was classified by a radiologist at follow-up (Lidström 1959, Missakian et al. 1992).

At follow-up after a mean of 4 (3-7) years, the sub-

jective evaluation included a pain relief rating based on a scale from 0 points (no pain) to 6 points (frequent or constant pain). The objective evaluation included the residual deformity, the degree of arthrosis, and complications. The range of wrist motion and pro-/supination was measured with a goniometer. Each variable was compared with the value obtained from the uninjured side. The subjective and objective data were graded, using a modification of the demerit point system of Gartland and Werley (1951) and Sarmiento et al. (1975).

Statistics

The Wilcoxon matched-pairs signed-rank sum test was used to compare pre- and postoperative dorsal angulation, radial length, articular step-off, and the intraarticular gap between fragments.

Results

The mean radial length improved from 2 (SD 8) mm to 11 (3) mm ($p < 0.0001$), and the angulation from 18 (18) degrees dorsal to 5 (6) palmar degrees ($p = 0.0001$). The mean articular step-off improved from

Number of patients with articular step-off and intra-articular gap before and after reduction (n 31)

	0-1 mm	1-2 mm	2-3 mm	> 3 mm
Articular step-off, preoperative	7	6	9	9
postoperative	25	5	1	0
	(p = 0.0001)			
Intraarticular gap, preoperative	4	4	12	11
postoperative	22	7	2	0
	(p < 0.0001)			

2.4 (2) mm to 0.3 (0.7) mm and the intraarticular gap from 3.1 (3) mm to 0.4 (0.9) mm, leaving only 1 patient with a step-off and 2 patients with a gap of 2 mm (Table). None of the patients had any loss of correction between the postoperative and follow-up radiographs.

At follow-up, no radiographic sign of arthrosis was found in 21 patients, moderate changes with narrowing of the joint space were found in 10. No patient had severe arthrosis.

16 patients had no pain, 9 had some discomfort in activities, 3 felt occasional pain and weakness of the wrist, and 3 patients had frequent pain. All patients but 1 regained full finger flexion. The median Gartland and Werley's demerit point score was 2, mean 4.0 (4) and the results were classified as excellent or good in 26 patients, and fair in 5.

1 patient with a fracture from a traffic accident developed a severe postoperative wound infection, followed by the acute carpal tunnel syndrome and underwent carpal tunnel release. A few weeks later, he sustained a rupture of the extensor pollicis longus tendon which was successfully treated with an indicis proprius tendon transfer. The swelling persisted for several weeks and at follow-up he had some permanent finger stiffness and mild paresthesias from the superficial radial nerve.

Another patient who had rupture of the extensor pollicis longus tendon 6 weeks after dorsal plating of the fracture underwent an indicis proprius tendon transfer. Mild paresthesias of the median nerve and the superficial radial nerve distribution area were seen in 2 patients. A compartment syndrome developed during the first day after injury in one patient. She underwent fasciotomy and function is now excellent.

Discussion

Our results indicate that the functional outcome is related to the quality of the reduction. Although our study was not randomized, the results agree with the increasing emphasis on restoring both articular congruity and extraarticular alignment in comminuted intraarticular fractures of the distal radius (Bradway et al. 1989, Jupiter and Lipton 1993, Amadio 1995). Failure to achieve a proper orientation and length of the distal radius relative to the carpus and the ulna can result in the complications of pain and instability, which may require corrective osteotomies (Jupiter and Masem 1988, Fernandez 1993, Hove and Mølster 1994). Persistent articular incongruity may lead to significant arthrosis and require arthrodesis (Knirk and Jupiter 1986). It is generally accepted that a plas-

ter cast alone cannot maintain the reduced position in the most comminuted fractures (Aro and Koivunen 1991, Ark and Jupiter 1993, Hove et al. 1994), and rereduction and a new cast will not improve the final radial length (McQueen et al. 1986, Hove et al. 1995). The management of unstable fractures of the distal radius has been significantly improved by the use of external fixators (Howard et al. 1989, Schuind et al. 1989, Hertel and Jakob 1993). However, there are still some articular fractures in which anatomic restoration of the joint surface cannot be obtained by "ligamentotaxis" through joint distraction alone.

In our material, 26/31 patients had a good or excellent anatomical end-result regarding radial length and angulation and articular congruity. This can be compared with the series of Fernandez and Geissler (1991) in which 37/40 had a residual articular incongruity of 1 mm or less. 26 patients in our series had good or excellent function, which is similar to other operative series with 13/16 (Bradway et al. 1989) and 28/32 patients (Missakian et al. 1992) with comparable values.

A long-term follow-up study of articular fractures of the distal radius (Knirk and Jupiter 1986) showed a high incidence of radiocarpal arthrosis in patients that had healed with an articular step-off of 2–3 mm. In our series, the articular congruity improved significantly following surgery in all patients, and after 3–7 years most patients had no arthrosis. These findings support the contention that restoration of accurate articular congruency prevents posttraumatic wrist arthrosis (Axelrod and McMurtry 1990, Hastings and Leibovic 1993).

The complication rate in different series varies between 7/40 patients (Fernandez and Geissler 1991) and 30/50 (Hastings and Leibovic 1993). In our series, 6 patients had 8 complications, but only 2 of these were major. In several studies, compression of the median nerve is common (Cooney et al. 1980, Stewart et al. 1985, Aro et al. 1988). In our series, all patients with severe injuries and all with a palmar approach had the carpal tunnels opened. Other reports routinely recommend carpal tunnel release in all operative cases (Axelrod and McMurtry 1990) which, together with the operative prevention of malunion, may reduce the number of entrapments of the median nerve (Aro et al. 1988, Hove 1995).

Attrition may cause tendon ruptures (Helal et al. 1982, Hirasawa et al. 1990). 2 patients sustained rupture of the extensor pollicis longus tendon 6–8 weeks after their operations. More recently, we have performed subtendinous interposition of the extensor retinaculum to avoid attrition from the plate and screws (Hove 1994, Amadio 1995).

In fractures where reduction leaves a significant bone defect, a cancellous bone graft can supply both structural and osteogenetic supports (Cooney et al. 1979, Jupiter and Lipton 1993, Amadio 1995). In our series, cancellous bone grafts from the iliac crest were used in 2 patients where mechanical support was judged necessary. In the remaining cases, the osteosynthesis was perioperatively considered to support the articular restoration adequately. Several authors recommend a bone graft, either local or from the iliac crest, as an important part of the procedure in all patients with bony impaction after fracture reduction (Amadio 1995, Leung and Leung 1995), while others find this necessary only in certain cases with excessive bone loss (Saffar 1995). Combinations of internal and external fixation are also recommended in severe metaphyseal comminution, where the external fixator serves as a neutralization device to counteract the strong forces of the extrinsic muscles, which tend to shorten the radius (Cooney and Berger 1993, Hastings and Leibovic 1993, Hertel and Jakob 1993), and in intraarticular fractures when comminution is so extreme that articular reduction cannot be maintained without the addition of ligamentotaxis (Jupiter and Lipton 1993, Amadio 1995).

References

- Amadio P C. Open reduction of intra-articular fractures of the distal radius. In: *Fractures of the distal radius* (Eds. Saffar P, Cooney W P). Martin Dunitz Ltd. London 1995: 193-202.
- Ark J, Jupiter J B. The rationale for precise management of distal radius fractures. *Orthop Clin North Am* 1993; 24 (2): 205-10.
- Aro H T, Koivunen T. Minor axial shortening of the radius affects outcome of Colles' fracture treatment. *J Hand Surg* 1991; 16A (3): 392-8.
- Aro H, Koivunen T, Katevuo K, Nieminen S, Aho A J. Late compression neuropathies after Colles' fractures. *Clin Orthop* 1988; 233: 217-25.
- Axelrod T S, McMurtry R Y. Open reduction and internal fixation of comminuted, intraarticular fractures of the distal radius. *J Hand Surg* 1990; 15A (1): 1-11.
- Bradway J K, Amadio P C, Cooney W P. Open reduction and internal fixation of displaced, comminuted intraarticular fractures of the distal end of the radius. *J Bone Joint Surg (Am)* 1989; 71 (6): 839-48.
- Cooney W P, Berger R A. Treatment of complex fractures of the distal radius. Combined use of internal and external fixation and arthroscopic reduction. *Hand Clin* 1993; 9 (4): 603-12.
- Cooney W P, Linscheid R L, Dobyns J H. External pin fixation of unstable Colles' fractures. *J Bone Joint Surg (Am)* 1979; 61 (6): 840-5.
- Cooney W P, Dobyns J H, Linscheid R L. Complications of Colles' fractures. *J Bone Joint Surg (Am)* 1980; 62 (4): 613-9.
- Fernandez D L. Reconstructive procedures for malunion and traumatic arthritis. *Orthop Clin North Am* 1993; 24 (2): 341-63.
- Fernandez D L, Geissler W B. Treatment of displaced articular fractures of the radius. *J Hand Surg* 1991; 16A (3): 375-84.
- Gartland J J, Werley C W. Evaluation of healed Colles' fractures. *J Bone Joint Surg (Am)* 1951; 33 (4): 895-907.
- Hastings H, Leibovic S J. Indications and techniques of open reduction and internal fixation of distal radius fractures. *Orthop Clin North Am* 1993; 24 (2): 309-26.
- Helal B, Chen S C, Iwegbu G. Rupture of the extensor pollicis longus tendon in undisplaced Colles' type of fracture. *Hand* 1982; 14 (2): 41-7.
- Hertel R, Jakob R P. Static external fixation of the wrist. *Hand Clin* 1993; 9 (4): 567-75.
- Hirrasawa Y, Katsumi Y, Akiyoshi T, Tamai K, Toliola T. Clinical and microangiographic studies on rupture of the E.P.L. tendon after distal radial fractures. *J Hand Surg* 1990; 15B (1): 51-7.
- Hove L M. Delayed rupture of the thumb extensor tendon. A 5-year study of 18 consecutive cases. *Acta Orthop Scand* 1994; 65 (2): 199-203.
- Hove L M. Nerve entrapment and reflex sympathetic dystrophy after fractures of the distal radius. *Scand J Plast Reconstr Hand Surg* 1995; 29 (1): 53-8.
- Hove L M, Mølster A O. Surgery for posttraumatic wrist deformity. Radial osteotomy and/or ulnar shortening in 16 Colles' fractures. *Acta Orthop Scand* 1994; 65 (4): 434-8.
- Hove L M, Solheim E, Skjeie R, Sørensen F K. Prediction of secondary displacement in Colles' fracture. *J Hand Surg* 1994; 19B (6): 731-6.
- Hove L M, Fjeldsgaard K, Skjeie R, Solheim E. Anatomical and functional results five years after remanipulated Colles' fractures. *Scand J Plast Reconstr Hand Surg* 1995; 29 (4): 349-55.
- Howard P W, Steward H D, Hind R E, Burke F D. External fixation or plaster for severely displaced comminuted Colles' fractures? *J Bone Joint Surg (Br)* 1989; 71 (1): 68-73.
- Jupiter J B, Lipton H. The operative treatment of intraarticular fractures of the distal radius. *Clin Orthop* 1993; 292: 48-61.
- Jupiter J B, Masem M. Reconstruction of post-traumatic deformity of the distal radius and ulna. *Hand Clin* 1988; 4 (3): 377-90.
- Knirk J L, Jupiter J B. Intra-articular fractures of the distal end of the radius in young adults. *J Bone Joint Surg (Am)* 1986; 68 (5): 647-59.
- Leung K S, Leung P C. The role of bone grafting in comminuted distal radius fractures. In: *Fractures of the distal radius* (Eds. Saffar P, Cooney W P). Martin Dunitz Ltd. London 1995: 193-202.
- Lidström A. Fractures of the distal end of the radius. *Acta Orthop Scand (Suppl 41)* 1959; 1-118.
- McQueen M M, MacLaren A, Chalmers J. The value of remanipulating Colles' fractures. *J Bone Joint Surg (Br)* 1986; 68 (2): 232-3.

- Melone C P. Articular fractures of the distal radius. *Orthop Clin North Am* 1984; 15 (2): 217-36.
- Melone C P. Open treatment for displaced articular fractures of the distal radius. *Clin Orthop* 1986; 202: 103-11.
- Metz V M, Gilula L A. Imaging techniques for distal radius fractures and related injuries. *Orthop Clin North Am* 1993; 24 (2): 217-28.
- Missakian M L, Cooney W P, Amadio P C, Glidewell H L. Open reduction and internal fixation for distal radius fractures. *J Hand Surg* 1992; 17A (4): 745-55.
- Müller M E, Nazarian S, Koch P, Schatzker J. The comprehensive classification of fractures of long bones. Springer-Verlag, Berlin 1990; 106-15.
- Older T M, Stabler E V, Cassebaum W H. Colles' fracture: Evaluation and selection of therapy. *J Trauma* 1965; 5 (4): 469-76.
- Saffar P. Current trends in treatment and classification of distal radial fractures. In: *Fractures of the distal radius* (Eds. Saffar P, Cooney W P). Martin Dunitz Ltd. London 1995; 12-8.
- Sarmiento A, Pratt G W, Berry N C, Sinclair W F. Colles' fracture. Functional bracing in supination. *J Bone Joint Surg (Am)* 1975; 57 (3): 311-7.
- Schuind F, Donkerwolcke M, Rasquin C, Burny F. External fixation of fractures of the distal radius: A study of 225 cases. *J Hand Surg* 1989; 14A (2): 404-7.
- Solgaard S. Angle of inclination of the articular surface of the distal radius. *Radiologe* 1984; 24: 346-8.
- Stewart H D, Innes A R, Burke F D. The hand complications of Colles' fractures. *J Hand Surg* 1985; 10B (1): 103-6.
- Trumble T E, Schmitt S R, Vedder N B. Factors affecting functional outcome of displaced intra-articular distal radius fractures. *J Hand Surg* 1994; 19A (2): 325-40.
- Van der Linden W, Ericson R. Colles' fracture. How should its displacement be measured and how should it be immobilized? *J Bone Joint Surg (Am)* 1981; 63 (8): 1285-8.