

Resection of cervical spinal neurinoma including affected nerve root

Recovery of neurological deficit in 15 cases

Toshiki Miura, Kozo Nakamura, Hiromi Tanaka, Hiroshi Kawaguchi, Katsushi Takeshita and Takahide Kurokawa

In surgery for spinal neurinoma derived from a root, which is assumed to be important for function of the extremities, it is controversial whether the nerve root involved should be totally resected. We retrospectively reviewed the postoperative neurological deficits in 15 patients with solitary neurinoma or neurofibroma in a segment of the cervical spine (C5–C8); in

all of them, both anterior and posterior roots were resected. Mean patient age was 47 (18–71) years and the mean follow-up period was 49 (9–137) months. 10 patients showed loss of motor function and 8 patients developed sensory impairment postoperatively. Most postoperative loss of motor function was recovered.

Department of Orthopaedic Surgery, Faculty of Medicine, University of Tokyo, 7-3-1 Hongo Bunkyo-ku Tokyo, Japan 113. Tel +81 3-3815 5411 (ext. 3376). Fax -3818 4082. Correspondence: Dr. Kozo Nakamura
Submitted 97-07-25. Accepted 98-01-07

In surgery for spinal neurinoma, preservation of the unaffected funiculus of the affected nerve root is often difficult even with microsurgical technique. When the tumor is derived from a root which is assumed to be important for extremity functions, it is still controversial whether that nerve root should be totally resected. We investigated the incidence, severity and outcome of neurological deficits after resection of single C5–C8 nerve roots because of neurinomas.

Patients and methods

We retrospectively reviewed 22 patients who underwent surgery for solitary spinal neurinoma or neurofibroma at C5–T1 levels during 1977–1996. Total resection of the involved root was performed in 18 of them. 3 patients were excluded: 2 whose operations were for recurrence of neurinoma and 1 with a psychological disorder. 15 patients (6 women) were studied (Table). Both anterior and posterior roots were resected in all of them. The mean age at surgery was 47 (18–71) years and the average follow-up period was 49 (9–137) months. Motor function was evaluated by manual muscle-testing (Lacote et al. 1987) and the weakest muscle was used to represent each case. Sensory deficit was evaluated by the extent and degree of hypesthesia. Preoperatively, motor function was normal in 11 patients, M4 in 2 and M1–M3 in 2 (Figure).

Patient age was also studied as a risk factor for neurological deficits. The Welch t-test was used to compare mean values.

Results

10 of the 15 patients showed a decrease in motor function immediately after operation: by 1 grade in 3 patients, by 2 grades in 3 patients and by more than 3 grades in 4 patients. After the follow-up periods, motor function improved in all 10 patients; all recovered to M5 or M4 (Figure). The mean time for recovery of motor function after a decrease of 1 grade was 6 months, and after a decrease of 2 or more grades was 22 months ($p = 0.05$).

Motor function of the 4 patients (cases 2, 8, 9, 12) 40 years old or less, excluding those with preoperative motor weakness, was impaired by an average 0.25 grade immediately after the operation, but was completely recovered while that of the 7 patients older than 41 years, excluding those with preoperative motor weakness, was impaired by an average 2.5 grades ($p = 0.002$).

Preoperative sensory deficit deteriorated in 1 patient, a new area of hypesthesia developed after operation in 7 patients, while no sensory impairment was seen after surgery in the other 7 patients. The extent and degree of hypesthesia in 8 patients, who had sen-

Data on 15 patients who underwent total resection of neurinoma at C5-C8

A	B	C	D	E	F	G	H	I	J	K	L	M	N	O	P	Q	R	S
1	18	M	L	C5	U	I	N	13	70	+	biceps	1	2	5		+	-	
2	34	M	L	C5	P	D	N	10	24	-	deltoid	5	5	5		-	-	
3	71	M	L	C5	U	D	N	15	47	+	deltoid	2	2	3		+	N	I
4	57	M	R	C5	U	I	N	13	17	+	deltoid	4	1	4	17	+	-	
5	43	M	L	C6	U	D	NF	36	120	-	biceps	5	0	4	37	-	N	I
6	55	F	L	C6	U	D	N	132	10	-	biceps	5	2	5	8	-	N	I
7	56	M	L	C6	U	D	NF	16	16	-	deltoid	5	2	5	16	-	-	
8	32	F	R	C6	P	D	N	24	134	-	deltoid	5	5	5		+	N	C
9	40	F	L	C7	P	D	N	4	12	-	triceps	5	4	5	2	-	N	I
10	59	M	R	C7	U	D	N	6	9	-	triceps	5	3	4	5	-	N	I
11	63	F	L	C7	U	D	N	7	82	-	triceps	5	3	5	52	+	-	
12	31	M	R	C7	A	D	N	25	137	-	triceps	5	5	5		+	-	
13	33	F	L	C8	U	I	N	8	10	+	FDP	4	3	4	5	-	-	
14	55	F	R	C8	U	D	N	5	20	-	FDP	5	3	5	20	+	A	I
15	65	M	R	C8	P	D	N	16	21	-	APB	5	4	5	11	-	N	C

A Case

B Age

C Sex

M male
F female

D Affected side

R right
L left

E Segment resected

F Origin

A anterior root
P posterior root
U unknown

G Type of tumor

D dumbbell
I intradural-extramedullary

H Histology

N neurinoma
NF neurofibroma

I Duration from onset to surgery, months

J Follow-up period after operation, months

K Preoperative motor deficit

L Weakest muscle

FDP flexor digitorum profundus
APB abductor pollicis brevis

M Muscle strength before operation

N Muscle strength immediately after operation

O Muscle strength after the follow-up period

P Period for the impaired muscle strength to reach plateau, months

Q Preoperative sensory deficit (hypesthesia)

R Sensory deficit immediately after operation

- no deficit

A preoperative sensory deficit became worse

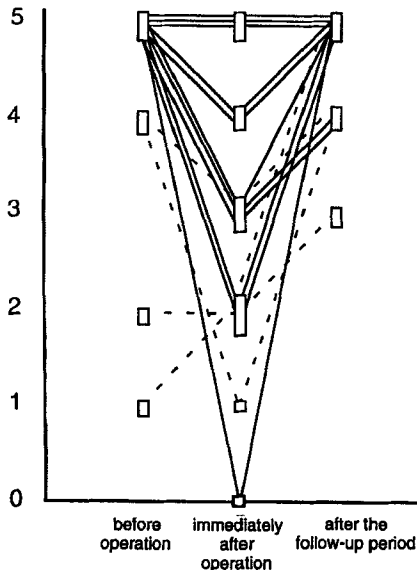
N new area of hypesthesia developed

S Improvement in hypesthesia after the follow-up period

C completely recovered

I improved, but not completely

Manual muscle testing



Time course of the muscle strength for each case.
 — cases without motor deficit before operation.
 - - - cases with motor deficit before operation.

sory impairment in the area of the relevant root immediately after operation, improved during the follow-up; the deficits disappeared completely in 2 patients.

Discussion

Several studies have concerned the incidence and severity of neurological deficits, following resection of nerve roots because of neurinoma at C5-T1 levels. Kim et al. (1989) and Schultheiss and Gullotta (1993) reported that all 5 of 14 patients and 3 of 6 patients showed mild neurological impairments, respectively. However, other studies included some cases with substantial loss of motor function (Tanaka et al. 1985, McCormick 1996). Our study confirmed that varying degrees of deficits occur after nerve root resection.

The reason why no neurological deficit was detected in some cases before or after the operation could be that the involved nerve may have been congenitally nonfunctional or had become nonfunctional before the operation, its function being compensated for by the neighboring roots (Pool 1969, Nittner 1976, Kim

et al. 1989, Schultheiss and Gullotta 1993). Even in the cases with postoperative impairment, where some fibers in the resected root had been functional, the impaired function was also compensated after the follow-up periods.

Schultheiss and Gullotta (1993) reported that all postoperative neurological deficits were regained within 7 months, but their study included no severe cases. We found that the time for recovery of motor function depended on the severity of impairment.

Patients 40 years old or less did not develop severe postoperative deficits.

References

- Kim P, Ebershold M J, Onofrio B M, Quast L. Surgery of spinal nerve schwannoma. Risk of neurological deficit after resection of involved root. *J Neurosurg* 1989; 71: 810-4.
- Lacote M, Chevalier A M, Miranda A, Bleton J P, Stevenin P. Clinical evaluation of muscle function. Churchill Livingstone 1987.
- McCormick P C. Surgical management of dumbbell tumors of the cervical spine. *Neurosurgery* 1996; 38: 294-300.
- Nittner K. Spinal meningiomas, neurinomas and neurofibromas- hourglass tumours. In: *Handbook of clinical neurology. Tumors of the spine and spinal cord* (Eds Vinken P J, Bruyn G W). Amsterdam, North-Holland 1976; 20: 177-322.
- Pool J L. The surgery of spinal cord tumors. *Clin Neurosurg* 1969; 17: 310-30.
- Schultheiss R, Gullotta G. Resection of relevant nerve roots in surgery of spinal neurinomas without persisting neurological deficit. *Acta Neurochir (Wien)* 1993; 122: 91-6.
- Tanaka H, Kurokawa T, Hoshino Y, Kobayashi M, Machida H, Sawa S, Hirabayashi S, Kato M, Yoshioka T. Recovery of motor function after resection of cervical nerve root (in Japanese). *Kanto Seikeisaigaijeka Gakkai Zasshi* 1985; 16: 80-1.