

Absorbable screws through the greater trochanter do not disturb physeal growth

Rabbit experiments

Jorge Gil-Albarova¹, Milena Fini², Raúl Gil-Albarova³, Marga Melgosa³, Nicoli Aldini-Nicolo², Roberto Giardino² and Fernando Seral¹

We studied the effect of implantation of self-reinforced polyglycolic acid (SR-PGA) screws through the greater trochanter in rabbits. 15 rabbits aged 10 weeks had an SR-PGA screw inserted through the left trochanter physis. A similar drilling was made through the right greater trochanter without screw implantation. The animals were assigned to 3 groups of 5, and were killed after 1, 2 or 3 months. Radiographs of both femurs were obtained monthly and the articulo-trochanteric distance and the neck-shaft angle were measured. After killing the animals,

a histological study was performed. The drilling on the right trochanter generated a bony bridge in all the animals. The SR-PGA screws did not give rise to an epiphysiodesis. The progressive peripheral degradation of the implants gave rise to the formation of only modest bridges, which were smaller in size than those observed in the control trochanter. Our findings suggest that absorbable PGA screws implanted through a growth plate cause only minor bone formation and no epiphysiodesis.

¹Servicio de Cirugía Ortopédica y Traumatología. Hospital Clínico Universitario "Lozano Blesa" Universidad de Zaragoza, Spain, ²Servizio di Chirurgia Sperimentale, Istituto di Ricerca Codivilla-Putti, Istituto Ortopedico Rizzoli, Bologna, Italia, ³Unidad Mixta de Investigación. Hospital Clínico Universitario "Lozano Blesa" Universidad de Zaragoza, Spain. Correspondence: Dr. Jorge Gil-Albarova, Fray Luis Amigó 2, 1°C, ES-50.006 Zaragoza, Spain. Tel and Fax + 34 9 76 389626 Submitted 97-05-31. Accepted 97-12-22

To treat relative overgrowth of the greater trochanter most authors recommend epiphysiodesis in children under 8 years of age and distal and lateral transposition in older children (Langenskiöld and Salenius 1967, Gage and Cary 1980, Tauber et al. 1980, Stevens and Coleman 1985, Bialik and Rosenberg 1994) to improve hip mechanics.

Absorbable implants have been studied in human clinical practice for fixation of malleolar fractures, elbow and hand fractures and physeal fractures (Böstman et al. 1989, Böstman 1991, 1995, Hope et al. 1991, Mäkelä et al. 1992, Pihlajamäki et al. 1992, Sinisaari et al. 1996). We investigated whether self-reinforced polyglycolic acid (SR-PGA) screws could induce epiphysiodesis of the greater trochanter in rabbits.

Animals and method

15 New Zealand white rabbits aged 10 weeks and weighing $1,700 \pm 0.2$ kg were used. Through an incision over the left greater trochanter, and after expos-

ing the lateral face, respecting its vertex, a 4.5 mm diameter PGA screw (Biofix[®]) was implanted reaching the opposite cortex, after 3.2 mm drilling and using a 4.5 mm tap. The same operation was performed on the right greater trochanter, though without implanting a screw. Intramuscular Cefazolin was used as antibiotic prophylaxis (100 mg/kg), beginning preoperatively and continuing for 3 days.

The animals were assigned to 3 subgroups of 5 rabbits (A, B and C) according to the postoperative follow-up (1, 2 and 3 months, respectively). Radiographs were taken in a standardized anteroposterior projection of both femurs preoperatively, after the operation and monthly until the death of the animals. In these radiographs, the articulo-trochanteric distance (ATD) and neck-shaft angle (NSA) were measured. All the animals survived the intervention. One animal in group A and another in group C died in the first postoperative week, due to diarrhea.

After killing, both femurs were extracted for histological study, by means of methacrylate inclusion. Histological preparations were stained with toluidine blue.

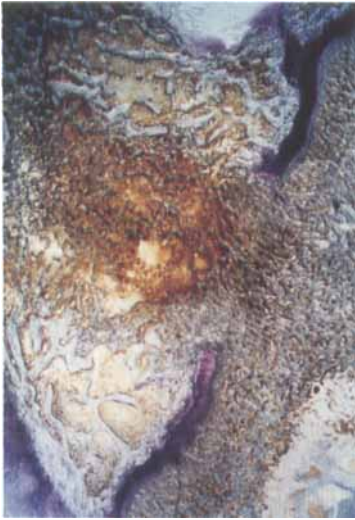

Figure 1. Right greater trochanter specimen 1 month postoperative. Bone tissue has developed filling the entire hole across the growth plate (Toluidine blue $\times 40$).

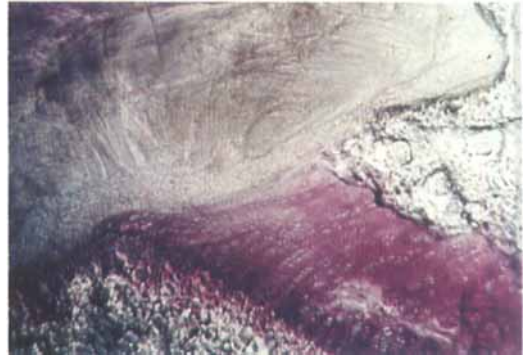


Figure 2. Left greater trochanter specimen 1 month postoperative. Intimate contact between the SR-PGA screw and the physis. Bone tissue formation across the hole was not observed, although it was possible to observe small physeal fragments pulled to the metaphysis by the screw itself (Toluidine blue $\times 600$).

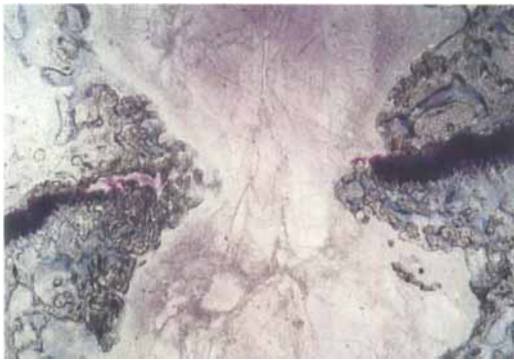

Figure 3. Left greater trochanter specimen 2 months postop. Peripheral SR-PGA screw degradation allowed some bone formation from both sides of the growth plate, across the physis (Toluidine blue $\times 100$).

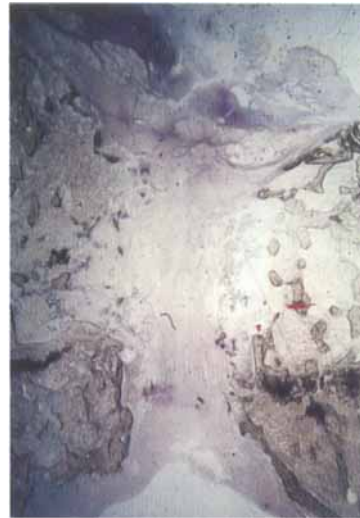


Figure 4. Left greater trochanter specimen 3 months postop. Greater degradation of SR-PGA screw was accompanied by more bone tissue formation across the growth plate, without reaching the magnitude of the bone bridge observed in the right greater trochanter (Toluidine blue $\times 40$).

Results

In the extracted femurs, caseous accumulations were observed in the left femur of 3 animals, without exterior fistulization, and cultures were positive for *Pasteurella Multocida*.

The screws maintained their macroscopic shape in the animals killed after 1 month (Group A), but were not recognizable later. Due to the morphology of the proximal rabbit femur, ATD values were always negative. No substantial evolutionary variations were observed in the ATD and NSA values. No fractures were observed.

Histologically, a bony bridge was found in the right

trochanter of all animals from the first postoperative month (Figure 1). This bony bridge filled the whole growth plate perforation and matured progressively. The screw which maintained its morphology at 1 postoperative month, prevented the formation of bony tissue through the growth plate perforation (Figure 2).

2 months postoperatively, the peripheral degradation of the screw permitted the formation of bony tissue from both sides of the growth plate giving rise to small marginal bony bridges (Figure 3). 3 months postoperatively, the greater degradation of the screw was accompanied by more bony growth through the physis in the periphery of the screw, although without reaching the dimensions of the physary bridge ob-

served in the right greater trochanter (Figure 4). At this time, thinning of the trochanter physis was observed, with progressive ossification, due to the skeletal maturation of the animal.

Discussion

For epiphyseodesis, fixation of the transposed greater trochanter with metallic screws is the commonest technique (Langenskiöld and Salenius 1967, Gage and Cary 1980, Tauber et al. 1980, Lloyd-Roberts et al. 1985, Stevens and Coleman 1985, Macnicol and Makris 1991, Bialik and Rosenberg 1994). The use of absorbable osteosynthesis implants has become more frequent in clinical practice (Böstman et al. 1989, Böstman 1991, 1995, Hope et al. 1991, Mäkelä et al. 1992, Pihlajamäki et al. 1992, Sinisaari et al. 1996). However, absorbable screws have smaller compression capacity, albeit sufficient to maintain the stability of the osteotomy or of the fracture in which they are applied, once it has been reduced (Böstman 1991, Böstman et al. 1995). Their application to physal fractures has not shown to damage the growth plate (Böstman et al. 1989, Hope et al. 1991, Mäkelä et al. 1992, Donigian et al. 1993).

All the animals in our study developed a bony bridge in the physis after perforation by drilling, as in previous reports (Siffert 1956, Garcés et al. 1994). In the trochanter with an SR-PGA screw, our histological observations showed that, while the screw maintained its structure, it prevented the formation of a bony bridge, in a similar way to that observed by other authors with other materials (Langenskiöld 1967, Lee et al. 1993, Stadelmaier et al. 1995). However, our radiographic measurements suggest that the compression capacity of PGA screws was insufficient to prevent physal growth (Strobino et al. 1956, Siffert 1966).

As reported by other authors (Mäkelä et al. 1989, Otsuka et al. 1992), the peripheral degradation of the PGA implant 2 months postoperatively gave rise to the formation of only slight bony bridges through the growth plate, which were insufficient to prevent physal growth. The more advanced degradation of the PGA screws at 3 months permitted development of slightly larger peripheral bony bridges, though always smaller than those observed in the controls which had only been treated by drilling.

The PGA screws were unable to promote epiphyseodesis of the greater trochanter in rabbits, and our findings suggest the value of these absorbable PGA implants as simple material for interposition in the treatment of a bony physal bridge.

References

- Bialik V, Rosenberg N. Transfer of greater trochanter. *J Pediatr Orthop (B)* 1994; 3: 30-4.
- Böstman O M. Absorbable implants for the fixation of the fractures. *J Bone Joint Surg (Am)* 1991; 73: 148-53.
- Böstman O M, Mäkelä E A, Törmälä P, Rokkanen P. Transphysal fracture fixation using biodegradable pins. *J Bone Joint Surg (Br)* 1989; 71: 706-7.
- Böstman O M, Pihlajamäki H K, Partio E K, Rokkanen P U. Clinical biocompatibility and degradation of polylevolactide screws in the ankle. *Clin Orthop* 1995; 320: 101-9.
- Donigian A M, Plaga B R, Caskey P M. Biodegradable fixation of physal fractures in goat distal femur. *J Pediatr Orthop* 1993; 13: 349-54.
- Gage J R, Cary J M. The effects of trochanteric epiphyseodesis on growth of the proximal end of the femur following necrosis of the capital femoral epiphysis. *J Bone Joint Surg (Am)* 1980; 62: 785-94.
- Garcés G L, Múgica Garay Y, Lopez Gonzalez Coviella N, Guerado E. Growth plate modifications after drilling. *J Pediatr Orthop* 1994; 14: 225-8.
- Hope P G, Williamson D M, Coates C J, Cole W G. Biodegradable pin fixation of elbow fractures in children. *J Bone Joint Surg (Br)* 1991; 73: 965-8.
- Langenskiöld A. The possibilities of eliminating premature partial closure of an epiphyseal plate caused by trauma or disease. *Acta Orthop Scand* 1967; 38: 267-79.
- Langenskiöld A, Salenius P. Epiphyseodesis of the greater trochanter. *Acta Orthop Scand* 1967; 38: 199-219.
- Lee E H, Gao G X, Bose K. Management of partial growth arrest: physis, fat or silastic?. *J Pediatr Orthop* 1993; 13: 368-72.
- Lloyd-Roberts G C, Wetherill M H, Fraser M. Trochanteric advancement for premature arrest of the femoral capital growth plate. *J Bone Joint Surg (Br)* 1985; 67: 21-4.
- Macnicol M F, Makris D. Distal transfer of the greater trochanter. *J Bone Joint Surg (Br)* 1991; 73: 838-41.
- Mäkelä E A, Vainionpää S, Vihtonen K, Mero M, Helevirta P, Törmälä P, Rokkanen P. The effect of a penetrating biodegradable implant on the growth plate. An experimental study on growing rabbits with special reference to polydioxanone. *Clin Orthop* 1989; 241: 300-8.
- Mäkelä E A, Böstman O M, Kekomäki M, Södergård J, Vainio J, Törmälä P, Rokkanen P. Biodegradable fixation of distal humeral physal fractures. *Clin Orthop* 1992; 283: 237-43.
- Otsuka N, Mah J Y, Orr F W, Martin R F. Biodegradation of polydioxanone in bone tissue: effect on the epiphyseal plate in immature rabbits. *J Pediatr Orthop* 1992; 12: 177-80.
- Pihlajamäki H, Böstman O M, Manninen M, Päiväranta U, Törmälä P, Rokkanen P. Absorbable plugs of self-reinforced poly-L-lactic acid for fixation of fractures and osteotomies. *J Bone Joint Surg (Br)* 1992; 74: 853-7.
- Siffert R S. The effect of staples and longitudinal wires on epiphyseal growth. An experimental study. *J Bone Joint Surg (Am)* 1956; 38: 1077-88.
- Siffert R S. The growth plate and its affections. *J Bone Joint Surg (Am)* 1966; 48: 546-63.

- Sinisaari I, Pätäälä H, Böstman O M, Mäkelä E A, Hirvensalo E, Partio E K, Törmälä P, Rokkanen P. Metallic or absorbable for ankle fractures. A comparative study of infection in 3111 cases. *Acta Orthop Scand* 1996; 67: 16-8.
- Stadelmaier D M, Arnoczky S P, Dodds J, Ross H. The effect of drilling and soft tissue grafting across open growth plates. A histologic study. *Am J Sports Med* 1995; 23: 431-5.
- Stevens P M, Coleman S S. Coxa breva: Its pathogenesis and a rationale for its management. *J Pediatr Orthop* 1985; 5: 515-21.
- Strobino L J, Colonna P C, Brodey R S, Leinbach T. The effect of compression on the growth of epiphyseal bone. *Surg Gyn Obst* 1956; 103: 85-93.
- Tauber C, Ganel A, Horoszowski H, Farine Y. Distal transfer of the greater trochanter in coxa vara. *Acta Orthop Scand* 1980; 51: 661-6.