

One-level cervical spine fusion

A randomized study, with or without plate fixation, using radiostereometry in 27 patients

Björn Zoëga, Johan Kärrholm and Bengt Lind

We randomized 27 consecutive patients undergoing 1-level cervical disc surgery to surgery with or without anterior plate fixation. The patients were studied with radiostereometry and clinically with visual analogue scores (VAS) for arm and neck pain. After 2 years, 1 patient had developed pseudoarthrosis, all other fusions were healed, but 1 patient showed substantial motions in the fusion area between the 1- and 2-year follow-ups. The 12 patients operated

on without a plate had increased rotations around the transverse axis, corresponding to deformation towards kyphosis. Clinically, there was no difference in outcome between the two groups, as assessed by VAS.

The use of an anterior plate in 1-level degenerative disc surgery in the cervical spine seems to prevent rotational deformation, without affecting the clinical outcome or fusion healing.

Department of Orthopaedics, Sahlgrenska University Hospital, SE-413 45 Göteborg, Sweden. Tel +46 31-601000
Fax -823584
Submitted 97-09-24. Accepted 98-03-10

Anterior plating of the lower cervical spine was initially introduced by Bohler and Gaudernak (1980). Since then, several authors have described the clinical success of plate fixation in the treatment of cervical spine fractures (Gassman and Seligson 1983, Caspar et al. 1989, Aebi et al. 1991). More recently, the indications for this procedure have been expanded to include degenerative conditions (Tippets and Apfelbaum 1988). A few preliminary reports of cases operated on because of degenerated disc disease on 1 level have been presented (Connolly et al. 1996), but the efficacy on this indication of operation remains to be demonstrated.

The purpose of this study was to evaluate whether the addition of a cervical spine locking plate (CSLP) (Synthes Switzerland) to a single-level fusion in degenerative disc disease really does enhance fusion and contribute to maintaining spinal alignment. The efficacy of the plate during the first 2 postoperative years was analyzed with radiostereometry (RSA).

Patients and methods

Between January 1994 and October 1995, we performed single-level anterior disc excision, followed by horseshoe-shaped autologous bonegrafting (Robinson and Smith 1955) in 27 patients (12 women). Their mean age was 41 (25–60) years. All patients

had pain and neurological symptoms corresponding to a 1-level MRI-verified herniated disc. The median time between onset of symptoms and operation was 18 (1–60) months.

15 patients (8 women) were randomized to stabilization with a graft and a CSLP plate and 12 patients (4 women) to grafting without fixation. Randomization was done with sealed envelopes opened on the day before surgery. The cervical spine was approached through an anterior incision on the left side of the neck. The anterior longitudinal ligament was excised over the disc space and the anterior half of the disc was removed macroscopically. The remaining posterior part of the nucleus pulposus and the herniated fragment were removed, using a microscope.

Before grafting, 3–7 tantalum markers (\varnothing 0.5 or 0.8 mm) were implanted in the adjacent vertebrae after predrilling through the cortex. The graft was harvested from the left anterior iliac crest. After surgery, patients operated on without a plate were treated with a Philadelphia collar for 6 weeks and those operated on with plate fixation used a soft collar for 6 weeks as recommended (Whitecloud 1983). The patients were examined with radiostereometry on the day after surgery, 2 weeks and 6 weeks postoperatively. They were examined clinically and with radiostereometry at 3, 6, 12 and 24 months postoperatively (Table 1). The study was approved by our local ethics committee.

Table 1. Number of cases examined with RSA

	Plate	No plate
1 day after surgery	15	12
2 weeks ^a	14	11
6 weeks ^b	12	12
3 months ^c	14	11
6 months	15	12
12 months ^d	15	11
24 months ^a	14	11

^a 2 patients did not attend.

^b 3 patients were not assessed because of lack of resources.

^c 2 patients were not assessed because of lack of resources.

^d 1 patient was not examined because of pregnancy.

^e 1 patient did not attend and 1 patient was reoperated on at that time

Radiostereometry

The patients were examined in the supine position, with the uniplanar technique (Kärrholm 1989). 2 roentgen tubes with central beams crossing at 40 degrees at the level of the cervical spine were used for simultaneous exposures of a pair of radiographs. A reference Plexiglas cage, fitted with tantalum markers, was placed between the patient and the roentgen films. The cage markers defined the laboratory coordinate system and were used to calculate the position of the roentgen foci. At the subsequent evaluation, the three-dimensional coordinates of the patient markers were determined at each examination.

The first postoperative examination was called the reference examination.

During the mathematical evaluation of the radiographic examinations, we used a software package (UmRSA, RSA Biomedical Innovations, Umeå, Sweden), mainly based on RSA according to Selvik (1989). The most distal vertebrae were used as a fixed reference segment. All movements were related to the laboratory coordinate system defined by the cage. The alignment of the patient with this system at the postoperative examination was chosen to repre-

sent the direction of the three cardinal axes at all subsequent examinations. Rotations of the more proximal vertebrae were calculated in the order 1) flexion-extension (rotations around the transverse axis), 2) left-right rotation of the head (longitudinal axis) and 3) left-right bending (anterior-posterior axis). In the following text, rotation between the postoperative examination and the following ones into flexion or extension is labeled kyphosis and lordosis, respectively. The relative translations of the center of gravity of the markers in the most proximal vertebrae were recorded in all but 6 patients (4 with plate fixation), where only 2 markers were available in the moving segment. In these cases, the mean value of the 2 markers represented translations, whereas rotations could not be evaluated. Translations were measured as 1) medio-lateral translations (left-right) 2) proximal-distal translations (compression) and 3) anterior-posterior translations. Only signed values were analyzed.

The accuracy of RSA depends on several factors. Some of the most important are the stability, spacing and number of markers (Kärrholm 1989). The degree of marker instability is expressed in mm as the mean error of rigid body fitting. In this study, only values below 0.35 mm were accepted. The spacing of the markers is expressed as a configuration number, reflecting how far from a straight line the markers are distributed (Kärrholm 1989). The mean error and the configuration number did not differ between the two patient groups (Mann-Whitney U-test, Table 2). Compared to previous studies of implant migration (Nilsson and Kärrholm 1993), we accepted higher configuration numbers, but only in cases with a low mean error of rigid fitting.

We calculated the reproducibility of the method by repeat radiostereometric examinations on the same day in all patients at different times during the follow-up period, corresponding to 23 double examinations (Table 3).

Table 2. Configuration number and mean error of rigid body fitting at the 1-year examination, mean, median and range. There were no differences between the 2 groups (Mann Whitney U-test) ^a

	Plate			No plate		
<i>Proximal vertebra (moving segment)</i>						
mean error, mm	0.18	0.16	0.05-0.31	0.19	0.19	0.05-0.34
configuration number	205	193	90-479	218	215	147-289
<i>Distal vertebra (reference segment)</i>						
mean error, mm	0.19	0.20	0.04-0.32	0.15	0.13	0.07-0.27
configuration number	231	185	118-548	218	215	147-289

^a In cases with a high configuration number between the postoperative and the last examination, the results were further validated by various comparisons of the motions between the 6 examinations.

Table 3. Mean difference, standard deviation (SD) and >99% confidence limits (99%CL; mean+ 2.8 SD) in 23 double examinations

	Difference	SD	99%CL
Translations mm			
anterior- posterior	0.12	0.16	0.56
proximal-distal	0.07	0.07	0.27
medial-lateral	0.25	0.20	0.81
Rotations degrees			
transverse axis	0.99	0.94	3.6
longitudinal axis	1.18	1.07	4.2
sagittal axis	0.39	0.33	1.3

Conventional radiographic examinations were done up to 1 year after the operation and fusions were considered healed, if there were signs of trabecular growth between the vertebrae and the graft. Pain in the neck and the arm were analyzed preoperatively and after 1 year, using a visual analogue scale (VAS).

Statistical methods

The statistical methods we used are indicated in the text for each calculation. To reduce the effect of missing observations, the analysis of repeated measurements was restricted to the 4 follow-up occasions between 6 weeks and 1 year, if not otherwise stated.

Results

Patients operated on without a plate had increased rotations around the transverse axis during the observa-

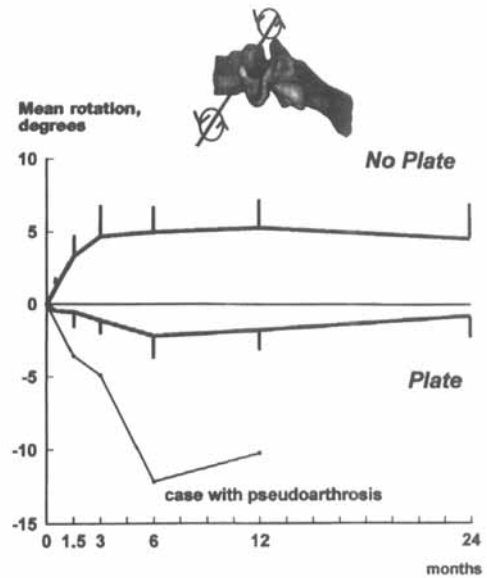


Figure 1. Mean rotation about the transverse axis of the most proximal vertebra in the fusion segment. Bars represent standard error of the mean (plate vs. no plate: $p < 0.05$). Positive value indicates rotation into kyphosis.

tion period, corresponding to the development of a kyphosis (6 weeks-1 year: $p = 0.04$; 2 weeks-2 years: $p = 0.06$) (Table 4). At 2 years, the kyphosis reached a mean of 5 (-5.0° - 17.7°) degrees compared to 1 (range -7.4° - 6.4°) degree of lordosis in those operated on with a plate (Figure 1).

At 2 years, the mean compression between the center of the 2 vertebrae was 1.3 mm in the group with

Table 4. Rotations and translations at 2 weeks, 6 weeks, 3 months, 6 months, 12 months and 24 months with or without plate fixation. Median, lower range, upper range

Movement	2 weeks		6 weeks		3 months		6 months		12 months		24 months	
	with	without	with	without	with	without	with	without	with	without	with	without
<i>Translations (mm)</i>												
Medio-lateral	0.0	-0.1	0.1	0.0	0.1	-0.1	0.0	-0.1	0.1	-0.2	0.2	0.0
-right	-0.4	-1.0	-0.7	-0.9	-1.8	-1.0	-0.7	-0.9	-0.7	-1.0	-0.7	-1.0
+left	0.5	0.2	0.6	0.5	0.8	-0.5	1.0	0.7	1.0	0.5	0.7	0.7
Proximal-distal	-0.4	-0.3	-0.5	-0.7	-0.7	-0.2	-1.0	0.2	-0.1	0.4	-1.0	-0.8
-distal	-2.1	-2.0	-3.3	-4.5	-3.6	-0.8	-3.7	-0.9	-2.8	-0.5	-3.2	-6.0
+proximal	-0.3	0.0	0.2	-0.1	0.0	1.0	0.2	1.0	1.1	1.0	0.1	0.1
Anterior-posterior	0.1	0.0	0.1	0.0	0.0	-0.2	0.1	0.2	-0.1	0.4	-0.2	0.1
-posterior	-0.6	-0.5	-1.0	-1.1	-1.1	-0.8	-3.0	-0.9	-2.8	-0.5	-1.5	-0.7
+anterior	0.6	0.9	0.5	0.7	0.4	1.0	0.3	1.0	1.1	1.0	0.5	1.0
<i>Rotations (degrees)</i>												
Transverse axis	-0.2	0.8	-0.3	2.6	-1.1	3.9	-1.4	4.1	-1.6	5.7	-0.8	4.3
-lordosis	-4.6	-1.1	-6.5	-4.0	-5.0	-2.5	-12.2	-4.1	-10.2	-3.7	-7.4	-5.0
+kyphosis	2.2	6.6	4.0	12.3	3.8	17.6	4.4	16.4	6.5	15.3	6.4	17.7
Longitudinal axis	0.8	-0.5	1.0	0.0	1.4	-0.3	1.1	0.1	0.9	0.7	0.8	0.5
-anterior tilt	-2.4	-4.0	-3.7	-3.4	-1.9	-3.5	-4.1	-2.7	-0.9	-4.4	-4.1	-4.6
+posterior tilt	2.8	1.4	3.2	2.6	4.0	1.1	3.1	4.1	3.8	2.8	5.1	3.9
Sagittal axis	-0.1	0.5	-0.4	-0.2	-0.8	0.8	0.3	0.6	-0.4	1.4	0.4	0.8
-right tilt	-2.3	-1.4	-1.8	-4.6	-2.3	-2.6	-3.4	-4.0	-3.1	-2.6	-2.7	-3.1
+left tilt	1.3	4.2	1.9	4.9	7.4	3.9	2.1	3.8	1.7	3.9	1.6	4.9

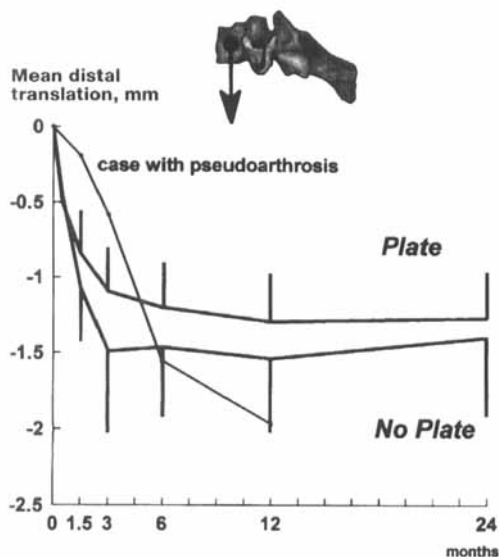


Figure 2. Mean distal translation (compression, negative value) of the most proximal vertebra in the fusion segment. Bars represent standard error of the mean (plate vs. no plate, not significant).

and 1.4 mm in the group without a plate ($p = 0.7$ repeated measure ANOVA) (Figure 2).

The anterior-posterior and medio-lateral translations and the rotations around the longitudinal and sagittal axes did not differ between the 2 groups ($p = 0.2$ and 0.5 , repeated measure ANOVA, Table 4).

1 patient, who was operated on with a plate, developed pseudoarthrosis. An increasing lordosis was seen up to 6 months after the first operation (Figure 2). The plate broke between the 3rd and the 6th months of follow-up (Figure 3). The patient was reoperated on 1 year after the index operation with an anterior refusion, but no plate, and immobilized with a Philadelphia collar for 3 months. This fusion healed after 4 months. Evaluation of conventional radiographs indicated that all other fusions had healed after 1 year.

4 other patients, 3 with a plate and 1 without, displayed small but significant motions ($p < 0.01$) between the 6th and 12th postoperative months. 1 patient operated on with a plate displayed significant motions ($p < 0.01$) between the 12th and the 24th months. However, on the plain radiographs, there were no signs of plate or screw loosening and no signs of pseudoarthrosis.

Clinically, there was no difference in arm pain ($p = 0.4$ Mann-Whitney-U test) or neck pain ($p = 0.6$ Mann-Whitney U-test) at the 2 year follow-up between the 2 groups (Table 5).

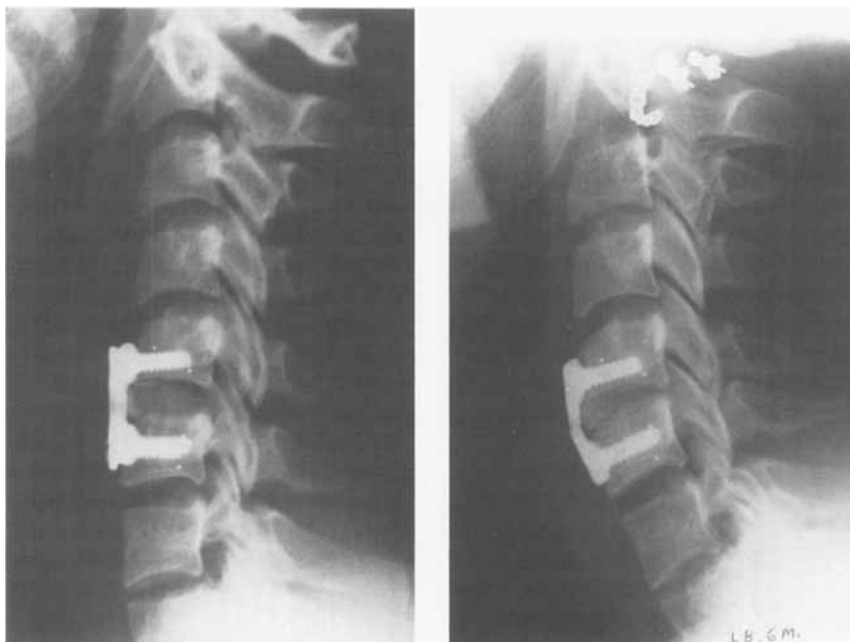

Figure 3. Postoperative radiograph of a patient who developed pseudoarthrosis (left). Same patient, 6 months postoperatively (right).

Table 5. VAS for arm and neck pain, preoperatively, at 3 months, 6 months, 12 months and 24 months with or without plate fixation. Median, range

Recorded value	Preoperatively		3 months		6 months		12 months		24 months	
	with	without	with	without	with	without	with	without	with	without
<i>Pain in the arm</i>	4.0	6.3	3.4	4.7	3.5	1.7	4.7	5.7	4.5	5.9
Range	1.0-9.5	2.9-8.6	0-9.5	0-6.4	0.1-9.5	0-7.7	0.4-6.5	0.1-8.5	0.3-8.0	0-7.8
<i>Pain in the neck</i>	5.4	6.3	3.7	4.6	4.8	2.9	5.4	5.6	5.8	5.6
Range	3.1-8.8	4.4-9.1	0.1-9.5	0.1-8.6	0.6-9.5	0.1-7.9	0.4-7.7	0.1-8.3	1.7-8.8	0-8.2

Discussion

Radiostereometry (RSA) is a technique with high accuracy for obtaining in vivo 3-dimensional measurements from radiographs (Selvik et al. 1983). In our study, there was a problem in obtaining sufficient scatter of the markers in some cases, due to difficulties in reaching the posterior part of the vertebra. This especially affected the accuracy of the rotations, when evaluated in the individual case. In the 2 groups of patients we studied, the marker configurations were equal, which implies that a relevant comparison can be made.

Patients without plate fixation developed kyphosis. Breig (1978) showed that an angular kyphosis increased the tensile forces in the spinal cord, which may reduce intramedullary blood circulation. However, the mean 5-6 degree kyphosis observed in our patients without a plate caused no symptoms.

The advantages of an anterior plate may be a shorter healing time and improved rate of fusion. The plate should withstand cyclic loading and stabilize the fused segments, until healing occurs. Many authors feel that a very stiff construct should lead to a higher rate of fusion (Sutterlin et al. 1988, Coe et al. 1989). This increased stiffness in the plated segments was also found in one mechanical analysis (Zdeblick et al. 1993). However, this may also lead to degenerative deterioration in the adjacent motion segments and contribute to pseudoarthrosis, by reducing the compressive forces over the fused area. According to our measurements, the translations of the center of the vertebrae along the longitudinal axis did not differ between the 2 groups. Nevertheless, 1 patient with a plate developed a pseudoarthrosis, whereas none in the group without a plate had this complication. We also noted that, between the 6th and 12th months, 3 other patients in the group with plate fixation had minor although significant movements as compared to only 1 patient in the group without a plate. This finding supports the hypothesis that the plate may act as an anterior stress shield, promoting late union and even pseudoarthrosis. Zdeblick et al. (1993) studied

the effect of plating on autograft incorporation in a goat model and found that plating had no effect on the healing rate. Histological analysis revealed even a diminution of peri-endplate vascularity in the plated group, which could suggest that the healing potential had decreased.

The clinical effect of a pseudoarthrosis has been much debated. Because of a high rate of success for the anterior decompression procedure, analysis of unsuccessful treatments has been difficult. DePalma et al. (1972), Robinson et al. (1962) and Williams et al. (1968) all reported approximately a 12% incidence of pseudoarthrosis, without any obvious association with clinical failure. However, Riley et al. (1969) reported better results in patients whose fusion healed. White et al. (1973a) found that 73% of the patients with bony union had good-to-excellent clinical results. In cases with pseudoarthrosis, the corresponding frequency was 53%. Zhang et al. (1983) reported 121 patients who were operated on with the Smith-Robinson technique, using autografts. 80% of the patients with bony union and 22% with pseudoarthrosis had good results. The one patient with pseudoarthrosis in our study had a poor clinical outcome.

Both groups displayed minor compression, without any significant difference between them, probably due to the comparatively great strength of the tricortical horseshoe-graft. Mechanical testing of load-to-failure in three different grafting techniques has shown that the Smith-Robinson tricortical graft is the strongest of all bone grafts (White and Hirsch 1971, White et al. 1973b).

In conclusion, the use of an anterior plate in degenerative cervical spine surgery clearly prevented post-operative kyphosis, but did not, in this study, improve the clinical outcome. A small but insignificant tendency to delayed healing, reflected by continued motions between 6 and 12 months, and 1 case with pseudoarthrosis in the plated group, raises the question whether the plate, by counteracting compression, has a true negative influence on the healing rate and healing time.

- This study was supported with grants from the Gothenburg Medical Society, IngaBritt and Arne Lundberg Research Foundation, the Greta and Einar Askers Foundation and Bertha and Felix Neuberghs Foundation.
- Aebi M, Zuber K, Marchesi D. Treatment of cervical spine injuries with anterior plating. Indications, techniques and results. *Spine (Suppl 3)* 1991; 16: 38-45.
- Bohler G, Gaudernak T. Anterior plate stabilization for fracture dislocations of the lower cervical spine. *J Trauma* 1980; 20: 203-5.
- Breig A. Adverse mechanical tension in the central nervous system. An analysis of cause and effect. Relief by functional neurosurgery. John Wiley, New York, NY, 1978.
- Caspar W, Dragos D B, Klara P M. Anterior cervical fusion and Caspar plate stabilization for cervical trauma. *Neurosurgery* 1989; 25 (4): 491-502.
- Coe J D, Warden K E, Sutterlin C E, McAfee P C. Biomechanical evaluation of cervical spine stabilization methods in a human cadaveric model. *Spine* 1989; 14 (10): 1122-31.
- Connolly P J, Esses S I, Kostuik J P. Anterior cervical fusion: Outcome analysis of patients fused with and without anterior cervical plates. *J Spinal Disord* 1996; 9 (3): 202-6.
- DePalma A F, Rothman R H, Lewinneck R E et al. Anterior interbody fusion for severe cervical disc degeneration. *Surg Gynecol Obstet* 1972; 134: 755-8.
- Gassman J, Seligson D. The anterior cervical plate. *Spine* 1983; 8: 700-7.
- Kärholm J. Roentgen stereophotogrammetry. Review of orthopedic applications. *Acta Orthop Scand* 1989; 60: 491-503.
- Nilsson K G, Kärholm J. Increased varus-valgus tilting of screw-fixed knee prostheses. *J Arthroplasty* 1993; 8 (5): 529-40.
- Riley L, Robinson R, Johnson K et al. The results of anterior interbody fusion of the cervical spine. *J Neurosurg* 1969; 30: 127-33.
- Robinson R A, Smith G W. Anterolateral cervical disc removal and interbody fusion for the cervical disc syndrome. *Bull Johns Hopkins Hosp* 1955; 96: 223-4.
- Robinson R, Walker A, Ferlic D et al. The results of anterior interbody fusion of the cervical spine. *J Bone Joint Surg (Am)* 1962; 44: 1569-87.
- Selvik G, Alberius P, Aronson A S. A roentgen stereophotogrammetric system. Construction, calibration and technical accuracy. *Acta Radiol (Diagn)* 1983; 24 (4): 343-52.
- Selvik G. Roentgen stereophotogrammetry. A method for the study of the kinematics of the skeletal system. *Acta Orthop Scand (Suppl 232)* 1989: 60.
- Sutterlin C E, McAfee P C, Warden K E, Rey R M, Farey I D. A biomechanical evaluation of cervical spine stabilization in a bovine model. Static and cyclic loading. *Spine* 1988; 13: 795-802.
- Tippett R H, Apfelbaum R I. Anterior cervical fusion with the Caspar instrumentation system. *Neurosurgery* 1988; 22: 1008-13.
- White A A, Hirsch C. An experimental study of the immediate load bearing capacity of some commonly used iliac bone grafts. *Acta Orthop Scand* 1971; 42: 482-90.
- White A, Southwick W, Deponte R et al. Relief of pain by anterior cervical spine fusion for spondylosis. *J Bone Joint Surg (Am)* 1973a; 55: 525-34.
- White A A, Jupiter J, Southwick W O, Panjabi M M. An experimental study of the immediate load-bearing capacity of three surgical constructions for anterior spine fusions. *Clin Orthop* 1973b; 91: 21-8.
- Whitecloud T. Management of radiculopathy and myelopathy by the anterior approach. In: *Cervical Research Society (eds.). The Cervical Spine*. Lippincott, Philadelphia, PA 1983: 411-24.
- Williams J, Allen M, Harkess J. Late results of cervical discectomy and interbody fusion: Some factors influencing the results. *J Bone Joint Surg (Am)* 1968; 50: 277-86.
- Zdeblick T A, Cooke M E, Wilson D et al. Anterior cervical discectomy, fusion and plating: A comparative animal study. *Spine* 1993; 18: 1974-83.
- Zhang Z H, Yin H, Yang K et al. Anterior intervertebral disc excision and bone grafting in cervical spondylotic myelopathy. *Spine* 1983; 8: 16-9.