

Case reports

Migration of Kirschner wires following fixation of the clavicle—a report of 2 cases

Juhana Leppilähti and Pekka Jalovaara

Department of Surgery, Oulu University Hospital, PL 22, FI-90220 Oulu, Finland. Tel +358 8 315–2011. Fax –5318.

Correspondence: Prof. Pekka Jalovaara

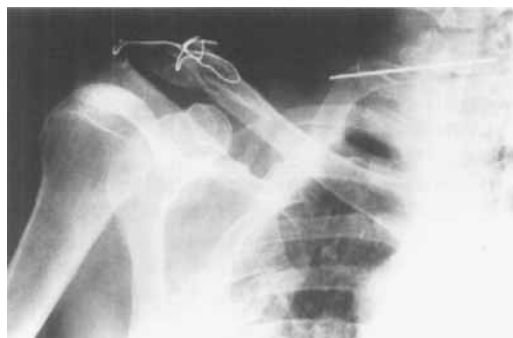Submitted 99-03-27. Accepted 99-07-01

Case 1

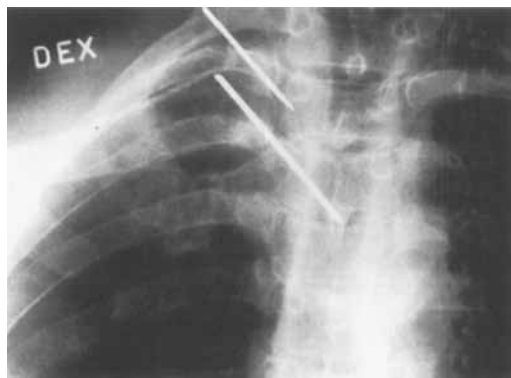
A 56-year-old man was involved in a traffic accident. One of his injuries was a comminuted lateral fracture of the right clavicle. Because of the risk of skin perforation, an open reduction and a steel wire loop fixation of the fracture, with an unthreaded Kirschner wire inserted through the acromion into the clavicle, was performed 19 days after the injury. The free end of the unthreaded wire was not bent. Radiographs taken on the fourth postoperative day showed that the pin had migrated medially through the cortical bone of the clavicle, and 2 days later it appeared to have moved further medially. Radiographs taken on the eleventh day showed that the wire had migrated outside the clavicle across the midline of the neck, with its tip lying on the anterior side of the cervical spine behind the trachea. It was immediately removed.

Case 2

A 48-year-old man had a traumatic dislocation of the right sternoclavicular joint, which was not treated at once. It continued to be painful, howev-



Case 1. Lateral fracture of the right clavicle in a 56-year-old man 11 days postoperatively. The pin has migrated to the neck between the cervical spine and the trachea.

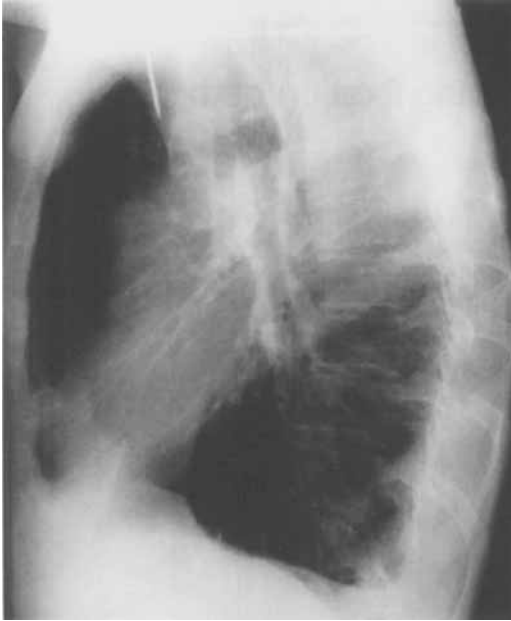

Case 2. Radiograph showing traumatic dislocation of the right sternoclavicular joint taken immediately after reduction and fixation of the joint with a plantaris tendon graft and 2 Kirschner wires.

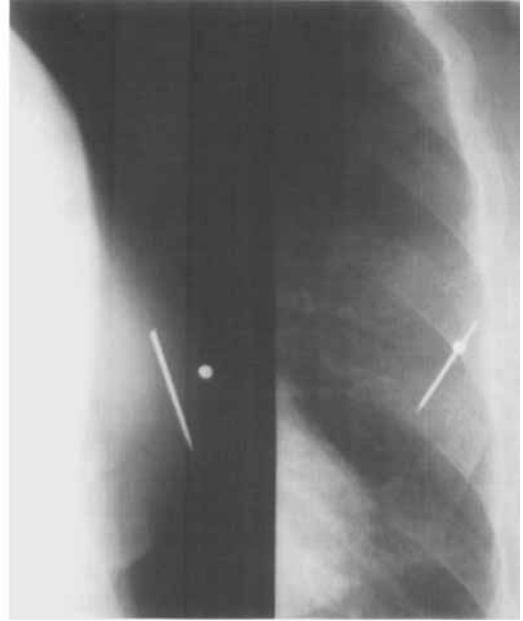
er, and a reconstruction of the joint with a plantaris tendon was therefore performed 1 year after the accident. The fixation was secured with two unthreaded Kirschner wires, which were not bent. On a follow-up examination 26 days after the operation, the fixation was found to have failed and one of the pins appeared to have migrated into the mediastinum. It was removed on the following day through a mediastinostomy, during which the tip of the pin was seen to touch the aortic arch. The sternoclavicular joint remained painful, and resection of the medial head of the clavicle was performed 3 months later. The remaining pin was not found at this operation. Postoperative radiographs showed the missing pin in the subcutaneous tissue of the contralateral mamillar region, and it was extracted 3 days later.

Discussion

The migration of various internal fixation devices, especially Kirschner wires, is well established.



Case 2. 26 days after the operation, one of the wires had migrated into the mediastinum.



Case 2. The other wire was located subcutaneously in the left mamillar region.

The wires usually follow a retrograde path, protruding near their entry point. Occasionally, however, they migrate in another direction. This may cause serious harm. A few cases of remarkable Kirschner wire migration have been reported. Potter et al. (1988) described the migration of a Kirschner wire from the shoulder region to the spleen and Fuster et al. (1990) from the shoulder into the right hemithorax. Wires have been reported also to cause damage to major vascular structures such as the heart (Salvatore 1968), the subclavian artery (Grauthoff and Klammer 1978), the ascending aorta (Nettles and Lindscheid 1968), and the pulmonary artery (Janssens de Varebecke and Van Osselaer 1993). Other locations to which pins have migrated from the shoulder include the lung (Tristan and Daughtridge 1964) and the spinal canal (Norrell and Liewellyn 1965). Complications after reconstruction of the sternoclavicular joint with pin fixation have occurred in as many as one fourth of the cases (Worman and Leagus 1967). Some of the complications have been fatal due to migration of a Kirschner or Steinmann pin into the mediastinum and the heart, pulmonary artery or aorta (Leonard and Gifford 1965, Nettles and Lindscheid 1968, Salvatore 1968, Gerlach et al. 1984).

Muscular movements, gravity and capillary action have been thought to cause migration, but the primary etiology remains obscure (Potter et al. 1988). Bending of the pins and the use of threaded pins have been proposed to prevent migration (Gerlach et al. 1984, Lindsay and Gutowski 1986). However, not even these methods can eliminate the risk of migration, which has also been reported in cases of threaded Steinmann pins (Norrell and Liewellyn 1965) and even after fixation of the pin with bone cement (Jorden et al. 1983).

Fuster S, Palliso F, Combalia A, Sanjuan A, Garcia S. Intrathoracic migration of a Kirschner wire. *Injury* 1990; 21: 124-6.

Gerlach D, Wemhöner S-R, Ogbuihi S. Ueber Zwei Fälle von Herzbeutel-tamponade infolge Migration von Spickdrähten aus dem Sternoclaviculargelenk. *Z Rechtsmed* 1984; 93: 53-60.

Grauthoff V H, Klammer H L. Komplikationen durch Drahtwanderungen nach Kirschnerdraht-spickungen an der Klavikula. *Fortschr. Geb Röntgen* 1978; 128: 591-4.

Janssens de Varebecke B, Van Osselaer G. Migration of Kirschner's pin from the right sternoclavicular joint resulting in perforation of the pulmonary artery main trunk. *Acta Chir Belg* 1993; 93: 287-91.

Jorden S E, Bremer A M, Nguyen T Q. An unusual late complication of acrylic spinal fusion: case report. *Neurosurg* 1983; 13: 441-2.

- Leonard J W, Gifford R W Jr. Migration of a Kirschner wire from the clavicle into the pulmonary artery. *Am J Cardiol* 1965; 16: 598-600.
- Lindsay R W, Gutowski W T. The migration of a broken pin following fixation of the acromioclavicular joint. *Orthopedics* 1986; 9: 413-6.
- Nettles J L, Linscheid R L. Sternoclavicular dislocations. *J Trauma* 1968; 8: 158-64.
- Norrell H Jr, Liewellyn R C. Migration of a threaded Steinmann pin from an acromioclavicular joint into the spinal canal: a case report. *J Bone Joint Surg (Am)* 1965; 47: 1024-6.
- Potter F A, Fiorini A J, Knox J, Rajesh P B. The migration of a Kirschner wire from shoulder to spleen: brief report. *J Bone Joint Surg (Br)* 1988; 70: 326-7.
- Salvatore J E. Sternoclavicular joint dislocation *Clin Orthop* 1968; 58: 51-5.
- Tristan T A, Daughtridge T G. Migration of a metallic pin from the humerus into the lung. *N Engl J Med* 1964; 270: 987-9.
- Worman L W, Leagus C. Intrathoracic injury following retrosternal dislocation of the clavicle. *J Trauma* 1967; 7: 416-8.

Late posttraumatic compartment syndrome in the axillary neurovascular sheath—a case report

Sven Byström¹ and Bertil Vinnars²

Departments of ¹Orthopedics and ²Hand Surgery, Uppsala University Hospital, Uppsala, Sweden. Correspondence: Dr. Sven Byström, Department of Orthopedic Surgery, Haukeland University Hospital, NO-5021 Bergen, Norway. Tel +47 55 97 56-80. Fax -97. E-mail: sbys@haukeland.no
Submitted 97-10-19. Accepted 99-06-25

A previously healthy 48-year-old man with alcohol abuse fell onto his abducted left arm. Plain radiographs revealed an anterior dislocation of the shoulder joint. The dislocation was easily reduced during light anesthesia and control radiographs were normal. Distal pulses were normal. Neurological examination revealed slight numbness of the lateral aspect of the shoulder and volar side of the forearm and hand which was interpreted as partial sensory loss involving the axillary, ulnar and median nerves. Motor function of the forearm

and hand was normal. The shoulder joint was immobilized with a collar-and-cuff sling and the patient was discharged with a clinical follow-up in 2 weeks.

1 week later, the patient returned because of increasing numbness and swelling of the shoulder and arm and reported that it had started 4 days after the trauma. In addition to substantial edema of the entire arm, abduction of the shoulder joint was not possible. Flexion and extension of the elbow were weak and there was practically no motor

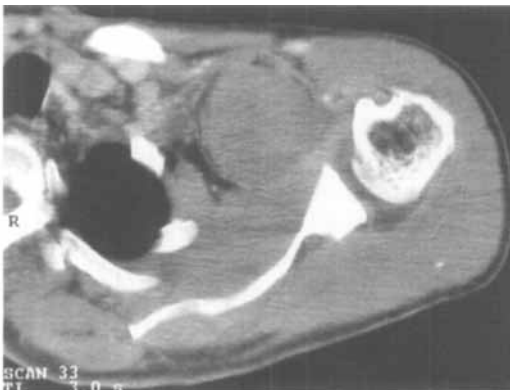
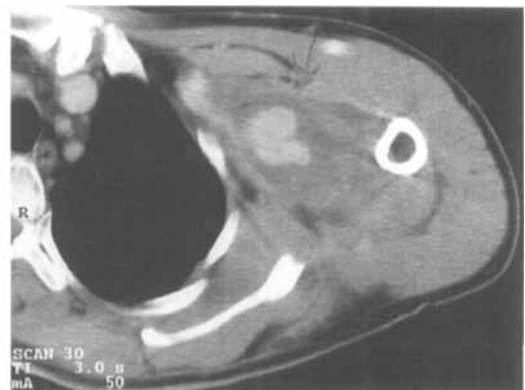


Figure 1. CT of the left shoulder at a level just below the major tubercle. The arrows indicate the limits of the large hematoma. The vascular tear was located at the junction of the circumflex humeral and axillary arteries.



CT of the left shoulder at a level approximately 10 cm below the major tubercle. Note that the hematoma dissected down into the neurovascular sheath well below the axilla. The light areas in the center of the hematoma indicate leakage of contrast fluid.