

ditional soft tissue stripping for the placement of large implants. The mechanism of action of Ilizarov's circular external fixator in olecranon fractures is similar to that of tension-band osteosynthesis since there are two groups of wires perpendicular to each other, compressing the fracture site during active elbow motion. The use of three 1.5 mm K-wires has the advantage of being the least invasive osteosynthesis method. Another advantage of this method is that the wires can be removed under local anesthesia, with minimal soft tissue injury. With this technique, we had a good outcome in our 3 patients.

- Fyfe I S, Mossad M M, Holdsworth B J. Methods of fixation of olecranon fractures. An experimental mechanical study. *J Bone Joint Surg (Br)* 1985; 67 (3): 367-72.
- Goldstock L E, Jupiter J B, Lins R E. Elbow trauma. In: Orthopaedic knowledge update—Trauma (Ed Levine A M). American Academy of Orthopaedic Surgeons, Rosemonth, IL 1996; 47-55.
- Gustilo R B, Anderson J T. Prevention of infection in the treatment of one thousand and twenty-five open fractures of long bones: Retrospective and prospective analysis. *J Bone Joint Surg (Am)* 1976; 58 (4): 453-8.
- Hotchkiss R N, Green D P. Fractures and dislocations of the elbow. In: Rockwood and Green's fractures in adults (Eds. Rockwood C A, Green D P, Bucholz R W). Lippincott Co. Philadelphia 1991; 1: 795-805.
- Hume M C, Wiss D A. Olecranon fractures. A clinical and radiographic comparison of tension band wiring and plate fixation. *Clin Orthop* 1992; 285: 229-35.
- Ilizarov G A. Transosseous osteosynthesis, theoretical and clinical aspects of the regeneration and growth of tissue. Springer Verlag, Berlin 1992; 369-452.
- King G J, Lammens P N, Milne A D, Roth J H, Johnson J A. Plate fixation of comminuted olecranon fractures: An in-vitro biomechanical study. *J Shoulder Elbow Surg* 1996; 5 (6): 437-41.
- Kiviluoto O, Santavirta S. Fractures of the olecranon. Analysis of 37 consecutive cases. *Acta Orthop Scand* 1978; 49: 28-31.
- Kozin SH, Berglund LJ, Cooney WP, Morrey BF, An KN. Biomechanical analysis of tension band fixation for olecranon fracture treatment. *J Shoulder Elbow Surg* 1996; 5(6): 442-448.
- Larsen E, Jensen CM. Tension-band wiring of olecranon fractures with nonsliding pins. Report of 20 cases. *Acta Orthop Scand* 1991; 62(4): 360-362.
- Macko D, Szabo R M. Complications of tension band wiring of olecranon fractures. *J Bone Joint Surg (Am)* 1985; 67 (9): 1396-401.
- Morrey B F. Current concepts in the treatment of fractures of the radial head, the olecranon and the coronoid. *J Bone Joint Surg (Am)* 1995; 77 (2): 316-27.
- Müller M E, Allgöwer M, Schneider R, Willenegger H. Manual of internal fixation. Techniques recommended by the AO group. Springer-Verlag, Berlin Heidelberg New York 1991.
- Murphy D F, Greene W B, Gilbert J A, Dameron T B. Displaced olecranon fractures in adults. Biomechanical analysis of fixation devices. *Clin Orthop* 1987a; 224: 210-4.
- Murphy D F, Greene W B, Dameron T B. Displaced olecranon fractures in adults. Clinical evaluation. *Clin Orthop* 1987b; 224: 215-23.
- Papagelopoulos P J, Morrey B F. Treatment of nonunion of olecranon fractures. *J Bone Joint Surg (Br)* 1994; 76 (4): 627-34.
- Paremain G P, Novak V P, Jinnah R H, Belkoff S M. Biomechanical evaluation of tension band placement for the repair of olecranon fractures. *Clin Orthop* 1997; 335: 325-30.
- Rowland S A, Burkhardt S S. Tension band wiring of olecranon fractures. A modification of the AO technique. *Clin Orthop* 1992; 277: 238-42.
- Teasdall R, Savoie F H, Hughes J L. Comminuted fractures of the proximal radius and ulna. *Clin Orthop* 1993; 292: 37-47.
- Wesley M S, Barenfeld P A, Eisenstein A L. The use of Zuelzer hook plate in fixation of olecranon fractures. *J Bone Joint Surg (Am)* 1976; 58 (6): 859-62.
- Wolfgang G, Burke F, Bush D, Parenti J, Perry J, LaFollette B, Lilmars S. Surgical treatment of displaced olecranon fractures by tension band wiring technique. *Clin Orthop* 1987; 224: 192-204.

The crowded wrist—a case with accessory carpal bones

Nusret Köse¹, Abdurrahman Özçelik¹ and Izge Günal²

Departments of Orthopaedics and Traumatology, ¹Osmangazi University, School of Medicine, Meselik, Eskisehir, Turkey. Tel +90 222 -2313584. Fax -2309632. E-mail: nkose@mail.ogu.edu.tr; ²Dokuz Eylül University, School of Medicine, Izmir, Turkey

Submitted 98-04-17. Accepted 98-10-13

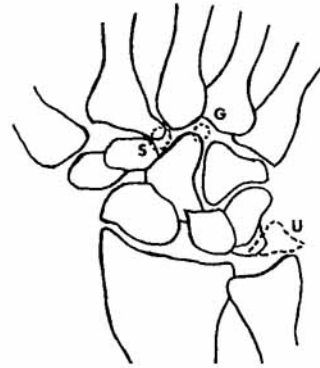
An 18-year-old student had felt pain for 3 weeks in her dominant right wrist, localized to the midcarpal area. The onset was gradual and she reported no previous injury.

The right wrist had 20 degrees less flexion-extension movements than the left side (Günal et al. 1996). The patient had some pain at the extremes of range of motion and tenderness over the dorsal midcarpal area.

Anteroposterior radiographs of both wrists showed bilaterally separated ulnar styloid processes (accessory os ulnostyloideum). Careful examination of the radiographs revealed two other accessory carpal bones: os Gruber, between the capitate, hamate, and the third and fourth metacarpals, and os styloideum, which is associated with a well developed third metacarpal styloid process, between the trapezoid, capitate, and the

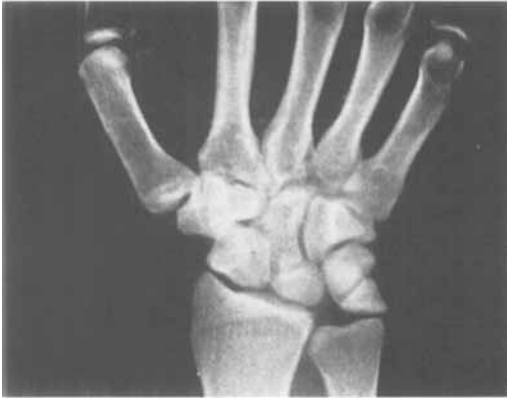

Figure 1.
A. Three congenital accessory bones.



B. Line drawing of the left wrist. U os ulnostyloideum, G os Gruber, S os styloideum.

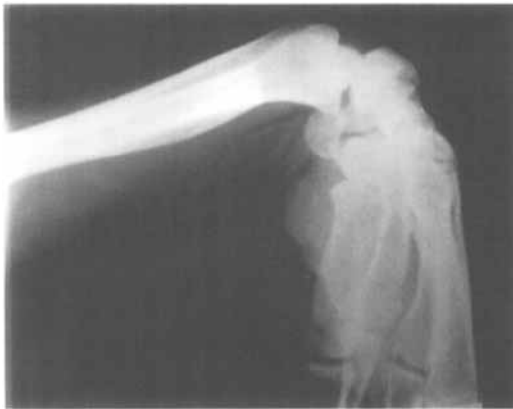

Figure 2. On the lateral radiograph of the flexed wrist, a dorsally subluxated lunate can be seen.

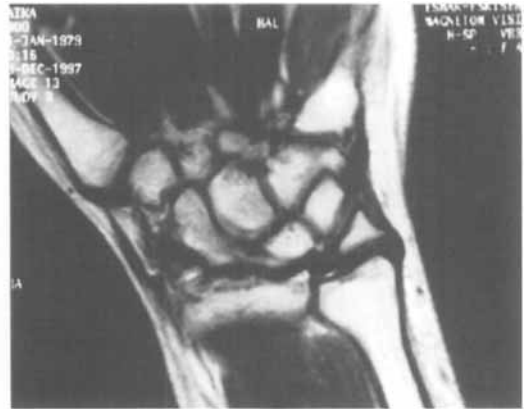


Figure 3. MRI arthrogram shows no radioopaque dye between accessory bones, lunate, and ulna, which indicates intact ligaments between them.

second and third metacarpals (Figure 1). The scaphoid appeared shortened, there was a mild increase in the scapho-lunate gap and no parallelism between the opposing articular surfaces of the scaphoid and lunate on the anteroposterior radiographic views. On the lateral view of the flexed wrist, the lunate was dorsally subluxated (Figure 2). There were no signs of arthritis in the wrist. MRI showed no evidence of carpal ligament injury and no radioopaque dye between the accessory ulnostyloid bone, lunate, and ulna, which indicates intact ligaments between them (Figure 3). No other abnormalities were noted. The pain decreased with a removable splint.

Discussion

Accessory carpal bones are of diagnostic interest, since they may be misinterpreted as fractures, or soft tissue calcifications. They are found in various con-

genital malformation syndromes (Kelikian 1974, Resnick 1988, Yang et al. 1994). Real accessory carpal bones are rare, with an incidence of 0.3%–1.6% (Lane et al. 1990). O’Rahilly in 1953, in a comprehensive study of accessory carpal bones, suggested that they should be called by names related to their position or shape.

The presence of accessory bones can be overlooked on radiographs because of overlap by adjacent bones. In previously published cases, accessory carpal bones usually appeared as round small bony fragments situated palmarly or dorsally. They were not seen as a functioning part of the wrist joint and were usually incidental findings of no clinical significance (Gerscovich and Greenspan 1990, Lane et al 1990).

In our patient, the accessory carpal bones were an isolated anomaly with no associated syndrome. The patient was symptomatic and had three accessory carpal bones bilaterally, one of which was an os ulnostyloideum, which appeared as a well demarcated inde-

pendent functional part of the wrist joint. The ulnar styloid was not present. The patient had a mildly increased scapho-lunate gap with no parallelism between the opposing articular surfaces, a shortened appearance of the scaphoid on the anteroposterior view and an abnormal carpal alignment on the lateral radiographs which are considered characteristics of carpal instability (Green 1993). The “crowding” of the wrist may disturb coordinated movements of the carpal bones and, when moving from flexion to extension, the lunate is forced to displace dorsally, which results in carpal instability and wrist pain. The differential diagnosis of subtle carpal instability and wrist pain should include accessory carpal bones.

Gerscovich E O, Greenspan A. Case report 598 (Os centrale carpi). *Skeletal Radiol* 1990; 19: 143-5.

Green D P. Carpal dislocations and instabilities. In: *Operative hand surgery* (Ed. Green D P). Churchill Livingstone, New York 1993; 1: 861-928.

Günel I, Köse N, Erdogan O, Göktürk E, Seber S. Normal range of motion of the joints of the upper extremity in male subjects, with special reference to side. *J Bone Joint Surg (Am)* 1996; 78: 1401-4.

Kelikian H. *Congenital deformities of the hand and forearm*. W B Saunders Co., Philadelphia 1974; 714-52.

Lane L B, Gould E S, Stein P D, Coffey E. Unilateral osteonecrosis in a patient with bilateral os centrale carpi. *J Hand Surg (Am)* 1990; 15: 751-4.

O’Rahilly R. A survey of carpal and tarsal anomalies. *J Bone Joint Surg (Am)* 1953; 35: 626-42.

Resnick D. Additional congenital or heritable anomalies and syndromes. In: *Diagnosis of bone and joint disorders* (Eds. Resnick D, Niwayama G). W B Saunders Co., Philadelphia 1988; 3540-600.

Yang Z Y, Gilula L A, Jonsson K. Os centrale carpi simulating a scaphoid waist fracture. *J Hand Surg (Br)* 1994; 19: 754-6.