

Systemic corticosteroids inhibit bone healing in a rabbit ulnar osteotomy model

Ruth V Waters¹, Seth C. Gamradt², Peter Asnis², Brian H. Vickery¹, Zafrira Avnur¹, Esther Hill¹ and Mathias Bostrom²

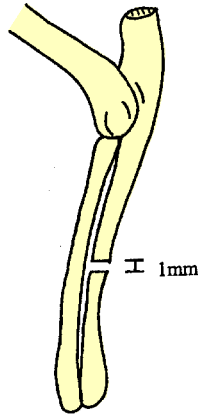
¹Roche Bioscience, Palo Alto, CA, ²The Hospital for Special Surgery, 535 East 70th Street, New York, NY 10021, USA. Tel +1 212 606 1674. E-mail: Bostromm@hss.edu. Correspondence: Dr. Mathias P.G. Bostrom
Submitted 99-05-03. Accepted 00-02-03

ABSTRACT – Prolonged systemic administration of corticosteroids causes osteoporosis and increased risk of fracture. Despite this well documented side effect of systemic corticosteroids, the effect of these compounds on fracture healing is not well defined. The goal of this study was to test the hypothesis that systemic corticosteroid therapy adversely affects fracture healing in a rabbit ulnar osteotomy model. Non-critical sized (1 mm) defects were created bilaterally in 18 adult female New Zealand White rabbits. Starting 2 months before operative intervention and continuing for 6 weeks during healing of the osteotomies, a subcutaneous dose of either sterile saline or prednisone (0.15 mg/kg) was administered daily. Serial radiographs of the forelimb were taken immediately post-operatively and weekly beginning the second week post-operatively. After killing at 6 weeks, only 3 of 20 limbs from animals treated with prednisone achieved radiographic union while 13 of 16 control limbs achieved union. The radiographic density of bone in the defect as well as callus size were greater in the control limbs than in the limbs from prednisone-treated animals. DEXA confirmed that the bone mineral content was lower in the ulnae of prednisone-treated rabbits both within the defect and in adjacent ulnar bone. Mechanical data indicated that osteotomies from rabbits chronically treated with prednisone were weaker than in controls. In this rabbit ulnar osteotomy model, chronic prednisone treatment clearly inhibited bone healing.

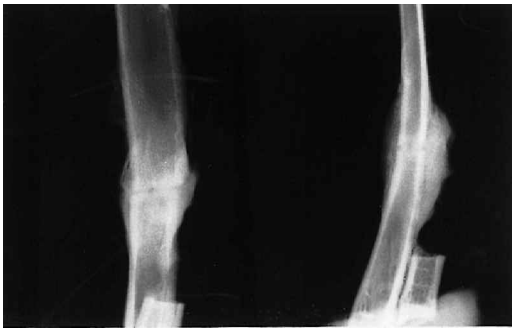
rabbits with closed femur fractures. Cortisone (25 mg/kg/day) was administered 3 days before fracture and continued until sacrifice. Cortisone-treated rabbits had less callus formation than controls. Sissons and Hadfield (1951) studied the effect of cortisone treatment (10 mg/kg/day) on closed tibial fractures in rabbits. After 21 days of treatment, control fractures showed complete union. In contrast, the fractures in cortisone-treated rabbits failed to unite. Analysis of the fracture sites showed that all histological processes of repair are retarded in cortisone-treated rabbits.

Several investigators have studied the effects of corticosteroids on fracture healing in other species. Key et al. (1952) studied the effect of cortisone (8–16 mg/kg/day) on the healing of closed humerus fractures in rats. In contrast to the previous studies, they observed no delay in fracture healing and no change in the microscopic appearance of the process of fracture healing in cortisone-treated rats. Weiss and Ickowicz (1964) created an operative fracture in rats and evaluated the effect of cortisone (20 mg/kg/day) on fracture healing. They found no significant difference in radiological and histological parameters, and no difference in the breaking strength of the healing callus. However, other investigators have reported harmful effects of cortisone on fracture healing in the rat (Duthie and Barker 1955, Storey 1960, Wiancko and Kowalewski 1961). Weiss and Ickowicz (1964) suggested that cortisone inhibits endochondral, but not membranous ossification, and thus the inhibitory effect of cortisone depends on the amount of cartilage in the callus. Since Key et

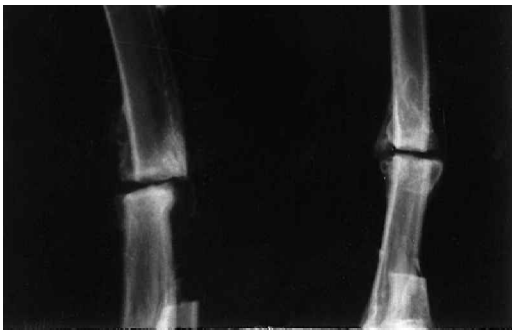The effect of corticosteroids on fracture healing is not well defined. Blunt et al. (1950) studied the effects of corticosteroids on fracture healing in



A. The location of the ulnar osteotomy.



B. Anteroposterior and lateral radiographs showing union of the ulna 6 weeks after osteotomy in a rabbit treated with saline.



C. Anteroposterior and lateral radiographs showing non-union of the ulna 6 weeks after osteotomy in a rabbit treated with prednisone.

al. (1952) (intramedullary pin placement) and Weiss and Ickowicz (operative fracture with scissors) used minimal trauma, there was greater fracture stability, and consequently less cartilage was formed. Finally, rats may not be a good species in which to study the effects of glucocorticoid, since they do not consistently respond to such treatment with bone loss and have a different endogenous

corticosteroid than the human and rabbit (Storey 1960).

In summary, the effect of cortisone on fracture healing depends partly on the species and the type of fracture being studied. In addition, the effect of corticosteroids on bone is dose-dependent (Jee et al. 1970). The studies reviewed above utilized supra-therapeutic doses of corticosteroids and thus their clinical relevance must be questioned.

The goal of this study was to test the hypothesis that systemic administration of clinically relevant doses of corticosteroids decreases the rate of fracture healing in a rabbit osteotomy model.

Animals and methods

Experimental model

Animals. 18 adult female New Zealand White rabbits weighing 3.5 kg were used in the experiment. The rabbits were caged individually and maintained on rabbit chow (Purina, St. Louis, MO) and water ad libitum. Unrestricted weight bearing and activity were permitted.

Operative model. The non-critical ulnar defect model is a modification of the segmental ulnar defect model used extensively in our laboratory to study augmentation of fracture healing (Bostrom et al. 1996) (Figure). Under general anesthesia with endotracheal intubation, standardized osteotomies of a noncritical size (1 mm) were created in each ulna approximately 4.0 cm distal to the tip of the olecranon. To expose of the ulna, a 1.5 cm incision over the subcutaneous border of the ulna was made. The osteotomy was created with a small, low-speed, oscillating saw (Stryker Osteonics, Allendale, NJ). Continuous irrigation of the osteotomy site with normal saline prevented thermal damage. The periosteum was not stripped proximal or distal to the osteotomy site. The defect was then irrigated with 0.9% NaCl. No internal or external fixation was necessary since the adjacent radius serves as an internal splint and allows weight bearing of the extremity. After adequate hemostasis is obtained, the wounds were closed in layers. The forelimbs were splinted for 4 days postoperatively.

Experimental design. 18 rabbits were divided into 2 groups: vehicle control group (n 8) and

prednisone-treated group (n 10). Subcutaneous injection of either sterile normal saline (control) or prednisone (0.15 mg/kg) (Schering-Plough Animal Health, Kenilworth, NJ) was administered daily starting 2 months prior to the operative intervention. The subcutaneous injections continued for 6 weeks after creation of the osteotomy, at which time the animals were killed. In this model, osteotomies are known to heal at six weeks in vehicle-treated animals. The dose of prednisone used has been shown to cause bone loss in rabbits (Vickery et al. 1997), which is very similar to iatrogenic osteoporosis, caused by corticosteroids in humans (Waters et al. 1995).

Analyses

Radiographs. All rabbits were evaluated with standard radiographs. Serial radiographs of the forelimbs of prone sedated rabbits were taken weekly starting in the second postoperative week. For calibration, an aluminum phantom step wedge standard (Department of Biomechanics, Hospital for Special Surgery, New York, NY) with known density values was included in each radiograph. Radiographs were transilluminated and photographed with a DCS 420 digital camera (Nikon, Melville, NY) and images were transferred to an IBM compatible computer (Gateway, N. Sioux City, SD). The average radiographic density in the area of the osteotomy was quantified, using an image analysis software package (Sigma Scan Pro, Jandel Scientific, San Rafael, CA). In addition, the density of the ulnae proximal and distal to the osteotomy was determined.

The osteotomy was considered united when there was radiographic evidence of osseous continuity of the ulna across more than 25% of the cross-sectional diameter of the osteotomy. The number of united osteotomies was recorded for each group.

After sacrifice, all soft tissues were dissected from the forelimb. Anteroposterior and lateral high resolution faxitron radiographs were taken of both limbs. Dual-view radiographs allowed for the analysis of fracture callus dimension and size. Specific parameters measured on radiographs included ulnar diameter at the osteotomy site, hard callus diameter, and soft callus diameter. The hard

callus was defined as the part of the callus nearest the ulna with a greater radiographic density than the less dense peripheral soft callus. With those measurements, the following data were calculated: the fracture cross-sectional area and the total callus, soft callus, and hard callus cross-sectional areas.

In addition to standard radiographs, the bone mineral density of each limb was also obtained using dual energy x-ray absorptiometry (DEXA) (regional high resolution scan parameters: 140/100 kVP, 4.0 mA, 149 sec, 60 Hz, 159 samples/line) (Hologic QDR 4500, Bedford, MA) prior to mechanical testing.

Mechanical testing. Epoxy was used to fix the proximal and distal ends of the forelimbs in square tapered molds, with the molds oriented normal to the long axis of the bones. Using an oscillating saw, a cut was made proximal to the distal radio-carpal joint and distal to the olecranon approximately seven-eighths of the way through the radius at the level of the potting material. The radius was then removed using a rongeur to facilitate testing of the isolated ulna. Care was taken at all times to insure that the bones were moist during processing.

Mechanical analyses were performed at room temperature using a Burstein torsion tester (Burstein and Frankel 1971) (Department of Biomechanics, Hospital for Special Surgery, New York, NY) equipped with a 200 inch-ounce Leblow torque cell (Eaton Corporation, Troy, MI). Specimens were torqued to failure in external rotation while acquiring torque and angular displacement at 5 Khz with a digital oscilloscope (Tektronics, Beaverton, OR). The following data were collected: maximum torque, maximum angular deformation, stiffness, and energy absorption to failure. Appropriate data were normalized to the exposed length of bone.

Statistics. Radiographic union data were compared, using the Fisher exact test. Radiographic callus dimension data were compared using analysis of variance for parametric data (Tukey-Kramer multiple comparisons test). Mechanical data were also analyzed, using analysis of variance for parametric data. The data on the stages of mechanical healing were analyzed with nonparametric analysis of variance (Kruskal-Wallis nonparametric

Table 1. Radiographic union of ulnar osteotomies

| | Control | Prednisone-treated |
|-----------|---------|--------------------|
| Union | 13 | 3 |
| Non-union | 3 | 17 |

Table 2. Radiographic intensity (normalized radiographic units) at the osteotomy site. Mean (SD)

| | Control | Prednisone-treated | P-value |
|-----------|-----------|--------------------|---------|
| Intensity | 3.9 (4.8) | 0.7 (1.3) | < 0.001 |

Table 3. DEXA analysis of bone mineral (mg/cm²) at the osteotomy site and ulna diaphysis. Mean (SD)

| Ulna site | Control | Prednisone-treated | P-value |
|-----------|-------------|--------------------|---------|
| Defect | 0.28 (0.04) | 0.21 (0.03) | < 0.001 |
| Diaphysis | 0.27 (0.03) | 0.22 (0.03) | < 0.001 |

analysis of variance with Dunn's multiple comparisons test).

Results

Radiographic bone union was achieved in only 3 of 20 limbs in rabbits treated with prednisone. In contrast, 13 of 16 control limbs achieved radiographic union at 6 weeks (Table 1) (Fisher's exact test $p < 0.001$). Typical radiographs at 6 weeks after osteotomy are shown in the Figure.

The radiographic density of bone at the osteotomy site, determined by radiographic image analy-

sis, was greater in the control limbs in comparison to the prednisone treated limbs (Table 2) ($p < 0.001$). In addition, the outer diameter of the fracture calluses was larger in control rabbits than in prednisone-treated rabbits. On lateral radiographs, the mean callus diameter was 8.9 (SD 1.3) mm in prednisone-treated ulnae and 14.3 (SD 1.8) mm in control ulnae ($p < 0.001$). On anteroposterior radiographs, the mean callus diameter was 8.6 (SD 1.3) mm in prednisone-treated ulnae and 18.1 (SD 2.1) mm in control ulnae ($p < 0.001$). DEXA analysis showed that the bone mineral density (BMD) and bone mineral content (BMC) were lower at both the osteotomy site and in adjacent native bone of prednisone-treated rabbits than in the ulnae of control rabbits (Table 3).

The mechanical data confirmed that the prednisone-treated osteotomies were weaker than the controls in torque, stiffness, and energy absorption to failure (Table 4).

Discussion

We found that chronic, systemic administration of a corticosteroid (prednisone) impaired fracture healing in rabbits in a non-critical sized ulnar defect model. Radiographic data indicated a smaller callus, less density at the osteotomy site, and a very low rate of union in the ulnae of prednisone-treated rabbits when compared to controls. DEXA analysis confirmed the radiographic findings and biomechanical studies confirmed that prednisone-treated fracture sites were significantly weaker than controls in all parameters tested. Our results are in accordance with those of two other groups who demonstrated impaired fracture-healing in rabbits treated with corticosteroids (Blunt et al.

Table 4. Biomechanical properties of ulnae of prednisone-treated and control rabbits 6 weeks after osteotomy. Mean (SD)

| | Control | Prednisone-treated | P-value |
|----------------------------|-------------|--------------------|---------|
| Number of limbs | 16 | 20 | |
| Angular displacement (rad) | 0.29 (0.98) | 0.32 (0.07) | 0.2 |
| Stiffness (N-mm/rad) | 567 (294) | 218 (102) | < 0.001 |
| Energy (N-mm × rad) | 1966 (729) | 731 (391) | 0.005 |
| Torque (N-mm) | 96 (74) | 34 (22) | < 0.001 |

1950, Sissons and Hadfield 1951). In those studies, corticosteroid administration was begun at or near the time of fracture. Our study more accurately reflects fracture healing in the setting of chronic corticosteroid administration, since rabbits were pretreated with prednisone for 2 months prior to fracture.

We conclude that prednisone-treated rabbits with a non-critical ulnar osteotomy serve as a good model for impaired fracture healing. Given the widespread use of chronic corticosteroid therapy in medicine today, the findings in this study may have significant clinical implications.

The biochemical mechanism of corticosteroid-induced osteoporosis has been well studied in humans. The mechanism of fracture healing in the setting of corticosteroid administration is less clear. However, the pathophysiology of corticosteroid-induced osteoporosis could help to explain corticosteroid effects on fracture healing. That is, similar pathophysiology is probably at work in both entities. Corticosteroid administration results in decreased osteoblast activity and thus decreased matrix synthesis (Aaron et al. 1989, Lo-Cascio et al. 1990, Lund et al. 1985). In addition, corticosteroids have been shown to affect vitamin D metabolism adversely (Cosman et al. 1994). The molecular mechanisms of corticosteroid-induced osteoporosis have also been studied.

Corticosteroids alter the transcription of genes. Corticosteroids are known to reduce the synthesis of type I collagen and osteocalcin mRNA. Type I collagen is the most abundant bone matrix protein, and osteocalcin is a highly specific marker for the osteoblast lineage (Lukert and Kream 1996). In addition, corticosteroids have also been shown to alter transcription of alkaline phosphatase, bone sialoprotein, fibronectin, β 1-integrin, and interstitial collagenase mRNAs (Lukert and Kream 1996). Corticosteroids also diminish the production and activity of growth factors that are important for fracture healing, most notably IGF-1 and TGF- β (Lane and Lukert 1998). In addition to the well documented decrease in bone formation, other factors involved in the pathophysiology of corticosteroid-induced osteoporosis may influence fracture healing. These include increased bone resorption, decreased intestinal calcium absorption, decreased secretion of sex steroids caused by ad-

renal suppression, and possibly secondary hyperparathyroidism (Lane and Lukert 1998). The abnormal bone metabolism, well documented in corticosteroid-induced osteoporosis, probably contributed to the detrimental effect of corticosteroids on fracture healing observed in our study.

Therapy for and prevention of corticosteroid-induced osteoporosis are active areas of clinical research. Currently, promising clinical results have been obtained with PTH and bisphosphonate therapy. PTH has been shown to reverse corticosteroid-induced osteoporosis in a 1-year clinical trial (Lane et al. 1998). Etidronate has been found to prevent bone loss in patients started on high-dose corticosteroids as well as bone loss in patients with established corticosteroid-induced osteoporosis (Adachi et al. 1997, Eastell et al. 1998). Other therapeutic options include hormone replacement therapy, calcitriol, intranasal calcitonin, as well as supplementation with vitamin D and calcium (Lane and Lukert 1998). It is not known whether these interventions will promote fracture healing in glucocorticoid-treated patients.

Since it has already been shown that a PTHrP analog can reverse corticosteroid-induced osteoporosis in the prednisone-treated rabbit model (Vickery et al. 1997), PTH/PTHrP and bone anabolics in general might be beneficial in fracture healing. The ulnar osteotomy model in rabbits treated with corticosteroids should prove useful in studying the pathophysiology and treatment of impaired fracture healing. Further research is underway to investigate possible pharmacologic intervention, most notably with PTHrP analogs, to reverse the detrimental effect of corticosteroids on bone loss and the delay in fracture healing.

- Aaron J E, Francis R M, Peacock M, Makins N B. Contrasting microanatomy of idiopathic and corticosteroid-induced osteoporosis. *Clin Orthop* 1989; 243: 294-305.
- Adachi J D, Bensen W G, Brown J, Hanley D, Hodsmann A, Josse R, Kendler D L, Lentle B, Olszynski W, Ste-Marie L G, Tenenhouse A, Chines A A. Intermittent etidronate therapy to prevent corticosteroid-induced osteoporosis. *N Engl J Med* 1997; 337: 382-7.
- Blunt J W, Plotz C M, Lattes R, Meyer K, Ragan C. Effect of cortisone on experimental fractures in the rabbit. *Proc Soc Exp Biol NY* 1950; 73: 678.
- Bostrom M, Lane J M, Tomin E, Browne M, Berberian W, Turek T, Smith J, Wozney J, Schildhauer T. Use of bone morphogenetic protein-2 in the rabbit ulnar nonunion model. *Clin Orthop* 1996; 327: 272-82.

- Burstein A H, Frankel V H. A standardized test for laboratory animal bone. *J Biomech* 1971; 4: 155-8.
- Cosman F, Nieves J, Herbert J, Shen V, Lindsay R. High-dose glucocorticoids in multiple sclerosis patients exert direct effects on the kidney and skeleton. *J Bone Miner Res* 1994; 9: 1097-105.
- Duthie R B, Barker A N. Histochemistry of preosseous stage of bone repair autoradiography. Effect of cortisone. *J Bone Joint Surg (Am)* 1955; 37: 691-710.
- Eastell R, Reid D M, Compston J, Cooper C, Fogelman I, Francis R M, Hosking D J, Purdie D W, Ralston S H, Reeve J, Russell R G, Stevenson J C, Torgerson D J. A UK Consensus Group on management of glucocorticoid-induced osteoporosis: an update. *J Intern Med* 1998; 244: 271-92.
- Jee W S, Park H Z, Roberts W E, Kenner G H. Corticosteroid and bone. *Am J Anat* 1970; 129: 477-9.
- Key J A, Odell R T, Taylor L W. Failure of cortisone to delay or to prevent the healing of fractures in rats. *J Bone Joint Surg (Am)* 1952; 34: 665-77.
- Lane N E, Lukert B. The science and therapy of glucocorticoid-induced bone loss. *Endocrinol Metab Clin North Am* 1998; 27: 465-83.
- Lane N E, Sanchez S, Modin G W, Genant H K, Ini E, Arnaud C D. Parathyroid hormone treatment can reverse corticosteroid-induced osteoporosis. Results of a randomized controlled clinical trial. *J Clin Invest* 1998; 102: 1627-33.
- LoCascio V, Bonucci E, Imbimbo B, Ballanti P, Adami S, Milani S, Tartarotti D, DellaRocca C. Bone loss in response to long-term glucocorticoid therapy. *Bone Miner* 1990; 8: 39-51.
- Lukert B, Kream B E. Clinical and basic aspects of glucocorticoid action in bone. In: Principles of bone biology (Eds. Bilezikian J P, Raisz L G, Rodan G A). Academic Press, New York 1996; 533-48.
- Lund B, Storm T L, Melsen F, Mosekilde L, Andersen R B, Egmos C, Sorensen O H. Bone mineral loss, bone histomorphometry and vitamin D metabolism in patients with rheumatoid arthritis on long-term glucocorticoid treatment. *Clin Rheumatol* 1985; 4: 143-9.
- Sissons H S, Hadfield G H. The influence of cortisone on the repair of experimental fractures in the rabbit. *Br J Surg* 1951; 39: 172-8.
- Storey E. The effect of cortisone on normal and fractured bone in the rat. *Aust NZ J Surg* 1960; 30: 37-44.
- Vickery B H, Avnur Z, McRae G I, Hill E, Krstenansky J L. Bone formation may be uncoupled from resorption as demonstrated by a new class of h PTHrP (1-34) analogs in both rapid and slow models of bone turnover. In: Anabolic treatments for osteoporosis (Ed. Whitfield J F). CRC Press, New York 1997: 152-73.
- Waters R V, Bergstrom K, Briones W, Vickery B H, Kimmel D B. Prednisone causes bone loss in rabbits. The Endocrine Society Program and Abstracts, 77th Annual Meeting, June 14-17, 1995. Washington DC. Abstract P3-510, p 596.
- Weiss R, Ickowicz M. The influence of cortisone on the healing of experimental fractures in rats. *Acta Anat* 1964; 59: 163-79.
- Wiancko K O, Kowalewski K. Strength of callus in fractured humerus of rats treated by anti-anabolic and anabolic compounds. *Acta Endocrinol* 1961; 36: 310-8.