

Macrophage-osteoclast differentiation and bone resorption in osteoarthrotic subchondral acetabular cysts

Afsie Sabokbar¹, Ross Crawford¹, David W Murray¹ and Nicholas A Athanasou^{1,2}

¹Nuffield Department of Orthopaedic Surgery and ²Department of Pathology, Nuffield Orthopaedic Centre, Oxford OX3 7LD, U.K. Tel + 44 1865 227–619. Fax –354. Correspondence: Dr. N.A. Athanasou, Department of Pathology
Submitted 99-07-09. Accepted 00-01-12

ABSTRACT – A macrophage infiltrate is commonly found in enlarging subchondral cysts in osteoarthritis (OA) and the surrounding bone. To determine whether osteoclast differentiation by these cells contributes to the increase in the number of osteoclasts and bone resorption that accompanies OA cyst enlargement, we isolated macrophages from the wall of OA cysts and co-cultured them with osteoblast-like UMR106 cells in the presence or absence of 1,25(OH)₂D₃ and M-CSF.

After 14 days of incubation, co-cultures of UMR106 cells and cyst-derived macrophages showed evidence of osteoclast differentiation by expression of TRAP, VNR and formation of numerous lacunar pits. We found that, unlike osteoclast precursors in monocyte and other tissue macrophage populations, the addition of M-CSF to medium is not required for osteoclast differentiation.

Our findings suggest that macrophage-osteoclast differentiation is one means whereby the osteolysis associated with the enlargement of OA cysts could be effected.

■

Subchondral bone cysts are commonly found in osteoarthritis (OA) and other joint conditions (Sokoloff 1976). They are usually present over weight-bearing areas of the joint, often where extensive erosive changes are seen in the articular surface. The pathogenesis of OA cysts is not certain. Most observers believe that they form by transmission of intra-articular pressure and synovial fluid into the subchondral marrow through a microscopic defect in the overlying articular cartilage and bone plate (Landells 1953, Sokoloff 1976, Milgram 1983), or by myxoid degeneration

and fibrosis in areas of altered subchondral bone marrow (Ondrouch 1963).

Subchondral OA cysts may contain mucinous fluid, fibromyxoid or fibrous tissue (Sokoloff 1976, Milgram 1983). The fibrous wall of the cyst is of variable thickness and surrounded by subchondral bone trabeculae, which often show evidence of osteoblastic and osteoclastic remodelling activity. A chronic inflammatory infiltrate, composed largely of macrophages, is commonly found within both the wall and the lumen of OA cysts. Inflammatory cells are also present in the bone marrow surrounding OA cysts. It has been shown that synovial macrophages isolated from joints affected by rheumatoid arthritis (RA) are capable of osteoclast formation when co-cultured with osteoblastic cells in the presence of 1,25 dihydroxy-vitamin D₃ [1,25(OH)₂D₃] and human macrophage-colony stimulating factor (M-CSF) (Fujikawa et al. 1996b). It has also been shown that foreign body wear-particle-associated macrophages, isolated from the pseudomembrane surrounding a loose prosthetic implant, are similarly capable of osteoclast formation and that M-CSF is produced by cells in the arthroplasty membrane (Sabokbar et al. 1997). Aseptic loosening is associated with periprosthetic osteolysis and it is known that cytokines which stimulate osteoclastic bone resorption, including IL-1, IL-6 and TNF, are produced in the arthroplasty pseudomembrane (Jiranek et al. 1993, Kim et al. 1993). A similar cytokine profile has been found in the fibrous wall of subchondral OA cysts (Jiranek et al. 1997).

As osteoclastic resorption is seen in the subchondral bone surrounding OA cysts, we investigated whether macrophage-osteoclast differentiation may play a role in the osteolysis associated with the enlargement of subchondral OA cysts.

Material and methods

For all incubations, alpha minimum essential medium (MEM) (Gibco, U.K.) was supplemented with 100 IU/mL penicillin, 10 mg/mL streptomycin, 10 mM l-glutamine (Gibco, UK), and 10% foetal calf serum (FCS) (Gibco, UK). $1,25(\text{OH})_2\text{D}_3$ was purchased from Solvay Duphar (The Netherlands) and dissolved in absolute alcohol and stored at -20°C . The cloned hormone-resorptive rat osteosarcoma cell line UMR106, which has an osteoblast-like phenotype (Partridge et al. 1981), was kindly provided by Professor T.J. Martin (Melbourne, Australia). Collagenase Type I and 0.25% trypsin solution were purchased from Sigma Chemicals (Dorset, U.K.). All incubations were carried out at 37°C in 5% CO_2 .

Isolation of cells from subchondral OA cysts

We collected the wall of 6 subchondral cysts of the acetabulum from 4 male and 2 female patients (age-range 48–72 years) undergoing hip replacement for OA. The tissue specimens were washed thoroughly with phosphate-buffered saline before being cut into small fragments and digested in MEM containing 1 mg/mL collagenase Type I for 30 minutes at 37°C ; this was followed by a further 1 hour incubation in 0.25% trypsin. The digested tissue was filtered with a $70\ \mu\text{m}$ cell strainer (Falcon, UK) and the filtrate centrifuged at 800 g for 10 minutes. The cell pellet was resuspended in MEM/FCS and the number of leukocytes counted in a haemocytometer following lysis of red blood cells using a 5% (v/v) acetic acid solution.

Preparation of UMR106-macrophage cocultures on glass coverslips and dentine slices

24 hours prior to the isolation of cells from the digested OA cysts, 2×10^4 UMR106 cells were add-

ed to 7 mm wells of a tissue culture plate containing dentine slices (4 mm) and coverslips (6 mm diameter). The cell suspension obtained from surgical specimens was added to each well (1×10^5 cell/well) and incubated for 2 hours, after which time all dentine slices and coverslips were removed from the wells, washed vigorously in MEM/FCS to remove non-adherent cells, and then placed in 16 mm wells of a tissue culture plate containing 1 ml of MEM/FCS. All cultures were maintained in the presence of $1,25(\text{OH})_2\text{D}_3$ (10^{-7} M) and dexamethasone (10^{-8} M), for 1, 7, and 14 days. To determine the cellular and humoral requirements for osteoclast generation, OA cyst macrophages were cultured: (i) \pm UMR106 cells; (ii) \pm $1,25(\text{OH})_2\text{D}_3$ (10^{-7} M) and (iii) \pm a mouse anti-human M-CSF neutralising antibody ($10\ \mu\text{g}/\text{mL}$) (R & D Systems, U.K.).

Histology of OA cysts

Specimens of the subchondral cyst and surrounding bone were examined histologically. Following routine processing, $5\ \mu\text{m}$ paraffin-embedded sections were stained with haematoxylin-eosin and with an indirect immunoperoxidase technique with the monoclonal anti-CD68 antibody KP-1 (Athanasou and Quinn 1990, Athanasou et al. 1991); this antigen is expressed by macrophages and osteoclasts.

Histochemical and immunohistochemical characterisation of cultured cells

After 24 hours and 7 days of incubation, cell cultures on coverslips were fixed in acetone and characterised histochemically for the expression of tartrate-resistant acid phosphatase (TRAP), an osteoclast-associated enzyme marker (Minkin 1982), using a commercially available kit (Sigma, Cat No 386A, U.K.). Expression of the macrophage and osteoclast-specific cell surface antigens, CD11b and CD51 (vitronectin receptor (VNR)), respectively (Horton et al. 1985, Athanasou and Quinn 1990), was also sought by immunohistochemistry using an indirect immunoperoxidase technique. All histochemical and immunohistochemical preparations were counterstained routinely with haematoxylin.

Functional evidence of osteoclast differentiation: detection of lacunar resorption by scanning electron microscopy (SEM)

We sought evidence of lacunar resorption following culture of OA cyst-derived cells (\pm UMR106 cells) on dentine slices. The latter provides a smooth-surface mineralised substrate on which resorption lacunae can readily be identified by scanning electron microscopy. Dentine slices were removed from the culture wells after 24 hours and 14 days of incubation. Cells covering the dentine slices were removed with trypsin and immersion in 0.25M ammonium hydroxide overnight. Dentine slices were then passed through graded alcohols to absolute, then allowed to air-dry before being sputter-coated with gold and examined in a Philips SEM 505 scanning electron microscope. The extent of lacunar resorption was determined by counting the number of resorption pits on each slice. The mean number of resorption pits on each dentine slice was also calculated.

Statistics

We set up 3 or 4 dentine slices for each OA cyst specimen and each treatment studied. Results are expressed as mean number of lacunar resorption pits and statistical analyses were performed, using the ANOVA test.

Results

Histology of OA cysts (Figure 1)

Specimens of the femoral head from all patients studied showed marked erosion of the articular surface, osteophyte formation and subchondral bone changes, in keeping with the clinical and radiographic diagnosis of primary OA. The acetabular subchondral cysts examined were 1.2–2.9 cm in diameter. The cyst wall from which cells were isolated was composed of fibrous tissue (less than 2.5 mm maximum). Mucinous fluid and/or fibromyxoid material was noted in the lumen of the cysts.

Histologically, numerous scattered chronic inflammatory cells were present in the cyst wall and cyst lumen. Many of these cells stained positive for CD68. CD68 positive macrophages were also present in the oedematous and fibrotic marrow

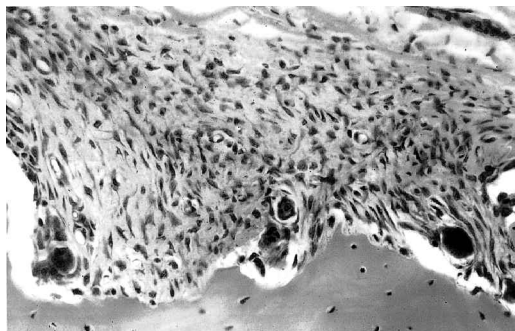


Figure 1. Photomicrograph showing part of the fibrous wall of a subchondral cyst and surrounding bone in OA. Note the presence of inflammatory cells in the cyst wall and the evidence of osteoclastic bone resorption, $\times 200$.

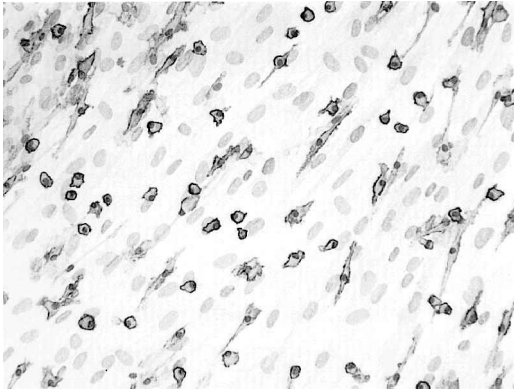
surrounding the cysts. Subchondral bone trabeculae around the cyst wall were often thickened and showed remodelling changes associated with the presence of active osteoblasts and resorbing osteoclasts.

Cytochemical and immunophenotypic characterisation of cells isolated from OA cysts (Figure 2)

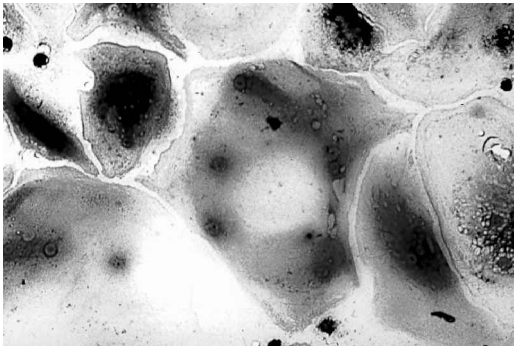
In 3 of the 6 cases, cytochemical staining of 24-hour cultures of cells isolated from the OA cyst wall on glass coverslips (incubated both in the presence or absence of UMR106 cells) showed no staining of the osteoclast markers TRAP and VNR; cells were positive for the macrophage marker CD11b. In the remaining 3 cases, 24-hour cultures contained, in addition to numerous CD11b positive cells, a few TRAP⁺ mononuclear and multinucleated cells, some of which were found to be attached to fragments of bone. We also saw VNR⁺ cells in these 3 cases.

We observed numerous CD11b positive mononuclear cells in all 7-day cultures of cells isolated from subchondral cysts, incubated in both the presence or absence of UMR106 cells. In 7-day co-cultures of cyst-derived macrophages and UMR106 cells, there were small and large clusters of TRAP⁺ mononuclear and multinucleated cells. Large VNR⁺ cells were also found in co-cultures of UMR106 cells and cyst-derived macrophages incubated in the presence of $1,25(\text{OH})_2\text{D}_3$. The number of large TRAP⁺ cell clusters containing multinucleated cells was 15–32 in these cases. In the absence of UMR106 cells, no TRAP⁺ cell clusters were seen and very few TRAP⁺ or VNR⁺

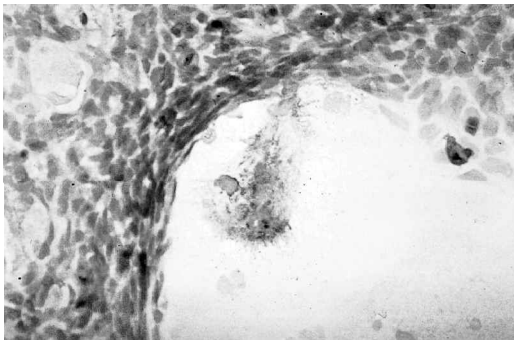
Figure 2. Co-cultures of OA cyst-derived macrophages and UMR106 cells incubated in the presence of $1,25(\text{OH})_2\text{D}_3$ and dexamethasone on glass coverslips. All counterstained with haematoxylin.



A. Numerous CD11b positive mononuclear cells after 24 hours of culture, $\times 200$.



B. TRAP⁺ cells in 7-day co-cultures, $\times 630$.



C. A large multinucleated VNR⁺ cell in 7-day co-cultures, $\times 400$.

cells were found in 7-day cultures, either in the presence or absence of $1,25(\text{OH})_2\text{D}_3$.

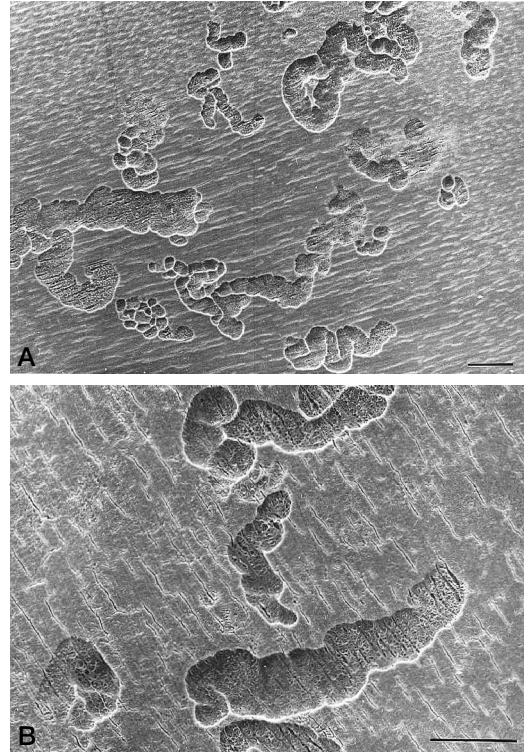


Figure 3. 14-day co-cultures of OA cyst-derived macrophages and UMR106 cells incubated in the presence of $1,25(\text{OH})_2\text{D}_3$ and dexamethasone on dentine slices. Cultured cells have been removed, revealing the formation of numerous well-defined lacunar resorption pits. Figure 3B shows a high power view of several resorption pits (black bar = $50\ \mu\text{m}$).

Functional characterisation of OA cyst-derived macrophages: cellular and humoral requirements for osteoclast differentiation (Figure 3, Table)

After 24 hours of incubation on dentine slices of cells isolated from OA cysts (both in the presence or absence of UMR106 cells), we saw no lacunar resorption in 2 of the 6 cases studied. In the remaining 4 cases, a few isolated, small resorption pits were noted. These few pits were seen only in those cases found to contain a few TRAP⁺ and VNR⁺ cells in parallel 24-hour cultures on glass coverslips: such findings indicated that this lacunar resorption was probably due to the presence of a few contaminating osteoclasts present in the cell suspension isolated from the cyst wall.

In 14-day co-cultures of OA cyst-derived macrophages and UMR106 cells, incubated in the

Number of lacunar resorption pits formed on dentine slices after 1 and 14 days of incubation (\pm UMR106 and $1,25(\text{OH})_2\text{D}_3$) of OA cyst-derived macrophages. 6 cases were studied and the mean number of resorption pits for each case is shown in parentheses

Case	Day 1	Day 14	\pm D ₃ or UMR106
1	6,5,4 (5)	48,38,50 (45)	With UMR & D ₃
	7,3,2 (5)	8,11,6 (8)	Without UMR
	4,2,2 (3)	8,6,7 (6)	No D ₃ + UMR
2	4,0,4 (3)	26,42,38 (35)	With UMR & D ₃
	3,0,4 (2)	8,10,9 (9)	Without UMR
	0,2,1 (1)	10,11,7 (9)	No D ₃ + UMR
3	16,25,8,16 (16)	92,75,85,91 (86)	With UMR & D ₃
	8,11,18,20 (14)	43,23,13,18 (24)	Without UMR
	18,10,7 (11)	24,18,11 (18)	No D ₃ + UMR
4	0	41,21,39 (34)	With UMR & D ₃
	0	0,8,0 (3)	Without UMR
	0	0,4,0 (1)	No D ₃ + UMR
5	0	35,14,28 (26)	With UMR & D ₃
	0	0	Without UMR
	0	0	No D ₃ + UMR
6	2,2,2 (2)	31,19,25 (24)	With UMR & D ₃
	0	1,1,0	Without UMR
	0	0,7,0	No D ₃ + UMR

presence of $1,25(\text{OH})_2\text{D}_3$, we found extensive lacunar resorption pit formation on all dentine slices in the 6 cases studied. Under these conditions, the mean number of resorption pits was 42 (24–86) per dentine slice; this was higher ($p = 0.003$) than the mean number of 4.3 resorption pits in 24-hour co-cultures. As in 24-hour cultures, a few lacunar resorption pits were detected on dentine slices when OA cyst-derived macrophages were cultured in the absence of UMR106 cells or $1,25(\text{OH})_2\text{D}_3$ for 14 days.

To determine whether M-CSF, which is known to be required for human monocyte and RA synovial macrophage-osteoclast differentiation, also plays a role in OA cyst macrophage-osteoclast formation, we added a neutralising antibody to human M-CSF (10 $\mu\text{g}/\text{mL}$) to cultures of macrophages isolated from cases 5 and 6. In both these cases there was marked inhibition of TRAP and VNR expression (at day 7) and lacunar resorption (at day 14). The mean number of lacunar resorption pits formed in the presence or absence of anti-human M-CSF was 4 and 25 pits per dentine slice, respectively.

Discussion

We have shown that macrophages isolated from the wall of subchondral OA cysts can differentiate into osteoclastic cells capable of lacunar resorption in vitro. For this to occur, the presence of osteoblastic cells and $1,25(\text{OH})_2\text{D}_3$ is essential. Our findings suggest that macrophages may provide the precursor population from which these osteoclasts develop and that macrophage-osteoclast differentiation is one means whereby osteolysis occurs in the subchondral bone surrounding OA cysts.

OA cyst macrophages did not require the addition of M-CSF for macrophage-osteoclast differentiation in vitro. Osteoclast formation from OA cyst macrophages thus differed from that of human monocytes and inflammatory macrophages isolated from the RA synovium which, in addition to $1,25(\text{OH})_2\text{D}_3$ and osteoblastic cells, requires exogenous M-CSF for osteoclast formation (Fujikawa et al. 1996a, b). Another human macrophage population from which osteoclasts have been formed in the absence of M-CSF is that of inflammatory (foreign body wear particle-associated) macrophages isolated from the arthroplasty pseudomembrane surrounding failed prosthetic implants. As with arthroplasty-derived macrophages, we found that osteoclast formation in OA cyst-derived macrophage-UMR106 co-cultures, was inhibited by the addition of an anti-M-CSF antibody. This was evidenced by reduced formation of TRAP⁺ and VNR⁺ multinucleated cells and marked inhibition of lacunar resorption. It implies that M-CSF is produced endogenously by the cells isolated from subchondral cysts and that M-CSF plays a role in osteoclast differentiation. Resorption was not abolished by the addition of an antibody to M-CSF, suggesting that other cytokines and growth factors, released by OA cyst-derived cells, are capable of promoting the process of macrophage-osteoclast differentiation.

Although our findings do not shed light on the manner in which subchondral cysts are initiated in OA, they may explain how they enlarge. Similarities have been noted between the arthroplasty pseudomembrane surrounding a failed implant and subchondral pseudocysts. Both tissues are composed of fibrous tissue which is often an in-

flammatory infiltrate containing numerous macrophages. Jiranek et al. (1997) showed that the wall of OA subchondral cysts and the arthroplasty membrane contain similar levels of cytokines such as IL-1, TNF and IL-6; these factors are known to stimulate osteoclast formation and bone resorbing activity (Suda et al. 1992). We found that the in vitro requirements for macrophage-osteoclast differentiation are similar in both OA subchondral cysts and the arthroplasty membrane, MCSF not being required for the formation of osteoclasts. Cytokine stimulation of macrophage-osteoclast differentiation may thus play a role in the osteolysis associated with enlargement of subchondral cysts as well as arthroplasty loosening.

Compressive forces have been reported to exceed 1,000 mm Hg in the hip joint (Termansen et al. 1981). This high pressure could act not only to force synovial fluid into a subchondral cyst (Crawford et al. 1998), but also to disturb the subchondral bone circulation, leading to ischaemia and fibrosis in bone and bone marrow around OA cysts. It has been shown that the intracapsular pressure is higher in hip joints containing loose prosthetic components; this increased pressure may pump wear particles along the bone-implant interface where osteolysis occurs (Robertsson et al. 1997). Short periods of oscillating fluid pressure have also been shown to promote osteolysis at a bone-titanium interface (van der Vis et al. 1998a). In consequence, it has been proposed that an increase in fluid pressure around a migrating prosthesis could contribute to the osteolysis of implant-loosening (van der Vis et al. 1998b).

Pathological changes associated with increased pressure evoke a macrophage response and macrophages are commonly found in the subchondral bone marrow around OA cysts. Our results indicate that these macrophages can contribute to the osteoclastic resorption of subchondral bone surrounding OA cysts by macrophage-osteoclast differentiation. As macrophages are not uncommonly found in OA in areas of oedematous, degenerate or fibrotic subchondral marrow unrelated to cysts, it is possible that macrophage-osteoclast differentiation may contribute more generally to the process of OA subchondral bone remodelling.

The authors thank Dr. David Ferguson for help with processing of the scanning electron micrographs. This study was supported by the Wellcome Trust.

- Athanasou N A, Quinn J. Immunophenotypic differences between osteoclasts and macrophage polykaryons: immunohistological distinctions and implications for osteoclast ontogeny and function. *J Clin Pathol* 1990; 43: 997-1004.
- Athanasou N A, Puddle B, Woods C G. Use of monoclonal antibodies to recognise osteoclasts in routinely processed bone biopsies. *J Clin Pathol* 1991; 44 (8): 664-6.
- Crawford R, Sabokbar A, Wulke A, Murray D W, Athanasou N A. Expansion of an osteoarthritic cyst associated with wear debris. *J Bone Joint Surg (Br)* 1998; 80: 990-3.
- Fujikawa Y, Quinn J, Sabokbar A, McGee JO'D, Athanasou N A. The human mononuclear osteoclast precursor circulates in the monocyte fraction. *Endocrinology* 1996a; 139: 4058-60.
- Fujikawa Y, Sabokbar A, Neale S D, Athanasou N A. Human osteoclast formation and bone resorption by monocytes and synovial macrophages in rheumatoid arthritis. *Ann Rheum Dis* 1996b; 55: 816-22.
- Horton M A, Lewis D, McNulty K, Pringle J A S, Chambers T J. Monoclonal antibodies to osteoclastomas (giant cell bone tumours): definition of osteoclast specific cellular antigens. *Cancer Res* 1985; 45: 5663-9.
- Jiranek W A, Machado M, Jasty M et al. Production of cytokines around loosened cemented acetabular components. *J Bone Joint Surg (Am)* 1993; 75: 863-79.
- Jiranek W A, Dalury D F, Qui J Y, Cardea J. Bone resorption in osteoarthritic cysts demonstrate cytokine profile as osteolytic lesions around joint implants. *Trans Orthop Res Proceedings* 1997; 159: 27.
- Kim K J, Rubash H E, Wilson S C, D'Antonio J A, McClain E J. A histologic and biochemical comparison of the interface tissues in cementless and cemented hip prostheses. *Clin Orthop* 1993; 287: 142-52.
- Landells J W. The bone cysts of osteoarthritis. *J Bone Joint Surg (Br)* 1953; 35: 643-9.
- Milgram J W. Morphologic alterations in the subchondral bone in advanced degenerative arthritis. *Clin Orthop* 1983; 173: 293-312.
- Minkin C. Bone acid phosphatase: Tartrate-resistant acid phosphatase as a marker of osteoclast function. *Calcif Tissue Int* 1982; 34: 285-90.
- Ondrouch A S. Cyst formation in osteoarthritis. *J Bone Joint Surg (Br)* 1963; 45: 755-60.
- Partridge N, Alcorn D, Michelangeli V, Kemp E, Ryan G, Martin T J. Functional properties of hormonal responsive cultured normal and malignant rat osteoblastic cells. *Endocrinology* 1981; 116: 213-9.
- Robertsson O, Wingstrand H, Kesteris U, Jonsson K, Önerfält R. Intracapsular pressure and loosening of hip prostheses. Preoperative measurements in 18 hips. *Acta Orthop Scand* 1997; 68: 231-4.

- Sabokbar A, Fujikawa Y, Neale S, Murray D, Athanasou N A. Human arthroplasty-derived macrophages differentiate into osteoclastic bone-resorbing cells. *Ann Rheum Dis* 1997; 56: 414-20.
- Sokoloff L. The general pathology of osteoarthritis. In: *Symposium on osteoarthritis*. Mosby CV, St. Louis 1976: 23-33.
- Suda T, Takahashi N, Martin T J. Modulation of osteoclast differentiation. *Endocrine Rev* 1992; 13: 66-80.
- Termansen N B, Teglbjaerg P S, Sorensen K H. Primary osteoarthritis of the hip: interrelationship between intraosseous pressure, X-ray changes, clinical severity and bone density. *Acta Orthop Scand* 1981; 52: 215-22.
- van der Vis H M, Aspenberg P, de Kleine R, Tigchelaar W, van Noorden C J F. Short periods of oscillating fluid pressure directed at a titanium-bone interface in rabbits lead to bone lysis. *Acta Orthop Scand* 1998a; 69: 5-10.
- van der Vis H M, Aspenberg P, Marti R K, Tigchelaar W, van Noorden C J F. Fluid pressure causes bone resorption in a rabbit model of prosthetic loosening. *Clin Orthop* 1998b; 350: 201-8.