

Degeneration of the acetabular cartilage in osteonecrosis of the femoral head

Histopathologic examination of 15 hips

Gun-Il Im, Do-Young Kim, Joo-Ho Shin, Won-Ho Cho and Chang-Ju Lee

Department of Orthopaedics, Hallym University Hospital, 153 Kyo-Dong, Chunchon 200-060, Korea.
Tel +82 361-252 9970. Fax -256-4414. E-mail:gunil@www.hallym.or.kr
Submitted 99-02-18. Accepted 99-07-13

ABSTRACT — Acetabular cartilage with subchondral bone was taken from the superior dome from 15 hips of 13 patients undergoing total hip arthroplasty due to osteonecrosis of the femoral head. The mean age of the patients was 40 years. There were 10 hips ARCO stage IIIA, and 5 hips stage IIIB. 3 of the cases were mild, 12 moderate, and 1 had severe arthrosis. The degree of collapse of the femoral head was significantly related to the degeneration of the acetabular cartilage on histological examination. Our observations support the view that patients with an ARCO Stage III hip do not benefit from head-preserving procedures. They may also explain why bipolar prosthesis gives poorer results than total hip arthroplasty, in cases of osteonecrosis of the femoral head.

Core decompression, transtrochanteric rotational osteotomy, and vascularized graft are head-preserving operations which give acceptable long-term results in Association Research Circulation Osseous (ARCO) stages I or II hips (Learmonth et al. 1990, Sugano et al. 1992, Fairbank et al. 1994, Urbaniak et al. 1995). However, in ARCO III hips, the results are worse (Mont 1995). One explanation of this could be degeneration of the acetabular cartilage also in hips without radiographic joint space narrowing.

Patients and methods

We obtained acetabular cartilage from 15 hips of 13 patients (mean age 40 (23–59) years, 11 men) with osteonecrosis of the femoral head, who un-

derwent total hip replacement. Patients older than 60 years were excluded from the study to rule out degenerative changes due to aging. The commonest etiologic factor was alcohol abuse, noted in 10 patients (Table). None of the hips had been operated on before. The mean duration of pain was 1.3 (0.2–3) years.

Preoperatively, the radiographs were examined for staging and measurement of joint space by two surgeons and one radiologist. The collapse of the femoral head was also evaluated with a concentric circle template. Only ARCO stage III hips (Ficat stage IIB or III) were included, 10 were stage IIIA and 5 IIIB. During the operation, gross appearance of the articular surface of the acetabulum was evaluated and graded (I–IV), according to Outerbridge (1964). A 1 × 2 cm slice of full-thickness articular cartilage with some subchondral bone was removed from the superior dome. The specimens were stained with hematoxylin-eosin and safranin-O with Weigert's iron hematoxylin and fast green. Mankin et al.'s (1970, 1971) histological and histochemical grading (0–14 points) for osteoarthritic cartilage was used for semiquantitative assessment of the cartilage. The evaluation was made by two surgeons and a pathologist. In case of a disagreement, the pathologist's score was accepted as the final grade. Total grade 0 was classified as normal, 1–5 as mild degeneration, 6–10 as moderate degeneration, and 11–14 as severe degeneration. The correlation between total grade and age, duration of pain, gross appearance, and degree of collapse was analyzed with the Spearman rank correlation coefficient.

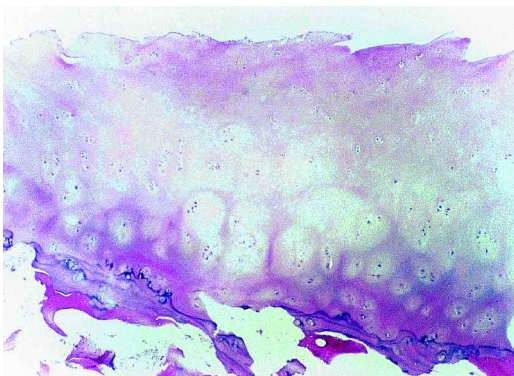
Clinical, radiological, histological data in 15 hips

No.	Age yr	Gender	Etiologic factor	ARCO stage	Gross appearance	Duration of pain (yr)	Depression (mm) of femoral head	Total grade
1	56	M	unknown	IIIB	II	0.2	2.0	7
2	41	M	alcoholic	IIIA	I	0.4	0	4
3	23	M	alcoholic	IIIB	I	1.0	3.0	10
4	59	M	alcoholic	IIIA	III	2.0	1.0	14
5				IIIA	II	2.0	1.5	9
6	58	M	alcoholic	IIIA	I	0.6	1.0	8
7	24	M	alcoholic	IIIA	II	0.5	1.5	7
8	24	M	alcoholic	IIIA	II	0.5	0.5	6
9	50	M	alcoholic	IIIA	I	1.0	0	3
10	56	M	alcoholic	IIIB	III	0.1	3.0	10
11	24	M	alcoholic	IIIA	II	3.0	0.5	7
12				IIIA	II	3.0	0.5	8
13	50	F	unknown	IIIA	II	0.5	1.0	7
14	34	M	alcoholic	IIIB	II	2.0	2.5	8
15	23	F	steroid	IIIB	III	3.0	3.0	7

Cases 4–5 and 11–12 bilateral

Results

The degree of collapse of the femoral head ranged from 0 to 3.0 mm. Grade of gross appearance was I in 4 hips, II in 8 hips, III in 3 hips. Total histological and histochemical grade of acetabular cartilage was mean 7. 3 hips had mild degeneration, 11 hips had moderate degeneration and 1 hip had severe degeneration. The total grade was not significantly correlated to age ($p = 0.3$), duration of pain ($p = 0.5$), or gross appearance ($p = 0.2$), but there was a significant correlation with the degree of collapse of the femoral head ($p = 0.02$).



Moderately osteoarthritic cartilages; surface irregularities, thinning of cartilage, cloning of chondrocytes, HE $\times 40$.

Discussion

Osteonecrosis of the femoral head eventually causes arthrosis that involves both the head and acetabulum. In ARCO stage IV hips, joint space narrowing is radiographically apparent, but in ARCO stage III hips, the absence of joint space narrowing has led surgeons to think that the acetabular cartilage was nearly normal, a rationale for a bipolar prosthesis (Cabanela 1990). Operations that preserve the femoral head have a generally lower long-term rate of success in stage III patients. Mont et al. (1995) found that clinical success in one half of core decompression in stage III hips after mean 2.5 years, and Fairbank et al. (1994) reported a one-third head survival rate after 10 years. Sugano et al. (1992) reported joint space narrowing in one tenth and osteophyte formation in two fifths of Ficat stage III hips after transtrochanteric rotational osteotomy with a follow-up of 6 years. Urbaniak et al. (1995) found that the probabilities of conversion to total hip arthroplasty within 5 years after vascularized fibular grafting in Marcus stage III, IV (ARCO III) hips were 23% and 29%, respectively. Our observations agree with those recently published by Steinberg et al. (1999). We think that even a minor degree of joint surface incongruity, resulting from

collapse of the femoral head, can cause rapid degeneration of the acetabular cartilage. This explains why head-preserving operations have bad long-term results in ARCO stage III hips and also the poorer results of bipolar prosthesis than those of total hip arthroplasty in the treatment of osteonecrosis.

- Cabanela M E. Bipolar versus total hip arthroplasty for avascular necrosis of the femoral head. *Clin Orthop* 1990; 261: 54-62.
- Fairbank A C, Bhatia D, Jinnah R H, Hungerford D S. Long-term results of core decompression for ischemic necrosis of the femoral head. *J Bone Joint Surg (Br)* 1994; 76: 42-9.
- Learmonth I D, Maloon S, Dall G. Core decompression for early atraumatic osteonecrosis of the femoral head. *J Bone Joint Surg (Br)* 1995; 77: 387-90.
- Mankin H J, Lippielo L. Biochemical and metabolic abnormalities in articular cartilage from osteo-arthritic human hips. *J Bone Joint Surg (Am)* 1970; 52: 424-34.
- Mankin H J, Dorfman H, Lippielo L, Zarins A. Biochemical and metabolic abnormalities in articular cartilage from osteo-arthritic human hips. II. Correlation of morphology with biochemical and metabolic data. *J Bone Joint Surg (Am)* 1971; 53: 523-37.
- Mont M A. Current concept review. Nontraumatic avascular necrosis of the femoral head. *J Bone Joint Surg (Am)* 1995; 77: 459-74.
- Mont M A, Carbone J J, Fairbank A C. Core decompression vs. non-operative management for avascular necrosis of the femoral head: An appraisal based on complete literature review (abstract). *ARCO Trans* 1995; 5: 57-8.
- Outerbridge R E. Further studies on the etiology of chondromalacia patella. *J Bone Joint Surg (Br)* 1964; 46: 179-84.
- Steinberg M E, Corces A, Fallon M. Acetabular involvement in osteonecrosis of the femoral head. *J Bone Joint Surg (Am)* 1999; 81: 60-5.
- Sugano N, Takaoka K, Ohzono K, Matsui M, Saito M, Saito S. Rotational osteotomy for non-traumatic avascular necrosis of the femoral head. *J Bone Joint Surg (Br)* 1992; 74: 734-9.
- Urbaniak J R, Coogan P G, Gunneson E B, Nunley J A. Treatment of osteonecrosis of the femoral head with vascularized fibular grafting. *J Bone Joint Surg (Am)* 1995; 77: 681-94.