

The Ilizarov method in total knee arthroplasty with nonunion of the proximal tibia—a case report

Vasfi Karatosun and Cebraïl Alekberov

Department of Orthopaedics and Traumatology, Dokuz Eylül University School of Medicine Hospital, TR-Izmir, 35340, Turkey. Correspondence: Dr. Vasfi Karatosun, Mithatpasa Cad 248/22, TR-35260 Izmir, Turkey
E-mail: vkaratosun@superonline.com
Submitted 00-09-27. Accepted 01-01-28

A 69-year-old woman was admitted to our clinic with pain in her right knee. She had been operated on with total knee arthroplasty (TKA) 12 years previously for osteoarthritis. 4 years after the operation, she fell and suffered a periprosthetic fracture of the tibia. The fracture was treated primarily in a long leg cast. 2 weeks later, open reduction and fixation with plate and screws was done due to an angular deformity. The fracture did not heal and the angular deformity increased to 15° of varus and 10° of recurvatum (Figure 1).

The plate and screws were removed 7 months after the operation. An Ilizarov frame with three rings was applied. 2 olive wires were used for the

proximal, 1 for the middle and 2 wires for the distal ring. Special attention was paid to inserting the proximal wires parallel to the joint line. A minimal number of wires was used to reduce the risk of infection. The angular deformity was corrected by using the rules of similar triangles (Herzenberg and Waanders 1991), then the frame was compressed (Figure 2). Full correction of the angular deformity required 2 weeks, by daily corrections of 1 mm. Fibular osteotomy was not done because it had been previously performed during the internal fixation.

The patient was allowed to bear weight on the fifth postoperative day and active knee movements

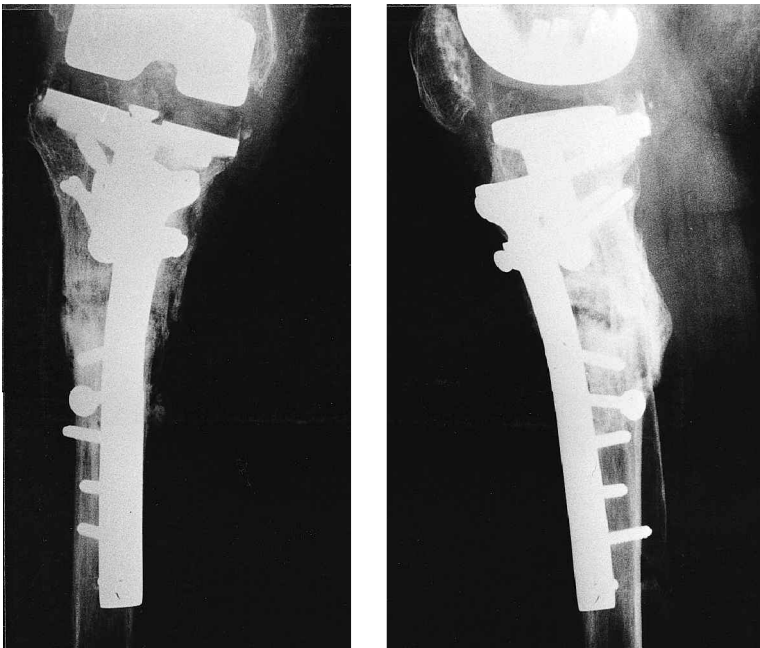


Figure 1. After application of the plate and screws in the the 5th postoperative month.

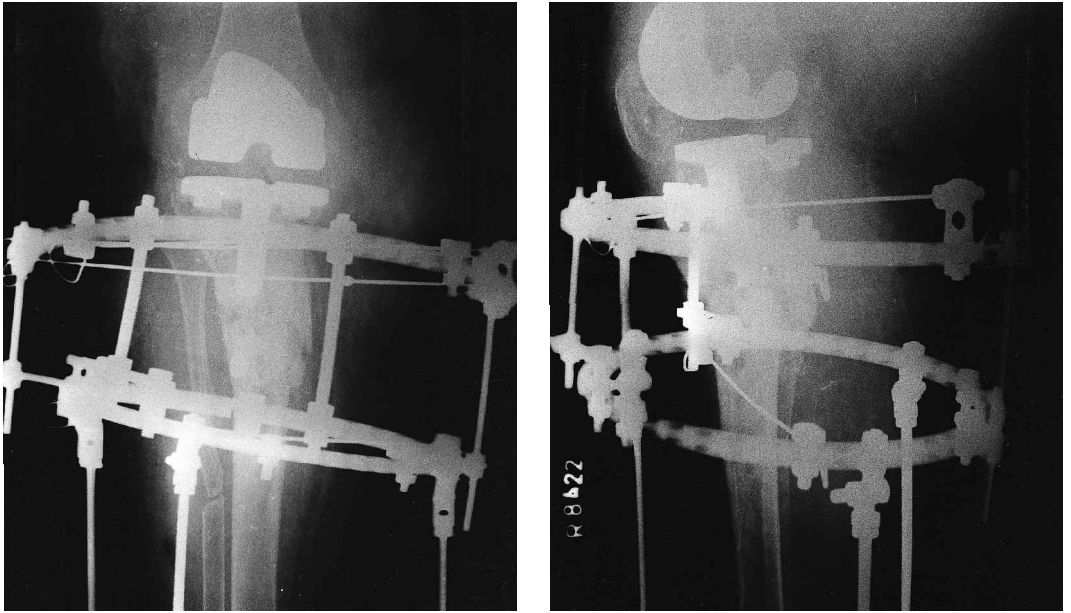


Figure 2. After application of the Ilizarov External Fixator in the 2nd month.

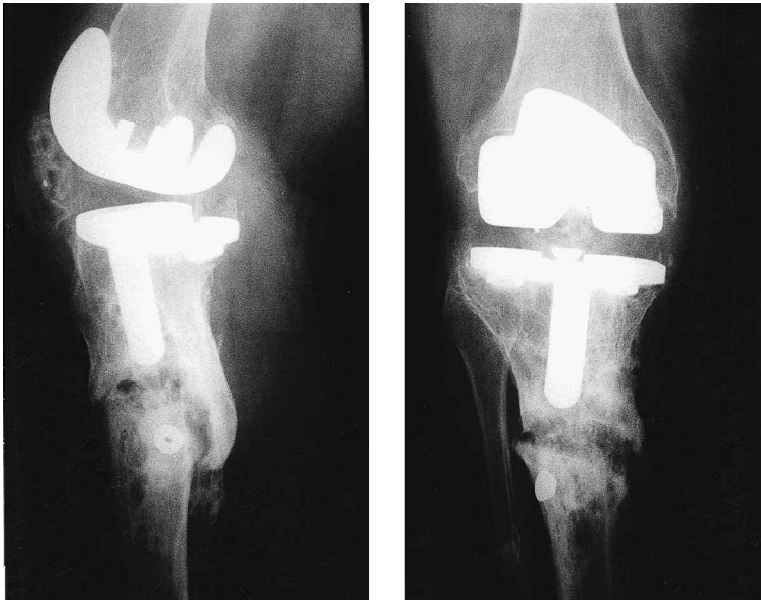

Figure 3. After union in the 60th postoperative month.

were begun. Radiographic union occurred after 5 months and the fixator was then removed. At the latest follow-up, 5 years after the removal of the frame, the patient had no pain and 115° of active knee motion (Figure 3).

Discussion

Periprosthetic fractures of the tibia occur infrequently (Rorabeck and Taylor 1999, Stuart and Hanssen 1999). Felix et al. (1997) recommended that periprosthetic tibial plateau fractures could be

treated nonoperatively with a brace or cast. The treatment of tibial fractures adjacent to the prosthetic stem or distal to it depends on the degree of displacement. Fractures with little, if any, displacement can be treated conservatively, but displaced ones should be treated with closed reduction and casting, although occasionally open reduction and internal fixation is needed (Felix et al. 1997).

Some authors advocate surgical treatment to maintain knee mobility (Merkel and Johnson 1986, Culp et al. 1987, Cordeiro et al. 1990, Healy et al. 1993, Rolston et al. 1995, Engh and Ammeen 1997). In our patient, the closed and subsequent open reduction failed. Nonunion developed probably because of extensive periosteal stripping, which reduced the vascular supply for healing (Rolston et al. 1995).

According to Merkel and Johnson (1986), surgical stabilization and bone grafting should be undertaken if the fracture does not heal despite operative treatment, or if the distal fragment is small or of poor quality, it may be removed and a revision or custom-made TKA can be considered.

The Ilizarov method has been successfully used in the treatment of tibial nonunion and angular deformity (Schwartzman et al. 1990, Ilizarov 1992). Simon and Brinker (1999) treated a case of periprosthetic femoral fracture after TKA with the Ilizarov method. We found no reports on tibial nonunion close to a TKA treated with this method. Our approach permitted correction of the angular deformity and resulted in healing (Figure 2). Early ambulation (Schwartzman et al. 1990, Ilizarov 1992, Simon and Brinker 1999) and weight bearing and active knee motions are important advantages of the Ilizarov method. A potential complication of this method is pin-track infection (Schwartzman et al. 1990, Simon and Brinker 1999), due to insertion of the pins close to the prosthesis (Figgie et al. 1990), but this did not occur in our case.

- Cordeiro E N, Costa R C, Carazzato J G, Silva J dos S. Periprosthetic fractures in patients with total knee arthroplasties. *Clin Orthop* 1990; 252: 182-9.
- Culp R W, Schmidt R G, Hanks G, Mak A, Esterhai J L Jr, Heppenstall R B. Supracondylar fracture of the femur following prosthetic knee arthroplasty. *Clin Orthop* 1987; 222: 212-22.
- Engh G A, Ammeen D J. Periprosthetic fractures adjacent to total knee implants: treatment and clinical results. *J Bone Joint Surg (Am)* 1997; 79 (7): 1100-13.
- Felix N A, Stuart M J, Hanssen A D. Periprosthetic fractures of the tibia associated with total knee arthroplasty. *Clin Orthop* 1997; 345: 113-24.
- Figgie M P, Goldberg V M, Figgie H E 3d, Sobel M. The results of treatment of supracondylar fracture above total knee arthroplasty. *J Arthroplasty* 1990; 5 (3): 267-76.
- Healy W L, Siliski J M, Incavo S J. Operative treatment of distal femoral fractures proximal to total knee replacements. *J Bone Joint Surg (Am)* 1993; 75 (1): 27-34.
- Herzenberg J E, Waanders N A. Calculating rate and duration of distraction for deformity correction with the Ilizarov technique. *Orthop Clin North Am* 1991; 22 (4): 601-11.
- Ilizarov G A. *Transosseous osteosynthesis* (Ed. Ass S. Green). Springer-Verlag, Berlin-Heidelberg 1992.
- Merkel K D, Johnson E W. Supracondylar fracture of the knee after total knee arthroplasty. *J Bone Joint Surg (Am)* 1986; 68 (1): 29-43.
- Rolston L R, Christ D J, Halpern A, O'Connor P L, Ryan T G, Uggem W M. Treatment of supracondylar fractures of the femur proximal to a total knee arthroplasty. A report of four cases. *J Bone Joint Surg (Am)* 1995; 77 (6): 924-31.
- Rorabeck C H, Taylor J W. Classification of periprosthetic fractures complicating total knee arthroplasty. *Orthop Clin North Am* 1999; 30 (2): 209-14.
- Schwartzman V, Choi S H, Schwartzman R. Tibial nonunions. Treatment tactics with the Ilizarov method. *Orthop Clin North Am* 1990; 21 (4): 639-53.
- Simon R G, Brinker M R. Use of Ilizarov external fixation for a periprosthetic supracondylar femur fracture. *J Arthroplasty* 1999; 14 (1): 118-21.
- Stuart M J, Hanssen A D. Total knee arthroplasty: periprosthetic tibial fractures. *Orthop Clin North Am* 1999; 30 (2): 279-86.