

Primary hemiarthroplasty in old patients with displaced femoral neck fracture

A 1-year follow-up of 103 patients aged 80 years or more

Cecilia Rogmark, Åke Carlsson, Olof Johnell and Ingemar Sernbo

Department of Orthopedics, Malmö University Hospital, SE-205 02 Malmö, Sweden. Cecilia.Rogmark@skane.se
Submitted 01-05-08. Accepted 02-04-27

ABSTRACT – 103 patients with displaced femoral neck fractures (Garden 3-4) treated with primary hemiarthroplasty in the Department of Orthopedics, Malmö University Hospital, Sweden 1998–1999 were followed in a prospective, consecutive study for 1 year. Inclusion criteria were age of at least 80 years, signs of mental changes and/or residence in an institution. The control group consisted of 69 patients with internal fixation (Hansson hook pins).

The arthroplasty group required more blood transfusions, a longer operation and had more superficial infections. No differences were detected as regards other complications, length of hospital stay, in-hospital mortality or ability to return home. The 1-year mortality rates were similar in the arthroplasty (29/103) and control groups (28/69). Within 1 year, we found a lower failure rate in the arthroplasty group (6/103) than in the control group (18/69). In the arthroplasty group, 2/103 had dislocations. Of the surviving arthroplasty patients at 12 months, 31/74 could walk as well as before the fracture and 55/74 had no pain.

We recommend primary hemiarthroplasty for demented and/or institutionalized patients over 80 years with displaced femoral neck fractures.

In Scandinavia, during the past decades, closed reduction and internal fixation has been the standard procedure for displaced femoral neck fractures. In other countries, primary arthroplasty is preferred. Several authors have suggested that the age and activity level of the patient with a hip fracture should determine the choice of treatment.

Patients under 70 years of age are suitable for internal fixation (Greenough and Jones 1988). Independent persons over 70 years benefit from total arthroplasty (Dorr et al. 1986, Skinner et al. 1989, Gebhard et al. 1992, Jonsson et al. 1996, Squires and Bannister 1999, Johansson et al. 2000, Ravikumar and Marsh 2000, Rogmark et al. 2002), while those who are frailer and dependent manage well with a hemiarthroplasty (Dorr et al. 1986, Gebhard et al. 1992, Eiskjaer and Ostgard 1993, Hudson et al. 1998). However, Parker and Pryor (2000) found that internal fixation and uncemented hemiarthroplasty were equally good in patients over 70 years. The demented patient with a displaced femoral neck fracture poses a special problem because of the higher risk of dislocation of the prosthesis (Khan et al. 1981, Woolson and Rahimtoola 1999) and higher mortality after a femoral neck fracture (Ions and Stevens 1987, Clayer and Bauze 1989). van Dortmont et al. (2000) considered internal fixation safer in this patient group, since they had a higher mortality after hemiarthroplasty than lucid patients.

The so-called NOA study (“Nail or Arthroplasty”), a prospective, randomized study of displaced femoral neck fractures in independent persons aged 70 years or older, showed better function and fewer failures after primary arthroplasty than after internal fixation (Rogmark et al. 2002). This led us to study even older, demented and/or institutionalized patients with displaced femoral neck fractures. Since the inclusion of confused patients in a randomized study involves ethical problems, we decided to do a prospective, consec-

utive follow-up study of primary hemiarthroplasties after displaced femoral neck fractures in this patient group. The aim was to compare patients who had undergone a primary hemiarthroplasty with those who had had an internal fixation, as regards early and late complications and mortality.

Patients and methods

103 patients with displaced femoral neck fractures (Garden 3-4) treated in the Department of Orthopedics, Malmö University Hospital, Sweden during January 1998–August 1999 were followed in a prospective, consecutive study for 1 year. Inclusion criteria were age of at least 80 years, signs of mental changes (manifest dementia or prolonged confusion) and/or institutionalization (nursing home or old people's home). Bedridden patients were excluded, as also were those with rheumatoid arthritis, pathological fractures or a life-threatening medical condition. The selection of patients was based on the clinical examination, previous medical records and information from family members.

117 patients fulfilled the inclusion criteria, but 8 were excluded for medical reasons and another 6 for logistic reasons, such as the box with laminar flow was not available or lack of personnel familiar with the arthroplasty procedure during weekends. The latter 6 patients underwent internal fixation. The primary end-point was failure defined as dislocation, loosening, deep infection or femoral fracture adjacent to the prosthesis stem.

Their median age was 87 (80–99) years, 93/103 were women, 22/103 were living in a nursing home and 67/103 in an old people's home. A walking frame was used by 64/103 before the fracture. Concomitant diseases were common (Table 1).

All patients were operated on with a hemiarthroplasty (Ultima LX, Johnson & Johnson), using a box and gentamicin-cement. All patients received an intravenous antibiotic (cloxacillin or clindamycin) and subcutaneous antithrombotic (enoxaparin) prophylaxis. Spinal anesthesia was used in 94/103. A lateral approach without a trochanteric osteotomy was done, with the patient in a supine position. 18 surgeons performed the operations. The demented patients (n = 49) were advised

Table 1. Other diseases before fracture

	Treatment group (arthroplasty) (n = 103)	Control group (internal fixation) (n = 69)
Senile dementia	49	40
Heart/lung disease	44	28
Stroke	20	8
Impaired vision	20	7
Previous hip fracture	13	16
Diabetes mellitus	13	4
Parkinson's disease	5	2

to use a knee-brace for 6 weeks after surgery to prevent dislocation.

All patients were supposed to have a clinical examination 4 and 12 months after surgery, the latter examination included a radiograph of the hip.

A control group of 69 patients was selected from the group of patients excluded from our previous randomized study (because of institutionalization and/or signs of mental change) (Rogmark et al. 2002). The control group had the same inclusion criteria as the arthroplasty one (age over 80 years, institutionalization and/or signs of mental change) and also the same exclusion criteria. Their median age was 86 (80–99) years, 46/69 were women, 17/69 lived in nursing homes and 42/69 in an old people's home. 39/69 needed at least a walking frame. Thus, the groups were similar except for the greater percentage women in the arthroplasty group. The control group was treated with closed reduction and internal fixation with Hansson (1982) hook-pins in our hospital during January to December 1997.

The arthroplasty patients were operated on within 2 days, apart from 6/103 patients treated with warfarin. Of the 69 internally fixated patients, 2 had to wait more than 2 days for surgery, because of concurrent diseases.

Statistical analysis was done with the chi-square test, t-test and Kaplan-Meier analysis.

Results

The arthroplasty group had more superficial infections. No other differences were found between

Table 2. Postoperative complications

	Treatment group (arthroplasty) (n = 103)	Control group (internal fixation) (n = 69)
Superficial infection ^a	20	2
Urinary tract infection	18	13
Pneumonia	5	3
Stroke	3	3
Heart/lung disease	4	8
Other	2	3

^a Only statistically significant difference ($p = 0.001$, chi-2)

the groups as regards postoperative complications (Table 2).

In the arthroplasty group (103 patients), the median duration of surgery was 65 (30–125) min and the median hospital stay 9 (1–83) days. Their mean preoperative hemoglobin concentration was 124 g/L. Blood transfusions were given to 85 patients and 32 needed 3 or more units. 5 died in hospital and 65 were discharged directly to their previous residence.

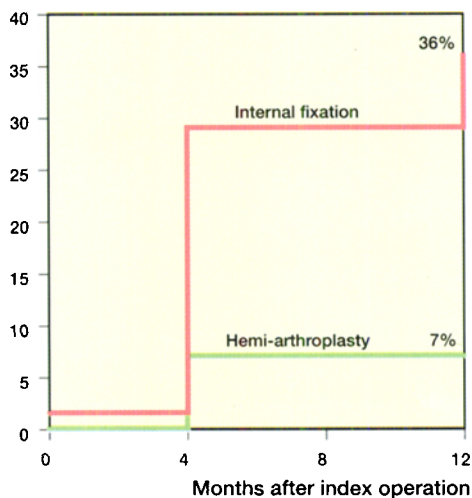
In the internally-fixated control group (69 patients), the mean duration of surgery was 20 (7–40) min, but the time taken for reduction was not included in this estimate. Their mean hospital stay was 8 (1–49) days. Their mean preoperative hemoglobin concentration was 128 g/L. Only 7 received a blood transfusion, and 1 needed 3 or more units. 6 died during their hospital stay and 43 were discharged directly to their previous residence.

Thus, the arthroplasty group needed more blood transfusions ($p < 0.001$) and a longer operation ($p < 0.001$). The length of hospital stay, in-hospital mortality or ability to return home were similar.

15/103 died after 4 months in the arthroplasty group versus 19/69 ($p = 0.04$) in the control group, and 29/103 after 12 months in the arthroplasty group versus 28/69 ($p = 0.06$) in the control group.

Within 1 year, we found a failure rate of 6/103 in the arthroplasty group, including 2 perioperative, uncomplicated fractures of the proximal femur. 2 patients developed deep infections and 1 of these finally received a total hip arthroplasty. 1 patient had recurrent dislocations and a deep infection and was reoperated on. She then underwent a Girdlestone procedure. Another patient had a single

Cumulative proportion failure



The cumulative failure rate (Kaplan-Meier analysis).

dislocation. All 6 failures were diagnosed before or at 4 months. 2 more patients were classified as “uncertain” because of persistent pain in the hip. In the arthroplasty group, 10 patients who died before 4 months had no further contact with the orthopedic department after discharge and therefore could not be definitely classified as regards failure.

In the control group with internal fixation, 17/69 patients died without having had another orthopedic examination. Of the 18 cases reported as failures within 12 months, 16 were caused by pseudarthrosis and 2 were thought to have avascular necrosis of the femoral head. 10 had had a secondary arthroplasty and in 1 the pins were extracted. 15 failures were diagnosed before or at 4 months, and 3 between 4 and 12 months. 4 other patients were classified as “uncertain”.

Thus, after 12 months 68/74 surviving patients had successfully treated fractures in the arthroplasty group, as compared to 26/41 in the control group ($p < 0.001$). The cumulative failure rate using Kaplan-Meier analysis was 7% in the arthroplasty group, and 36% in the internal fixation group (log rank test $p > 0.001$) (Figure).

At the follow-up at 1 year, we evaluated function in the arthroplasty patients. Of the surviving 74 patients, 50 lived in their original residence, 32 could walk as well as before the hip fracture. 6 needed no walking aids or one stick, 38 a walking frame. 9 could not walk. As regards hip pain

when walking or standing, 55 had no pain. The rate of uncertain answers to these 4 questions ranged between 6% and 24%. 4 patients were lost to follow-up.

The control group has not been examined as regards function at 1 year. However, the results at 1 year in the treatment group above can be compared to the younger (mean age 84 years), healthier and lucid cohort of 90 patients having a hemiarthroplasty in our NOA study (see Introduction) (Rogmark et al. 2002), who underwent the same evaluation. After 1 year, of the 71 survivors in this group, 52 had returned to their original residence and 46 had no pain, i.e., the same results as for the arthroplasty group in the present study. Only 14 had recovered their previous walking ability, but more of them managed to walk without walking aids or with just one stick (22) and only one could not walk. This group had the same total failure rate (6/90) and the same mortality at 1 year (19/90).

Discussion

Over the past few years, a broader consensus has been reached as regards treatment of displaced femoral neck fractures in active, independent elderly patients; they benefit from a primary arthroplasty. (Dorr et al. 1986, Skinner et al. 1989, Gebhard et al. 1992, Jonsson et al. 1996, Squires and Bannister 1999, Johansson et al. 2000, Ravikumar and Marsh 2000, Rogmark et al. 2002). However, some uncertainty remains concerning the 'old old', demented, dependent patient's femoral neck fracture.

Closed reduction and internal fixation has been considered faster and easier to perform, with the advantage of saving the natural joint if healing succeeds. Its obvious disadvantages are the high failure and reoperation rates (Lu-Yao et al. 1994). A very old or frail patient is often denied a reoperation for medical reasons, and is therefore immobilized, with a painful nonunion or segmental collapse of the femoral head. Nilsson et al. (1989) showed that 50% of the patients with healing complications were confined to a wheelchair by the time of the secondary arthroplasty.

A primary arthroplasty is more time- and cost-consuming in the initial phase. In the long run, the

complications associated with internal fixation, will make costs the same for both treatments (Palmer et al. 2000, Parker and Pryor 2000). In studies reporting on arthroplasties with older cementing techniques and less effective prophylaxis of infections, both the rates of loosening and of sepsis were higher than in contemporary studies. The risk of dislocation associated with hemiarthroplasty has been reported to be as high as 11% (Holmberg et al. 1987, Skinner et al. 1989), but can be lowered to 3% by appropriate precautions and a lateral surgical approach (Unwin and Thomas 1994). The total dislocation rate in our material was 2%. Old age, senile dementia and neuromuscular diseases may increase the risk of dislocation (Khan et al. 1981, Woolson and Rahimtoola 1999).

No data show that early mortality is significantly higher after primary arthroplasty (Lu-Yao et al. 1994). Unless the groups are randomized, it is difficult to compare mortality rates between patients treated with internal fixation or arthroplasty. By merely choosing the surgical procedure, a selection is made (Zindrick et al. 1985), based on the old belief that internal fixation should be safer for an old patient. In our material the internal fixation group had a slightly higher mortality. This can be partly explained by the higher percentage of men in this group. Since there is no significant difference in mortality during hospital stay, we consider both procedures equally safe, even in this old and frail patient group.

Primary arthroplasty implies more blood transfusions and a longer operation, which entails higher costs. Some studies (Koval et al. 1997, Levi and Sandberg 1998, Carson et al. 1999) show that blood transfusions reduce autoimmunological defense and increase the risk of bacterial infections. In our material, the hemiarthroplasty group had more superficial wound infections than the internally fixated control group, but the same incidence of urinary tract infections and pneumonia. Both groups had equally long hospitalization.

The frailty of these patients must always be taken into consideration. As compared to the younger and healthier group undergoing hemiarthroplasty in the NOA study (Rogmark et al. 2002), the treatment group in the present study had a higher rate of postoperative superficial infections, pneumonia and urinary tract infections. These complications

may be regarded as minor, but prophylaxis must be given to reduce them.

About 3 of 4 patients had no pain after 1 year, but only 43% have regained their ability to walk as well as before the fracture. As orthopedic surgeons, we control rehabilitation in the orthopedic department, but we do not know what will happen to the patients when they leave the hospital. Many authors have reported that active geriatric rehabilitation is effective and reduces costs (Clayer and Bauze 1989, Borgquist et al. 1991, Farnworth et al. 1994, Huusko et al. 2000). If we implant an expensive arthroplasty, it is essential that effective rehabilitation is also given in nursing homes and old people's homes. Currently in Malmö, we are improving our cooperation with physiotherapists in local care centers, and, with their help, trying to educate the eldercare staff.

Our study showed a good result after primary hemiarthroplasty in a cohort of old, demented and/or institutionalized persons and we recommend primary hemiarthroplasty for patients over 80 years with displaced femoral neck fractures.

No benefits in any form have been or will be received from a commercial party related directly or indirectly to the subjects of this article.

- Borgquist L, Lindelow G, Thorngren K G. Costs of hip fracture. Rehabilitation of 180 patients in primary health care. *Acta Orthop Scand* 1991; 62 (1): 39-48.
- Carson J L, Altman D G, Duff A, Noveck H, Weinstein M P, Sonnenberg F A et al. Risk of bacterial infection associated with allogeneic blood transfusion among patients undergoing hip fracture repair. *Transfusion* 1999; 39 (7): 694-700.
- Clayer M T, Bauze R J. Morbidity and mortality following fractures of the femoral neck and trochanteric region: analysis of risk factors. *J Trauma* 1989; 29 (12): 1673-8.
- Dorr L D, Glousman R, Hoy A L, Vanis R, Chandler R. Treatment of femoral neck fractures with total hip replacement versus cemented and noncemented hemiarthroplasty. *J Arthroplasty* 1986; 1 (1): 21-8.
- Eiskjaer S, Ostgard S E. Survivorship analysis of hemiarthroplasties. *Clin Orthop* 1993; 286: 206-11.
- Farnworth M G, Kenny P, Shiell A. The costs and effects of early discharge in the management of fractured hip (published erratum appears in *Age Ageing* 1995; 24 (4): 367). *Age Ageing* 1994; 23 (3): 190-4.

- Gebhard J S, Amstutz H C, Zinar D M, Dorey F J. A comparison of total hip arthroplasty and hemiarthroplasty for treatment of acute fracture of the femoral neck. *Clin Orthop* 1992; 282: 123-31.
- Greenough C G, Jones J R. Primary total hip replacement for displaced subcapital fracture of the femur. *J Bone Joint Surg (Br)* 1988; 70 (4): 639-43.
- Hansson L I. Osteosynthesis with the hook-pin in slipped capital femoral epiphysis. *Acta Orthop Scand* 1982; 53 (1): 87-96.
- Holmberg S, Kalen R, Thorngren K G. Treatment and outcome of femoral neck fractures. An analysis of 2418 patients admitted from their own homes. *Clin Orthop* 1987; 218: 42-52.
- Hudson J I, Kenzora J E, Hebel J R, Gardner J F, Scherlis L, Epstein R S et al. Eight-year outcome associated with clinical options in the management of femoral neck fractures. *Clin Orthop* 1998; 348: 59-66.
- Huusko T M, Karppi P, Avikainen V, Kautiainen H, Sulkava R. Randomised, clinically controlled trial of intensive geriatric rehabilitation in patients with hip fracture: subgroup analysis of patients with dementia. *BMJ* 2000; 321 (7269): 1107-11.
- Ions G K, Stevens J. Prediction of survival in patients with femoral neck fractures. *J Bone Joint Surg (Br)* 1987; 69 (3): 384-7.
- Johansson T, Jacobsson S A, Ivarsson I, Knutsson A, Wahlstrom O. Internal fixation versus total hip arthroplasty in the treatment of displaced femoral neck fractures: a prospective randomized study of 100 hips. *Acta Orthop Scand* 2000; 71 (6): 597-602.
- Jonsson B, Sernbo I, Carlsson A, Fredin H, Johnell O. Social function after cervical hip fracture. A comparison of hook-pins and total hip replacement in 47 patients. *Acta Orthop Scand* 1996; 67 (5): 431-4.
- Khan M, Brakenbury P, Reynolds I. Dislocation following total hip replacement. *J Bone Joint Surg (Br)* 1981; 63 (2): 214-8.
- Koval K J, Rosenberg A D, Zuckerman J D, Aharonoff G B, Skovron M L, Bernstein R L et al. Does blood transfusion increase the risk of infection after hip fracture? *J Orthop Trauma* 1997; 11 (4): 260-5; discussion 265-6.
- Levi N, Sandberg T. Blood transfusion and postoperative wound infection in intracapsular femoral neck fractures. *Bull Hosp Jt Dis* 1998; 57 (2): 69-73.
- Lu-Yao G L, Keller R B, Littenberg B, Wennberg J E. Outcomes after displaced fractures of the femoral neck. A meta-analysis of one hundred and six published reports. *J Bone Joint Surg (Am)* 1994; 76 (1): 15-25.
- Nilsson L T, Strömquist B, Thorngren K G. Secondary arthroplasty for complications of femoral neck fracture. *J Bone Joint Surg (Br)* 1989; 71 (5): 777-81.
- Palmer S J, Parker M J, Hollingworth W. The cost and implications of reoperation after surgery for fracture of the hip. *J Bone Joint Surg (Br)* 2000; 82 (6): 864-6.
- Parker M J, Pryor G A. Internal fixation or arthroplasty for displaced cervical hip fractures in the elderly. A randomised controlled trial of 208 patients. *Acta Orthop Scand* 2000; 71 (5): 440-6.

- Ravikumar K J, Marsh G. Internal fixation versus hemiarthroplasty versus total hip arthroplasty for displaced subcapital fractures of femur—13 year-results of a prospective randomised study. *Injury* 2000; 31 (10): 793-7.
- Rogmark C, Carlsson A, Johnell O, Sernbo I. A prospective randomised trial of internal fixation versus arthroplasty for displaced fractures of the neck of the femur. Functional outcome for 450 patients at two years. *J Bone Joint Surg (Br)* 2002; 84 (2): 183-8.
- Skinner P, Riley D, Ellery J, Beaumont A, Coumine R, Shafiqhian B. Displaced subcapital fractures of the femur: a prospective randomized comparison of internal fixation, hemiarthroplasty and total hip replacement. *Injury* 1989; 20 (5): 291-3.
- Squires B, Bannister G. Displaced intracapsular neck of femur fractures in mobile independent patients: total hip replacement or hemiarthroplasty? *Injury* 1999; 30 (5): 345-8.
- Unwin A J, Thomas M. Dislocation after hemiarthroplasty of the hip: a comparison of the dislocation rate after posterior and lateral approaches to the hip. *Ann R Coll Surg Engl* 1994; 76 (5): 327-9.
- van Dortmont L M, Douw C M, van Breukelen A M, Laurens D R, Mulder P G, Wereldsma J C et al. Outcome after hemi-arthroplasty for displaced intracapsular femoral neck fracture related to mental state. *Injury* 2000; 31 (5): 327-31.
- Woolson S T, Rahimtoola Z O. Risk factors for dislocation during the first 3 months after primary total hip replacement. *J Arthroplasty* 1999; 14 (6): 662-8.
- Zindrick M R, Daley R J, Hollyfield R L, Jobski R, Kinzler G M, Schwartz C M et al. Femoral neck fractures in the geriatric population: the influence of perioperative health upon the selection of surgical treatment. *J Am Geriatr Soc* 1985; 33 (2): 104-8.