

Mycotic aneurysm of the descending thoracic aorta with intraspinal extension—a case report

Mahesh K Pimple¹, Ranjeet S Narlawar² and Mihir R Bapat¹

Departments of ¹Orthopedics and ²Radiology, King Edward Memorial Hospital, Parel, Mumbai, 400 012, India. Correspondence: Dr. R.S. Narlawar. drranjeet@hotmail.com.

Submitted 01-10-09. Accepted 02-02-16

A 58-year-old man presented with pain since 1 month and swelling in the dorsal spinal region with acute onset of paraplegia. On examination, he had slight kyphosis of the dorsal spine with marked tenderness. His muscle strength throughout the lower limbs was grade 0 with spasticity and exaggerated reflexes. 50% hypoesthesia was present below the 5th dorsal level, but urinary bladder and bowel functions were not affected.

Radiographs of the dorsolumbar spine showed destruction of the 5th to 8th dorsal vertebrae with a kyphosis and those of the chest demonstrated a soft tissue density mass in the posterior mediastinum. The erythrocyte sedimentation rate was 76 mm per hour. On MRI, the aortic arch was dilated after the origin of the great vessels as also was the entire descending thoracic aorta (Figure 1). A saccular outpouching was seen arising from the medial wall of the descending thoracic aorta at the level of the 5th to 8th dorsal vertebrae. This measured about 4 × 6 × 6 cm in its widest axial plane (Figure 2). A central patent lumen with large eccentric thrombus was found mainly on the right side. It was iso-intense on T1-weighted images and not homogeneously hyperintense on T2-weighted images (Figure 3). This contained a few iso- to hypointense septae and the wall of the aorta was thickened on the left side as well. The descending aorta measured about 5 × 4.8 cm in its axial plane proximal to the aneurysm and about 4 × 4 cm in its axial plane distal to the aneurysm. The 5th to 8th dorsal vertebrae were completely eroded by the aneurysm. The thrombosed part of the aneurysm extended intraspinally from the 5th to 8th dorsal vertebrae, displacing the cord towards the right and posteriorly and compressing it at these levels, with signal abnormality in the cord suggesting edema/ischemia secondary to compression. The aneurysm also involved the pre- and para-vertebral regions at these levels and extended up to the level

of posterior vertebral elements, especially at the 7th and 8th dorsal vertebrae. The posterior ends of the ribs were eroded at these levels, especially on the left side (Figure 2). The abdominal aorta was of normal size and the other vertebrae and discs appeared normal.

The Mantoux test and ELISA test for tuberculous antigen were positive, but the antistaphylococcal antigen test was negative. The ECG showed myocardial ischemia, and 2-D echo and color Doppler studies revealed triple coronary vessel disease, for which coronary artery bypass surgery was recommended. The patient refused surgery and was lost to follow-up.

Discussion

The term mycotic aneurysm was first used by Osler in 1885 to describe aneurysms arising from septic emboli in patients with bacterial endocarditis. Today, the term is used in a broader sense for any infected aneurysm. The pathogenesis may include one or more of the following mechanisms: (a) septic embolization causing intravascular occlusion, (b) contiguous spread from osteomyelitis or abscess, (c) iatrogenic vascular manipulation, and (d) infection affecting sites of intimal defects, as in atheromatous plaques (Osler 1885). In the review by Long et al. (1999), tuberculous mycotic aneurysm of the aorta seemed to cause three fourths of the cases of erosion of the aortic wall by contiguous spread. The usual fate of the rare tuberculous abdominal aortic aneurysm is rupture into the lung (De Prophetis et al. 1959, Quaini et al. 1985) or esophagus (Volini et al. 1962).

MRI shows the aneurysmal sac with its intraspinal extension and suggests its infectious nature in terms of an atypical site, saccular aspect, adjacent inflammatory process, or occasional

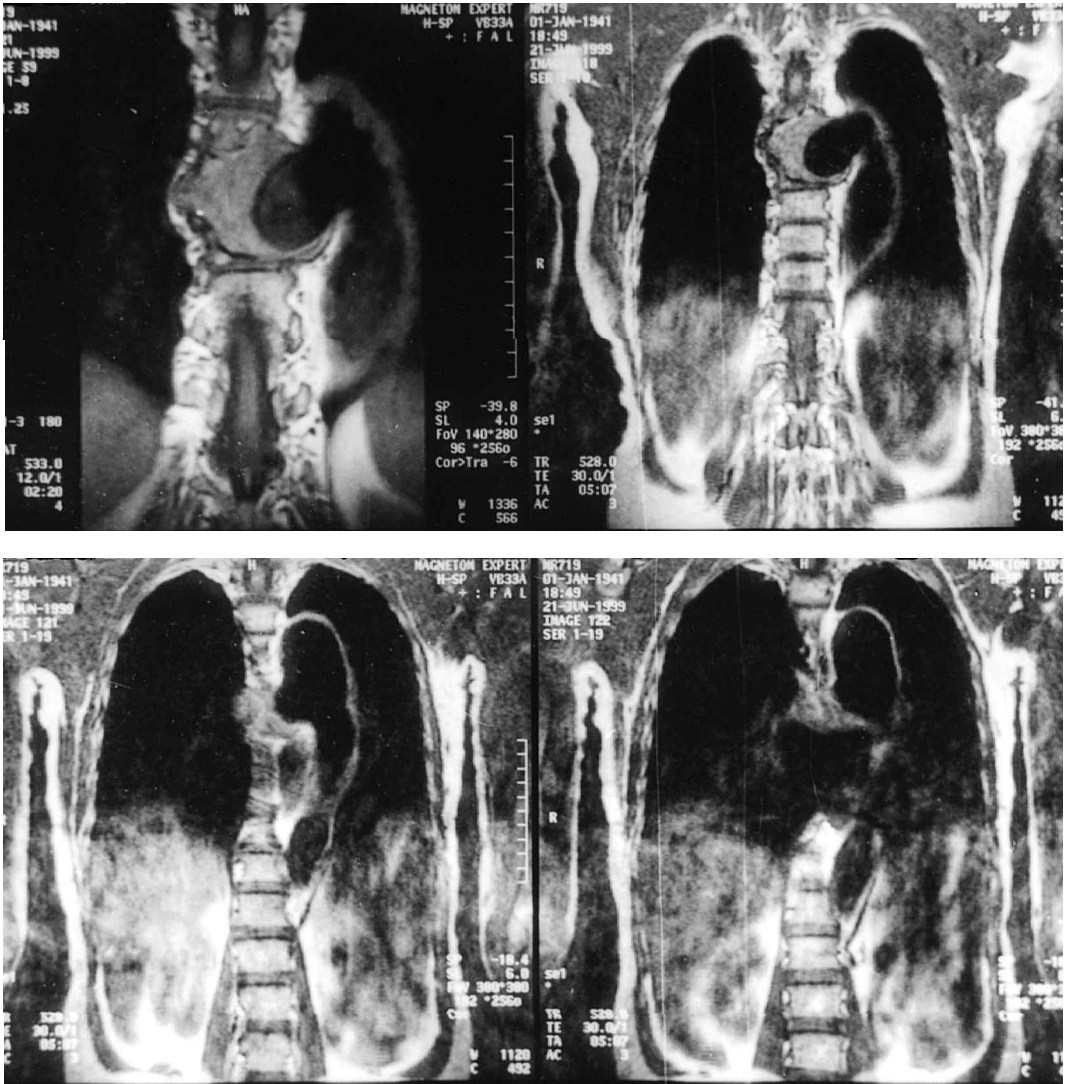


Figure 1. T1W coronal images show saccular dilatation of the descending thoracic aorta with extrinsic thrombus and vertebral destruction.

bone destruction. It also clearly demonstrates the changes in the cord secondary to ischemia or compression.

Treatment is essentially surgical. However, preoperative antituberculous treatment improves the condition of the aortic wall and surrounding soft tissue and thus reduces the morbidity and mortality associated with the procedure. Surgery includes excision of the vessel, debridement of the surrounding tissue and restitution of blood flow. Vascular bypass should be performed outside the normal anatomical path of the vessels to avoid placing the synthetic graft in a bed of infected

tissue. Lethal progression of the disease may be prevented by rapid diagnosis and early surgical intervention. However, the prognosis is extremely poor in patients with mycotic aneurysm of the aorta (Johansen and Devin 1983). Although rare, the possibility of tuberculous aneurysm should be considered when there is radiological evidence of soft tissue involvement near major vessels.

A review of the literature shows only two previous cases of mycotic aneurysm of the thoracic descending aorta with epidural extension causing paraplegia (Rubery et al. 1995). However, neither of these patients had tuberculosis.

In our patient with cardiovascular disease, we believe that intimal damage must have predisposed the tissue to lodgment of tuberculous bacilli.

De Prophetis N, Armitage H V, Triboletti. Rupture of tuberculous aneurysm into lung. *Ann Surg* 1959; 150: 1046-51.

Johansen K J, Devin J. Mycotic aortic aneurysm: a reappraisal. *Arch Surg* 1983; 118 (5): 583-8.

Long R, Guzman R, Greenberg H, Safneck J, Hershfield E. Tuberculous mycotic aneurysm of the aorta: review of the published medical and surgical experience. *Chest* 1999; 115: 522-31.

Osler W G. Lectures on malignant endocarditis. *BMJ* 1885; 1: 467-72.

Quaini E, Donatelli F, Bonacina E, Vittali E, Colombo T, Panzeri E. Mycotic tuberculous aneurysm of the descending thoracic aorta. *Tex Heart Inst J* 1985; 12: 257-60.

Rubery P T, Smith M D, Cammisa F P, Silane M. Mycotic aortic aneurysm in patients who have lumbar vertebral osteomyelitis: A report of two cases. *J Bone Joint Surg (Am)* 1995; 77: 1729-32.

Violini F I, Olfield R C, Thompson J R, Kent G. Tuberculosis of the aorta. *JAMA* 1962; 181: 78-81