

Surgical treatment of talus fractures

A retrospective study of 80 cases followed for 1–15 years

Wito Schulze, Jens Richter, Otto Russe, Patrick Ingelfinger and Gert Muhr

Department of Surgery, BG-Kliniken Bergmannsheil, Ruhr-University Bochum, Germany. Correspondence: Dr. Wito Schulze, Orthopädische Klinik, Vivantes Klinikum Berlin-Hellersdorf, Akademisches Lehrkrankenhaus der Charité, Humboldt-Universität zu Berlin, Mysłowitzer Str. 45, DE-12621 Berlin, Germany. E-mail: schulzenhaus@web.de
Submitted 01-03-22. Accepted 01-11-27

ABSTRACT – We retrospectively reviewed 79 patients (80 talar fractures) operated on between 1994 and 1997. The average follow-up was 6 (1–15) years. 15 patients had a Marti/Weber fracture type I, 14 patients a type II, 32 patients a type III, and 19 patients a type IV fracture. 46 patients suffered a fracture of the talar neck, Hawkins type I in 10 patients, type II in 18, type III in 17 and type IV in 1 patient. 18/23 patients directly placed in our department were operated on within 6 hours of admission. Primary arthrodesis of both the ankle and subtalar joint was performed twice. Secondary arthrodesis of the ankle joint was done in only 3 patients. Combined secondary arthrodesis of the ankle and subtalar joint was performed in 5 and arthrodesis of the talonavicular joint in 1 patient. According to the Hawkins score, 35/80 feet achieved good/very good function versus 43 with the Mazur score. Radiographs showed ankle or subtalar arthrosis in two thirds of the patients. A normal range of motion was achieved in 18 ankle and 19 subtalar joints. The overall rate of talar necrosis was 9/80 fractures.

but to shorten the duration of joint immobilization, some authors recommend internal fixation of Hawkins type I fractures (Hausel 1980, Haase et al. 1995, Kundel et al. 1995, Schulze et al. 1998). There is a consensus that dislocated talar fractures should be operated on (Kundel et al. 1995, Schulze et al. 1998).

The results of treatment of talar fractures are due mainly to the presence of bone necrosis or secondary arthrosis in the surrounding joints. Müller (1978) found necrosis in almost half of 44 talar fractures, most of which had been treated without surgery, but arthrodesis was necessary in 9 patients. In a multi-center study, the German AO-group showed that the collapse rate could be lowered by surgery (Kuner and Lindenmaier 1983). Consequently, internal fixation is commonest and non-operative treatment is used in exceptional cases (Dávid et al. 1996).

We assessed retrospectively our results of surgical treatment of talar fractures.

3% of fractures of the foot involve the talus (Kuner et al. 1978). The most widely used classification of fractures is that of Marti/Weber (Marti 1978, Grob et al. 1985, Sanders 1999). Talar neck fractures are classified by Hawkins' method (1970), together with that of Canale and Kelly (1978) to include a type IV fracture (Table 1). The indications for surgical treatment and duration of no weight bearing are still disputed (Baumhauer and Alvarez 1995). Undisplaced talar neck fractures can be treated without surgery (Beck 1991, Dávid et al. 1996),

Patients and methods

From January 1984 to December 1997, 99 talar fractures (98 patients) were operated on. Follow-up data were available in 79 patients (80 fractures).

67 were men and their average age was 33 (7–64) years at the time of injury. 23 patients were directly admitted to our service and 18 were operated on within 6 hours. 5 patients could not be treated immediately due to soft tissue problems or other injuries. The median interval between accident and surgery was 0 (0–12) days, and for

Table 1. Marti/Weber classification of talar fractures (Marti 1978, Grob et al. 1985) and Hawkins classification of talar neck fractures (Hawkins 1965) showing prevalences in the study population

Fracture type	Marti/Weber classification	n	Hawkins classification	n
I	Distal talar neck and talar head fractures, peripheral fractures and osteochondral flakes	15	Undisplaced talar neck fractures	10
II	Undisplaced talar neck and corpus fractures	14	Talar neck fractures with dislocation and/or luxation of the subtalar joint	18
III	Dislocated talar neck and corpus fractures	32	Talar neck fractures with luxations involving the subtalar and ankle joints	17
IV	Proximal talar neck fractures with corpus tali luxated out of the intermalleolar space or comminuted fracture	19	Type III with additional luxation involving the talonavicular joint	1
Total		80		46

patients referred to us from other hospitals, it was 6 (0–420) days because of soft tissue problems or delays in diagnosis and transfer. 12 patients were polytraumatized and 52 had at least one more fracture which had to be treated. 40 patients had ipsilateral fractures of the lower extremity.

Etiology and pathomechanism of injury

14 fractures occurred during leisure activities, 31 being traffic accidents, 25 accidents at work, 7 accidents during sports and 3 at home. Most fractures were caused by a high-energy trauma.

Fracture classification

Conventional radiographs and an axial calcaneal projection were used for diagnosis. 65 were central fractures of the corpus and neck and 15 peripheral fractures. The fractures were classified by Marti/Weber's method (Marti 1978, Grob et al. 1985, Sanders 1999) and the talar neck fractures by Hawkins' (1965) and Canale and Kelly's (1978) method (Table 1). 10 fractures were open: 5 grade 1, 2 grade 2 and 3 grade 3, according to Gustilo and Anderson (1976).

Fracture reduction

Among the 51 Marti/Weber type III and IV fractures, closed reduction was done successfully in 2 patients in the emergency room, in 3 patients intraoperatively and in 11 cases, it was performed before admission to our department. In the remainder, the reduction was done during the operation.

Surgical approach

An anterolateral approach was used for the 32 talar neck and corpus fractures. In 4 of these patients, an additional osteotomy of the medial malleolus was also done. In 3 patients, a combination of the anteromedial and lateral approaches was used. We used the medial approach in 17 other patients with talar neck and corpus fractures, which was combined in 6 patients with an osteotomy of the medial malleolus. In the remaining patients, the lateral approach was used in 15 cases, the antero-lateral in 5, and the posterior in 4.

With an open talar fracture, the wound was used as the primary surgical access after initial extensive debridement had been performed. Fixation of the fracture was done in 7 patients through the wound only. In 3 patients, additional incisions were needed.

Fracture fixation

In 28 non-comminuted fractures, we used partially threaded cancellous screws with short to medium long threads. Continuous threaded screws were used in 30 patients. In 5, both types of screws were used simultaneously. If possible, screws were placed in pairs in a divergent manner. Starting in 1993, titanium screws were employed to permit subsequent MRI scans for diagnosing osteonecrosis. The intraoperative temporary fixation with K-wires proved useful. After radiographic confirmation of correct fragment positioning, the wires were replaced by cannulated screws. In cases of distal talar fractures with screw insertion close to the talonavicular joint, we embedded the screw

Table 2. Type of osteosynthesis

Surgical procedure	Number
Total number of screw osteosyntheses	67
Number of screws — 1	8
2	53
3	5
4	1
K-wire-osteosynthesis	2
K-wire + external fixation	1
K-wire + ethipins	1
External fixation	1
Primary arthrodesis	2
Fragment extirpation	6
Total	80

heads. Excessive stripping of bone was avoided to preserve the vascular supply. Table 2 gives a survey of all surgical procedures.

In 2/67 patients with screw fixation, we used additional K-wires. Temporary external fixation was done in 12 other patients who had comminuted fractures or to simplify wound care in those with open fractures.

Primary cancellous bone grafts

In 4 patients, a bony defect in the talar neck (2 Hawkins type II and 2 type III) was seen on the preoperative CT-scans. It was filled with a bone graft harvested from the iliac crest in 3 patients and from the ipsilateral tibia in 1.

Complications

2 patients with compression screw fixation of talar neck fractures Hawkins types II and III developed pseudarthrosis. The fractures healed after reoperation using autologous cortico-cancellous bone. In another patient with pseudarthrosis and partial talar necrosis after a Hawkins type II fracture, arthrodesis had to be performed.

In 1 patient, the postoperative follow-up showed a step in 1 articular surface; immediate reoperation was performed.

1/10 open fractures became infected by *Staphylococcus aureus* and 2 infections occurred in patients with closed fractures. They were treated with surgical débridement and antibiotic therapy. In 4 cases, skin necroses could be treated locally without progressing into a deep infection.

Postoperative care

Non-comminuted Hawkins type I and II fractures were treated for 8 weeks with intensive physiotherapy without weight bearing as soon as postoperative swelling had subsided. Hawkins type III and IV fractures usually received a non-weight bearing cast. Radiographic and, in some cases, CT-scan-based follow-up imaging were used to determine the individual postoperative rehabilitation. Full weight-bearing was reached within an average of 12 weeks in patients with a talus fracture alone and within 14 weeks in patients with additional injuries. The duration of the hospital stay averaged 15 (6–38) days in patients with isolated talar fractures ($n = 28$), and averaged 21 (8–66) days in patients with additional fractures ($n = 52$). The duration of the hospital stay was particularly long in patients with polytrauma, those developing postoperative infections or in cases of delayed wound healing, but it was also affected by the type of Marti/Weber fracture (isolated Marti/Weber type I fractures: 9 days; type II: 11 days; type III 17 days; type IV: 26 days).

The duration of sick leave averaged 7 (0.5–24) months for the entire study population.

Follow-up

The average postoperative follow-up was 6 (1–15) years. All patients underwent a standardized clinical follow-up examination. They were asked about persistent accident-related complaints and the effect on their professional careers. Radiographs of the ankle joint were done in two projections. The Hawkins (1970) score, based on criteria such as pain, presence of limping, and range of motion in the ankle and subtalar joint, and the Mazur et al. (1979) functional score (based on pain, patterns of walking, walking distance, walking aids and mobility of the ankle joint where the most important variable is pain with a maximum impact of 50 of 100 total points) were used for the final assessment of treatment.

Results

Joint function

The range of motion of the ankle joint was normal in 18 patients and of the subtalar joint in 19 (Table

Table 3. Range of motion of the ankle and subtalar joint depending on severity of fracture, according to the Marti/Weber classification (Marti 1978, Grob et al. 1985, Sanders 1999)

Marti/Weber type of fracture and prevalence	Mobility of the ankle joint			Mobility of the subtalar joint		
	free	limited	complete loss	free	limited	complete loss
Type I (n 15)	7	8	–	7	7	1
Type II (n 14)	5	8	1	3	10	1
Type III (n 32)	4	27	1	8	22	2
Type IV (n 19)	2	8	9	1	7	11
Total (n 80)	18	51	11	19	46	15

3). With an increase in the severity of the fracture, the subsequent postoperative joint mobility was

reduced (Figure 1). The range of motion in the ankle and subtalar joints was lost, especially in patients with Marti/Weber fractures types III and IV. Complete loss of joint mobility was seen in 1 ankle and 8 subtalar joints apart from the 10 ankle and 7 subtalar joints in which an arthrodesis was performed.

Complaints

19/79 patients were very satisfied with the outcome at the follow-up. 33 patients were mostly satisfied, and 17 moderately satisfied,

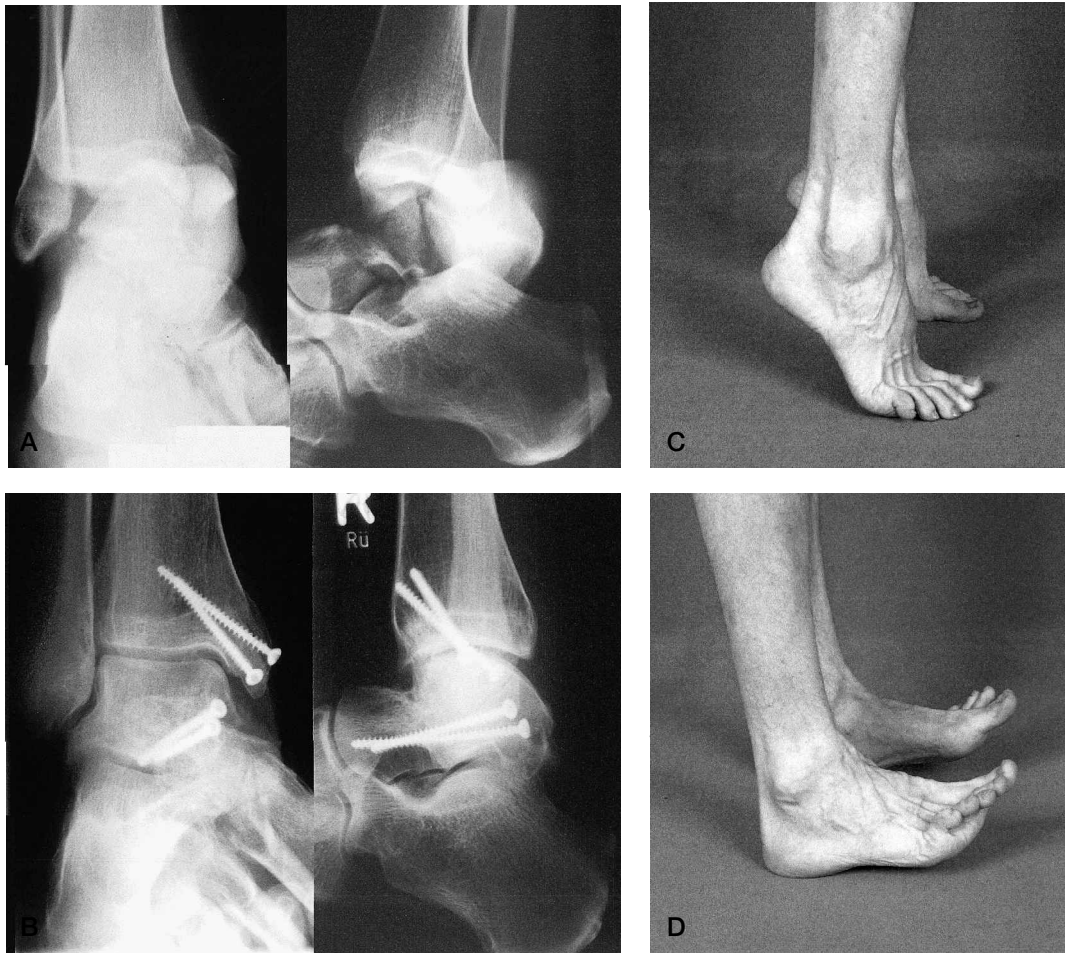

Figure 1. A. Primary open defect fracture of the talar neck Hawkins type III and a medial malleolus fracture. B. 5 years after accident. C and D. Free range of motion in ankle and subtalar joints. Good results according to the Hawkins (12 of 15 points) and Mazur scores (89 of 100 points).

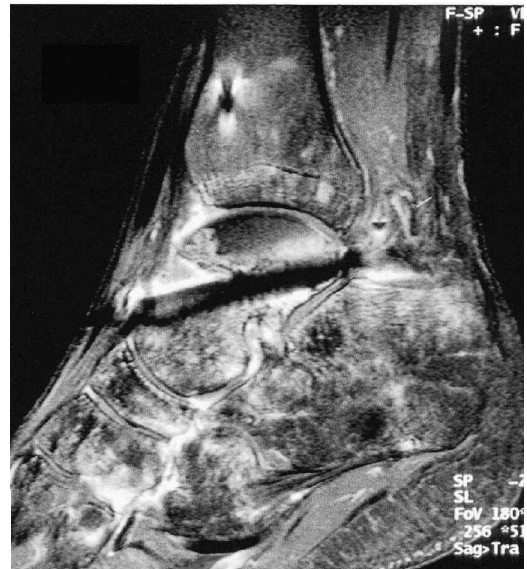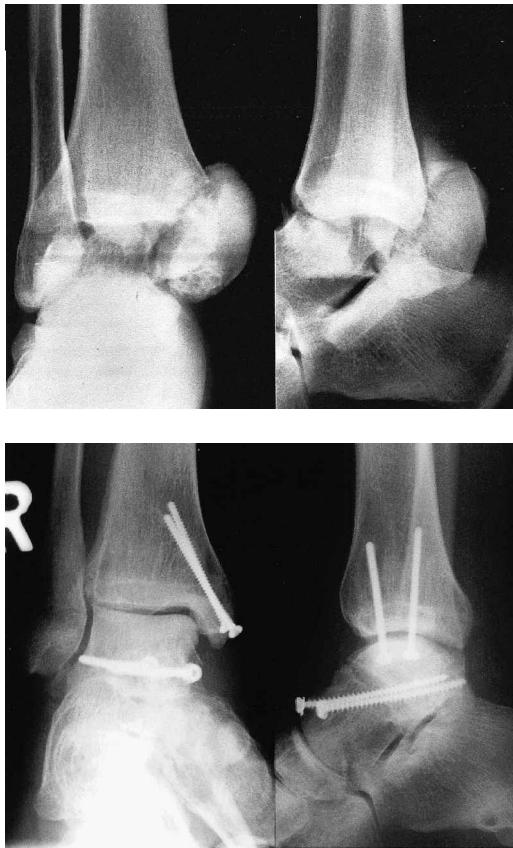


Figure 2. A. Hawkins type III talar neck fracture shows dorsal luxation of the corpus tali and a medial malleolus fracture.

B. 13 months after osteosynthesis using continuous threaded screws for the talar and medial malleolus. Talar corpus necrosis can be seen in both projections with no sign of fracture consolidation.

C. 13 months after osteosynthesis MRI scan using intravenous gadolinium shows talar trochlea necrosis in the presence of the osteosynthesis material. The previous fracture line is still visible.

but 10 patients were not.

Only 19 patients had no pain, 50 had pain after sports or walking longer distances. 5 complained of pain after walking short distances or at rest. 5 patients used continuous and 15 occasional NSAID medication. 6/11 patients with an arthrodesis had no pain. The remaining 4 patients with a Marti/Weber type IV talar fracture and one with a type III fracture reported pain after walking short distances.

Posttraumatic arthrosis

25 patients did not develop arthrosis. They had a median of 87 points on the Mazur score, as compared to 74 points in those with arthrosis and 11 versus 8.2 points on the Hawkins score. However, 13/25 patients with no arthrosis reported strain-related pain and 2 after walking. 11 patients had arthrosis in the ankle joint, 14 in the subtalar joint alone and 28 in both joints. We found a correlation between the radiographic findings of arthrosis and

both the severity of the fracture, using the Marti/Weber classification ($p = 0.003$), and as exercise-induced pain ($p = 0.04$). The patient's age at the time of injury, duration of follow-up or concomitant injuries of the ankle joints did not significantly affect the development of arthrosis.

Avascular talar necrosis

Talar necrosis occurred in 9/80 fractures (Figure 2). The patient with bilateral Hawkins type III fractures developed bilateral necrosis. In 7 cases, partial necrosis of the talar corpus occurred, but 2 of them developed necrosis of the body. 9/65 central fractures and 8/46 neck fractures developed necrosis, but none of those with undisplaced Marti/Weber type I and II fractures, or Hawkins type I fractures did.

Functional outcome (Table 4)

35/80 patients attained good and very good joint function on the Hawkins score and 43/80 patients

Table 4. Results of treatment of Marti/Weber type fracture (Marti 1978, Grob et al. 1985, Sanders 1999), as assessed by the Hawkins and Mazur scores

	Marti/Weber type of fracture				Total (n 80)
	I (n 15)	II (n 14)	III (n 32)	IV (n 19)	
<i>Hawkins score</i>					
Very good	5	3	5	1	14
Good	3	5	9	4	21
Fair	4	5	11	5	25
Poor	3	1	7	9	20
Mean score	11	10	9.0	7.0	8.9
<i>Mazur score</i>					
Very good	6	3	7	1	17
Good	5	7	10	4	26
Satisfactory	1	2	7	5	15
Poor	3	2	8	9	22
Mean score	80	79	74	67	77

on the Mazur score. However, with an increase in severity of the fracture, the mean score decreased. Whereas 11/15 patients with Marti/Weber I fractures regained good and very good joint function according to the Mazur score, only 5/19 patients with a Marti/Weber IV fracture showed a similar satisfactory functional outcome. Using the Mazur score, the functional outcome of almost half of the patients with a type IV fracture was unsatisfactory.

Arthrodeses

Arthrodeses had to be performed in 11/80 patients. In 2 patients with a comminuted fracture, reconstruction of the joint surface was impossible and primary arthrodesis of the ankle and subtalar joint had to be done. Secondary arthrodesis was necessary because of persistent pain and was done an average of 18 (6–36) months after the primary operation. 6/9 secondary arthrodeses were performed in patients with talar necrosis. All patients had severe arthrosis at the time of arthrodesis. The arthrodeses involved the ankle joint in 3 patients, the ankle and subtalar joints in 5, and the talonavicular joint in 1.

Discussion

In our opinion, non-operative management should

be used solely for undisplaced talar fractures. However, undisplaced talar neck fractures can also be treated with percutaneous screw fixation. Unlike non-operative treatment, osteosynthesis permits early mobilization of the joint (Hausel 1980, Szyszkowitz et al. 1985). Undisplaced central fractures may benefit from surgery, see below. Surgery for displaced fractures consists of anatomically correct reconstruction to avoid articular surface incongruence and angular deformity as well as preservation and rapid restoration of talar blood supply. This permits removal of small fragments, exact anatomic reconstruction of the articular surface under visual, digital and fluoroscopic control and is the best way to avoid posttraumatic arthrosis which in many cases necessitates secondary arthrodesis. Immediate reduction of fracture-dislocations is essential to preserve talar blood supply and avoid secondary soft tissue edema with reduced capillary perfusion. Hence, careful closed fracture reduction should be attempted as early as possible during assessment in the emergency room (Hausel 1980, Kuner and Lindenmaier 1983, Kundel et al 1995, Frawley et al. 1995).

The surgical approach also avoids talar necrosis. Since most fractures are located in the talar neck, the antero-medial approach is usually preferred. If an additional medial malleolus osteotomy is necessary, the vascular supply of the medial aspect of the talus via the dorso-medial joint capsule ligament must be preserved. If exact fracture reduction is assured, a postero-lateral or -medial approach should be attempted in proximal fractures of the talar corpus or of the posterior process because of its biomechanical advantages and minimal effect on vascular supply (Ebraheim et al. 1996). Depending on the location of the fracture, other or additional surgical approaches may be used. To ensure interfragmentary compression, we used titanium small fragment cancellous screws with short or medium-length threads in most patients. Good results have also been reported with Herbert screws (Mallon et al. 1989). It remains to be seen whether biodegradable implants (Kankare and Rokkanen 1998) are an alternative and which side effects should be expected (Yoshino et al. 1998). Arthroscopic treatment of talar fractures and talar necrosis is still indicated in a few exceptional cases only (Resch et al. 1992, Saltzmann et al. 1994, Baena et al. 1997).

9/65 central fractures and 8/46 neck fractures developed necrosis, which is a lower incidence than that reported by Hawkins (1965), Canale and Kelly (1978), Penny and Davis (1980), Dunn et al. (1966) or Frawley et al. (1995). The low rate of secondary talar necrosis confirms the importance of early fracture reduction and interfragmentary compression to reduce the rate of collapse of the talar corpus, as stressed by the German AO group (Kundel et al. 1995). We therefore performed osteosynthesis in undisplaced central fractures (Marti/Weber II or Hawkins I).

Some authors recommend primary arthrodesis in fracture-dislocations (Weber 1981), which sacrifices the ankle and subtalar joint. However, we and other authors do not agree with this approach (Beck 1991, Dávid et al. 1996, Schulze et al. 1998).

Secondary arthrodesis may be indicated in patients who develop painful arthrosis secondary to necrosis or articular surface incongruence, but our study confirms that, despite early radiographic evidence of arthrosis, several patients did not develop severe symptoms until much later (Isay et al. 1992). The site and number of joints for surgical arthrodesis must be decided in each individual case. In patients with avascular necrosis, the vascular supply to the talar head is usually sufficient to permit the Chopart joint to remain intact and a pantalar arthrodesis, which is functionally undesirable, can be avoided. If the talus trochlea is affected by osteonecrosis, an arthrodesis can be limited to the ankle joint and obviate a tibio-calcaneal arthrodesis.

The overall functional results in our patients are encouraging, with 52/79 mostly or entirely satisfied.

No funds have been received to support this study.

We thank Uwe Tigör, New York, for help in preparing this study.

Baena A E, Arévalo R L, Robledo J A M, de Llano A Q, De Santos F J. Partial necrosis of the neck of the talus treated with arthroscopy. *Arthroscopy* 1997; 13: 245-7.

Baumhauer J F, Alvarez R G. Controversies in treating talus fractures. *Foot Ankle* 1995; 26 (2): 335-51.

Beck E. Die Talusfraktur. *Orthopäde* 1991; 20: 33-42.

Canale S T, Kelly F B. Fractures of the neck of the talus. *J Bone Joint Surg (Am)* 1978; 60: 143-56.

Dávid A, Muhr G, Möllenhoff G. Talusfrakturen - Therapie und Ergebnisse. In: *Das obere Sprunggelenk - Angeborene und erworbene Schäden* (Ed. Stahl Ch). ecomed 6. Fortschritte in Orthopädie und Traumatologie, Landsberg/Lech 1996: 103-4.

Dunn A R, Jacobs B, Campbell R D. Fractures of the talus. *J Trauma* 1966; 6: 443-68.

Ebraheim N A, Mekhail A O, Salpietro B J, Mermer M J, Jackson B A, Jackson W T. Talar neck fractures: Anatomic considerations for posterior screw application. *Foot Ankle* 1996; 17: 541-5.

Frawley P A, Hart J A, Young D A. Treatment outcome of major fractures of the talus. *Foot Ankle* 1995; 16: 339-45.

Grob D, Simpson L, Weber B G, Bray T. Operative treatment of displaced talus fractures. *Clin Orthop* 1985; 199: 88-96.

Gustilo R B, Anderson J T. Prevention of infection in the treatment of one thousand and twenty-five open fractures of long bones: retrospective and prospective analyses. *J Bone Joint Surg (Am)* 1976; 58: 453-8.

Haase T, Meeder P J, Ranzelzhofer B, Weller S. Aseptische Komplikationen nach Talusfrakturen - Therapie und Prophylaxe. *Akt Traumatol* 1995; 25: 182-5.

Hausel M. Ergebnisse bei der operativen Behandlung von Talusfrakturen. *Krankenhausarzt* 1980; 53: 415-22.

Hawkins L G. Fracture of the lateral process of the talus. *J Bone Joint Surg (Am)* 1965; 47: 1170-5.

Hawkins L G. Fractures of the neck of the talus. *J Bone Joint Surg (Am)* 1970; 52: 991-1002.

Isay M, Wolvius R, Ochsner P E. Langzeitergebnisse nach Talusfrakturen. *Z Unfallchir Vers med* 1992; 85: 12-8.

Kankare J, Rokkanen R. Dislocated fractures of the talus treated with biodegradable internal fixation. *Arch Orthop Trauma Surg* 1998; 117: 62-4.

Kundel K, Braun W, Scherer A. Spätergebnisse nach zentralen Talusverletzungen. *Unfallchirurg* 1995; 98: 124-9.

Kuner E H, Lindenmaier H L. Zur Behandlung der Talusfraktur. *Unfallchirurgie* 1983; 9: 35-40.

Kuner, E H, Muller, T H, Lindenmaier, H L. Einteilung und Behandlung der Talusfrakturen. *Hefte zur Unfallheilkunde* 1978; 131: 197-211.

Mallon W J, Wombwell J H, Nunley J A. Intra-articular talar fractures: Repair using the Herbert Bone Screw. *Foot Ankle* 1989; 10: 88-92.

Marti R. Talus- und Calcaneusfrakturen. In: *Frakturbehandlung bei Kindern und Jugendlichen* (Eds. Weber B G, Brunner C, Freuler F). Springer, Berlin Heidelberg New York 1978: 376-87.

Mazur J M, Schwartz E, Simon S R. Ankle arthrodesis. Long-term follow-up with gait analysis. *J Bone Joint Surg (Am)* 1979; 61: 964-75.

Müller K H. Talusfrakturen - Ergebnisse Bochum. In: *Verletzungen des oberen Sprunggelenks* (Eds. Burri C, Rüter A). *Hefte zur Unfallheilkunde* 1978; 131: 218-25.

Penny J N, Davis L A. Fractures and fracture-dislocation of the neck of the talus. *J Trauma* 1980; 20: 1029-37.

- Resch H, Kathrein A, Golser K, Sperner G. Arthroskopische und perkutane Verschraubungstechniken mit einem neuen Verschraubungssystem. *Unfallchirurg* 1992; 95: 91-8.
- Saltzman C L, Marsh J L, Tease D S. Treatment of displaced talus fractures: An arthroscopically assisted approach. *Foot Ankle* 1994; 15: 630-3.
- Sanders R. Fractures and fracture-dislocations of the talus. In: *Surgery of the Foot and Ankle* (Eds. Coughlin M J, Mann R A). Mosby, St. Louis 1999; 7: 631-46.
- Schulze W, Richter J, Klapperich T, Muhr, G. Funktionsergebnisse nach operativer Therapie von Talusfrakturen. *Chirurg* 1998; 69: 1207-13.
- Szyszkowitz R, Reschauer R, Seggl W. Eighty-five talus fractures treated by ORIF with five to eight years of follow-up of 69 patients. *Clin Orthop* 1985; 199: 97-107.
- Weber B G. Brüche von Knöcheln und Talus. Bewährtes und Neues in Diagnostik und Therapie. *Langenbecks Arch Chir* 1981; 355: 421-5.
- Yoshino N, Takai S, Watanabe Y, Kamata K, Hirasawa Y. Delayed aseptic swelling after fixation of talar neck fracture with a biodegradable poly-L-lactide rod: Case reports. *Foot Ankle* 1998; 19: 634-7.