

Case reports

An unusual variant of fracture through the capitate bone—a case report

Lars B Dahlin¹ and Jack Besjakov²

Departments of ¹Hand Surgery and ²Radiology, Malmö University Hospital, SE-205 02 Malmö, Sweden. E-mail: Lars.Dahlin@hand.mas.lu.se
Submitted 01-04-21. Accepted 01-09-06

A 31-year-old right-handed man had a hyperextension trauma to the right wrist when he fell off a motorbike in July 1999. Initial plain radiographs were normal. Since a scaphoid fracture was suspected, a cast was applied. After 2.5 weeks, new plain radiographs with special projection of the scaphoid again showed no fracture; he still had wrist pain, but returned to ordinary work.

The patient was referred to our department in September 1999 due to persistent pain. The range of wrist motion, including pro- and supination, was normal. He had slight pain on palpation around the scaphoid, but no definite pain in the snuff box. Watson's test, LT-test and Lichtman's test were all negative. No signs of median nerve compression were found. A bone scintigram (Figure 1) showed increased uptake at the site of the capitate bone with an intensity reminiscent of a fracture. MRI of the right wrist in November 1999 showed slight

edema in the bone marrow of the capitate and dorsal to the bone and a fracture in the capitate bone that divided the bone into a ventral and a dorsal portion, but no dislocation of the fracture (Figure 2). The patient was given a splint. On a follow-up with computed tomography (CT) of the right wrist and plain radiographs in March 2000 (Figure 3), he had slight sclerosis in the middle of

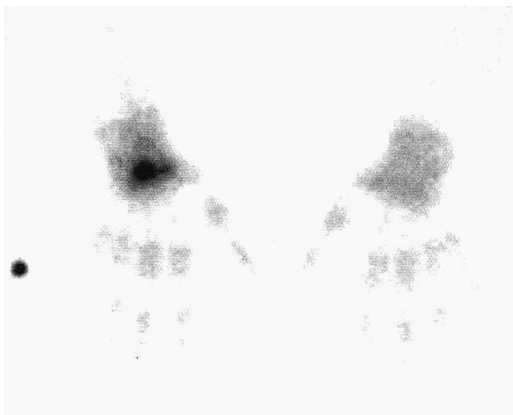


Figure 1. Bone scan showing an increase in uptake at the location of the capitate with the intensity of a suspected fracture.

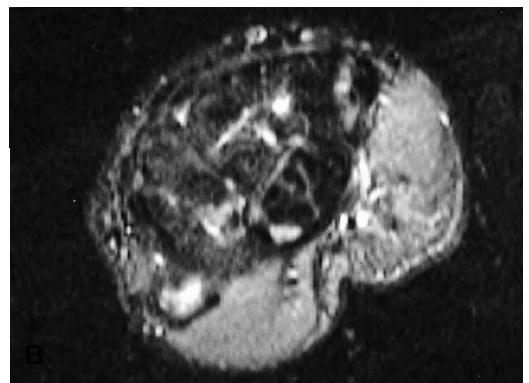
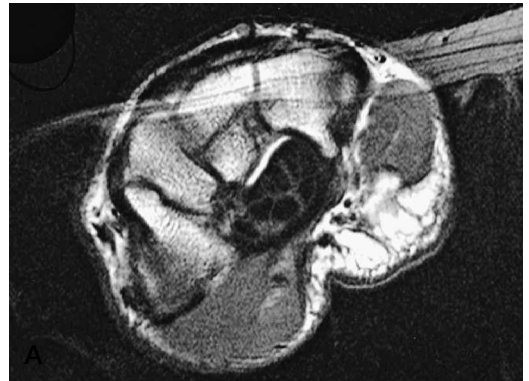

Figure 2. Axial T1-weighted (A) and inversion recovery (B) MR images show an undisplaced fracture in the capitate bone that divides the bone into a ventral and a dorsal portion.

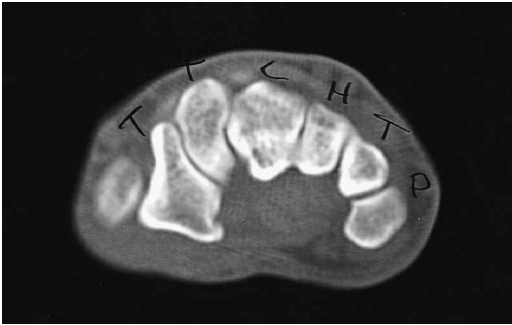

Figure 3. An axial CT scan confirms that the capitatum fracture has healed with no dislocation. A linear band of sclerosis is seen in the capitatum bone (c = capitatum bone).

the capitatum (plain radiograph), but both investigations showed that the fracture had healed without dislocation. The cartilage in the right wrist had a normal appearance. At a second follow-up in May 2000, the patient had normal motion, good grip strength and no pain.

Discussion

An isolated capitatum fracture creating a volar and a dorsal segment of the capitatum without dislocation is rare (Adler and Shaftan 1962, Kuderna 1986, Albertsen et al. 1999). Isolated capitatum fractures comprise up to 1.3% of carpal fractures (Rand et al. 1982). They may be underdiagnosed because little, if any, dislocation of the fracture segments may occur due to fixation by the intracarpal ligaments (Calandruccio and Duncan 1999). Various mechanisms of such an injury to the capitatum bone have been described, including a fall on an outstretched hand which results in forced extension of the ulnar deviated or neutrally-positioned wrist (Fenton and Rosen 1950, Adler and Shaftan 1962). In our patient, two plain radiographic examinations showed no fracture, which is common in cases of an isolated capitatum fracture (Albertsen et al. 1999, Calandruccio and Duncan 1999). However, MRI, CT, and bone scans are useful for diagnosing isolated wrist fractures (Hopkins and Ammann 1990, Albertsen et al. 1999, Bretlau et al. 1999, Calandruccio and Duncan 1999, Rayan 1994, Schick et al. 1999). Albertsen et al. (1999) described a similar fracture, but that fracture was seen even

on the plain radiograph. However, they gave no information about the follow-up. In the report of Kuderna (1986), an oblique dorsal fracture was combined with dorsal displacement of the third metacarpal bone. Such a dislocation is common in patients with fracture-dislocations of the fourth and fifth metacarpal bones together with a hamate fracture of varying severity.

Our patient had persistent pain which later disappeared and the follow-up with CT showed that the fracture had healed. Persistent pain in the wrist can be caused by an occult capitatum fracture which does not heal. Nonunion (pseudoarthrosis) of an isolated capitatum fracture is rare (Rayan 1994, Rico et al. 1999) and may require surgery with use of a cancellous bone graft (Rico et al. 1999).

Posttraumatic carpal arthrosis may occur late after capitatum fractures (Rand et al. 1982). So far our patient has shown no signs of posttraumatic carpal arthrosis, but we plan to follow him for a long time.

- Adler J B, Shaftan G W. Fractures of the capitatum. *J Bone Joint Surg (Am)* 1962; 44: 1537-47.
- Albertsen J, Mencke S, Christensen L, Teisen H, Hjarbæk J. Isolated capitatum fracture diagnosed by computed tomography. Case report. *Handchir Mikrochir Plast Chir* 1999; 31 (2): 79-81.
- Bretlau T, Christensen O M, Edstrom P, Thomsen H S, Lausten G S. Diagnosis of scaphoid fracture and dedicated extremity MRI. *Acta Orthop Scand* 1999; 70 (5): 504-8.
- Calandruccio J H, Duncan S F. Isolated nondisplaced capitatum waist fracture diagnosed by magnetic resonance imaging. *J Hand Surg (Am)* 1999; 24 (4): 856-9.
- Fenton R L, Rosen H. Fractures of the capitatum bone. Report of two cases. *Bull Hosp Joint Dis* 1950; 11: 134-9.
- Hopkins S R, Ammann W. Isolated fractures of the capitatum: use of nuclear medicine as an aid to diagnosis. *Int J Sports Med* 1990; 11 (4): 312-4.
- Kuderna H. Frakturen und Luxationsfrakturen der Handwurzel. *Orthopade* 1986; 15 (2): 95-108.
- Rand J A, Linscheid R L, Dobyns J H. Capitatum fractures: a long-term follow-up. *Clin Orthop* 1982; 165: 209-16.
- Rayan G M. Occult wrist pain due to capitatum nonunion. *South Med J* 1994; 87 (3): 402-4.
- Rico A A, Holguin P H, Martin J G. Pseudarthrosis of the capitatum. *J Hand Surg (Br)* 1999; 24 (3): 382-4.
- Schick S, Trattinig S, Gabler C, et al. Okkulte Handgelenkfrakturen: Feinfokusvergrößerungsrontgen versus MRT. *Fortschr Röntgenstr* 1999; 170(1): 16-21.