

The Weil osteotomy for treatment of dislocated lesser metatarsophalangeal joints

Good outcome in 21 patients with 42 osteotomies

Hans-Jörg Trnka¹, Christoph Gebhard², Michaela Mühlbauer¹, Gerd Ivanic¹ and Peter Ritschl¹

Departments of Orthopaedic, ¹Hospital Gersthof, Wielemanngasse 28, AT-1180 Vienna Austria, ²General Hospital, St. Pölten, Austria
E-mail: hans4hallux@aon.at
Submitted 00-05-23. Accepted 01-08-02

ABSTRACT – Hardly any surgical methods are available for metatarsalgia caused by a dislocated lesser metatarsophalangeal joint (MTP) that do not sacrifice the joint. We reviewed retrospectively the outcome of 60 metatarsal Weil osteotomies for correction of dislocated lesser MTP joints in 31 patients.

Between 1995 and 1996, 31 consecutive patients were treated with a Weil osteotomy at 2 institutions. The Weil osteotomy is an oblique osteotomy of the metatarsal neck and shaft, parallel to the ground surface, that controls shortening of the metatarsal by internal fixation with screws or pins. At an average final follow-up of 30 (24–44) months, all patients were interviewed, using a standardized questionnaire based on the AOFAS Lesser Metatarsophalangeal-Interphalangeal Scale. Recurrent or transfer metatarsalgia, formation of callus, mobility and dislocation of the MTP were noted on physical examination. Dorsoplantar and lateral weightbearing radiographs taken preoperatively and at the time of final follow-up were examined for alignment of the metatarsal heads, subluxation or dislocation and for evidence of nonunion, or malunion of the metatarsal osteotomy.

We had excellent results in 21 patients (42 osteotomies). A major complication was plantar penetrating hardware in 10 cases (3 screws and 7 pins).

We conclude that the Weil osteotomy is a good method for correcting metatarsalgia caused by dislocation of the MTP joint.

■

Subluxation or dislocation of one of the lateral MTP joints is common. Although the first cases

were described by Branch as early as 1937, only a few reports have been published about the treatment of this deformity (Thompson and Hamilton 1987, Cracchiolo et al. 1988, Coughlin 1989, Daly and Johnson 1992).

The strong extension forces in the MTP joint of the extensor digitorum longus and brevis are partly antagonized by the interosseous and lumbrical muscles and stabilized by the plantar plate. This plate, formed by the plantar aponeurosis and the plantar joint capsule, plays a major role in dorsoplantar stability of the MTP joint (Bhatia et al. 1994, Johnston et al. 1994). Once the plate deteriorates, there are no major antagonists for the extensors, and the proximal phalanx is inevitably pulled dorsally out of the joint. This leads to contracture of the extensors, elongation and rupture of the plantar structures, and finally dislocation of the joint.

Nonsurgical treatment, like modifications of shoes, metatarsal pads, and custom orthoses may help to relieve the symptoms initially, but can not correct a dislocation. Surgical options include dorsal soft tissue release with pin-fixation (Scheck 1968, Thompson and Hamilton 1987, Coughlin 1989), silicone implants (Cracchiolo et al. 1988), metatarsal neck osteotomies (Helal 1975, Helal and Greiss 1984, Trnka et al. 1996) and MTP joint excisional arthroplasties (DuVries 1956). Weil devised a joint preserving, intraarticular shortening osteotomy, first reported by Barouk (1996).

We present our results with the Weil procedure for correction of the dislocated lesser MTP joint(s),

Table 1. Clinical data

	Weil	n
Number of patients	31	
Age	60 (25–78)	
Sex	29 women / 2 men	
Length of follow-up	30 (24–44) months	
<i>Previous procedures</i>		
Keller-Brandes		4
Scarf osteotomies		5
Austin		2
<i>Additional simultaneous procedures</i>		
Scarf osteotomies		12
Distal metatarsal osteotomies		3
Basal metatarsal osteotomies		2
Tendon lengthening		3
Hohmann		2
1st MTP arthrodesis		1
<i>Locations of 60 Weil osteotomies</i>		
Second metatarsal		29
Third metatarsal		16
Fourth metatarsal		13
Fifth metatarsal		2

with special attention to transfer lesions and recurrent metatarsalgia.

Patients and methods

31 patients (29 women) who had undergone a Weil osteotomy for dislocated MTP joints at two institutions from 1995 to 1996 formed the study group (Table 1). An inclusion criterion was a painful dislocation of the MTP joint. We excluded patients with neurological disorders and rheumatoid arthritis. Before surgery, all patients had been treated with modifications of shoe wear, custom-made inlays, and metatarsal paddings for at least 6 months before they were referred to our tertiary care orthopedic hospital for evaluation and possible surgical correction.

The average age and duration of follow-up of these patients were 60 (25–78) years and 30 (24–44) months, respectively. 60 osteotomies were performed.

Surgical method (Figure 1)

All operations were done under regional ankle anesthesia and tourniquet control. A 3 cm longitu-

dinal incision was made over the metatarsal for a single osteotomy, over the web space for a double osteotomy, or over the central metatarsal for a triple osteotomy. After identifying the metatarsal head and neck, the joint-capsule was incised. The collateral ligaments of the MTP joint were cut, the dislocation of the MTP joint partly reduced and the toe plantarflexed to expose the metatarsal head. The plane of the osteotomy was parallel to the plantar surface, from the dorsal portion of the metatarsal head proximally. The plantar fragment was shifted proximally to obtain the shortening that was measured preoperatively on the dorsoplantar radiographs. The amount of shortening, from 3–8 mm, was based on the length of the involved and adjacent metatarsals, and the severity of the dislocation. The osteotomy was secured with a 1.2 threaded K-wire in 3 patients (7 metatarsals) or a special 2 mm titanium “Twist-off screw” (DePuy) in 53 metatarsals. The resulting dorsal protuberance over the metatarsal head remnant was removed. Weightbearing with a postoperative shoe was allowed after the second postoperative day.

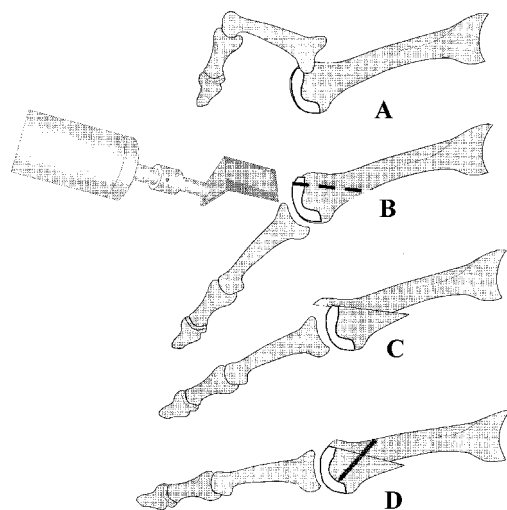


Figure 1. The Weil osteotomy.

A. Dislocated lesser metatarsophalangeal joint.

B. The toe is plantarflexed and an osteotomy parallel to the ground surface from the dorsal portion of the metatarsal head proximally was performed.

C. The plantar fragment is shifted proximally for shortening.

D. The osteotomy is fixed with a special twist-off screw and the resulting protuberance is removed.

Table 2. Results

	Weil
Score on LMIS ^a	81 SD 25.3 (52–100)
No pain	21 patients
Recurrent metatarsalgia	6 patients
Transfer metatarsalgia	0
Subluxation or dislocation at follow-up	8
Pseudarthrosis	0

^a Lesser Metatarsophalangeal-Interphalangeal Scale (Kitaoka et al. 1994)

Radiographic assessment

Dorsoplantar and lateral weightbearing radiographs taken preoperatively and at the time of final follow-up were examined for alignment of the metatarsal heads and subluxation or dislocation of the MTP joint. At final follow-up, nonunion, malunion, and shortening of the metatarsal were evaluated radiographically.

Clinical assessment

At the final follow-up, patients were interviewed, using a standardized questionnaire (Trnka et al. 1996) based on the AOFAS Lesser Metatarsophalangeal-Interphalangeal Scale (LMIS) (Kitaoka et al. 1994). Points were assigned for clinical parameters including pain (40), functional restriction (15), restriction of footwear (10), tender and painful callus (10), alignment (5), and stiffness of the MTP joint (5). In addition to the formal survey, patients were asked about functional outcome and, separately, about the cosmesis, using scales graded 1 (excellent) to 4 (poor). Finally, we noted the presence or absence of recurrent or transfer metatarsalgia, formation of callus, and subluxation or dislocation of the MTP joint on physical examination

Results

Clinical results

21 patients had excellent results, 4 good, 2 fair and 4 patients were dissatisfied with the outcome of treatment. In all dissatisfied patients, K-wires or a screw had penetrated the soft tissue on the plantar side of the foot and caused pain. The screws

were removed in 2 patients, the third refused revision surgery and was successfully treated with an orthotic support, and in the fourth patient, 3 migrating threaded K-wires had to be removed. The median score of the AOFAS LMIS was 81 (52–100) points (Table 2). 21 patients had no pain, 5 had mild pain, 3 moderate, and 2 had persistent and severe pain, because of screw penetration. The cosmetic appearance was excellent in 19 patients, good in 11, and fair in 1 patient. An asymptomatic callus below the operated metatarsal heads was seen below 16 metatarsals (6 patients) and below one adjacent metatarsal head. Metatarsalgia not associated with metatarsal callosity was noted in 6 patients due to plantar prominence of a screw or K-wires in 9 MTP joints. There was no case of transfer metatarsalgia to an adjacent non-operated metatarsal.

Radiographic findings (Figure 2)

We had no patient with malunion or pseudarthrosis. 8 joints were still dislocated. Shortening of the metatarsals was obtained in all cases. Accurate measurements of shortening could not be made because the radiographs had not been taken in the same institution preoperatively and at follow-up.

Complications

3 patients with delayed healing of the wound after 3–4 weeks had had an osteotomy of the second, third and fourth metatarsals. In 3 metatarsals, a plantar perforation of the screw, and in 7 metatarsals, a migrating threaded K-wire caused pain. Two of the screws and all migrated K-wires had to be removed.

Discussion

Helal and Greiss (1984) suggested that shortening of the metatarsal without touching the joint capsules would allow passive correction of the subluxation or dislocation. Mulier et al. (1994) and Winson et al. (1988) found that this is not correct. In a previous study, Trnka et al. (1999) reviewed the correction of subluxed or dislocated MTP joints treated with the Helal osteotomy and the Weil osteotomy. After the Helal procedure, only 8/21 MTP joints were reduced, but 21/25 subluxed or dislo-

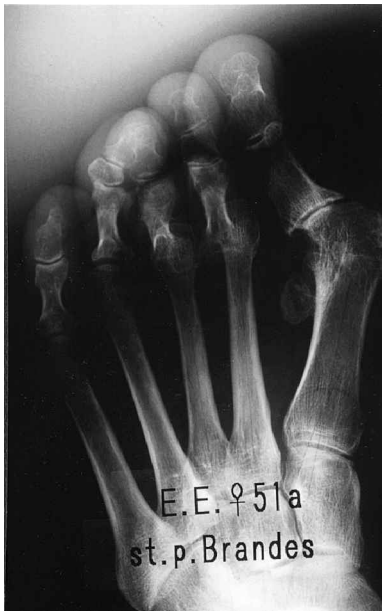
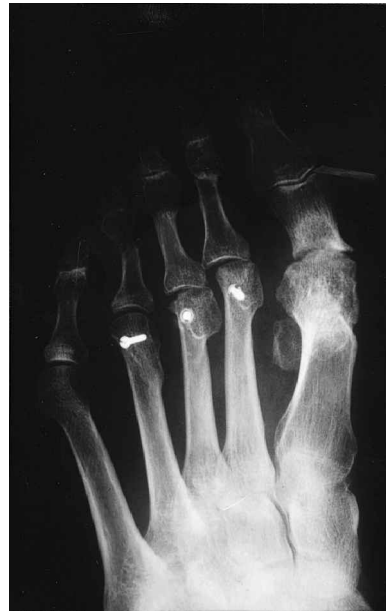
Figure 2. A. A 51-year-old woman, 10 years after a Keller-Brandes procedure. Severe painful dislocation of the 2nd and 3rd MTP joints, and re-valgus deformity.



B. The same patient at the 2-year follow-up. A Chevron osteotomy with a Keller-Brandes revision had been performed in addition to the Weil osteotomy 2-4. She has no pain.

cated MTP joints were reduced after a Weil osteotomy.

Cracchiolo et al. (1988) reported their results of treating dislocated lesser MTP joints with silicone implant arthroplasty. Preoperatively 23 of 32 MTP joints were diagnosed as dislocated and correction was obtained in 5 of 32 at follow-up.

Helal and Greiss (1984) noted successful reduction of pain in 88%, but this has not been confirmed by others. Winson et al. (1988) obtained good pain reduction in 47%, and Mulier et al. (1994) had good results in only 50%. Daly and Johnson (1992) reported persistent pain in 28% after resection of the proximal base of the phalanx and syndactylization.

We have abandoned the K-wires for fixation of the Weil osteotomy, and recommend the "Twist-off" screw for fixation of the osteotomy. Most of the available mini fragment screws need predrilling, which may dislocate the plantar fragment. The so-called "Twist-off" screw is used without predrilling. Other methods for correction of dislocated lesser MTP joints showed a higher rate of complications. Cracchiolo et al. (1988) reported unsatisfactory results in 26/32 cases, and Daly and Johnson (1992) found that 43/60 operated patients had

some complaints. After the Helal osteotomy, nonunion and metatarsalgia are the commonest complications. Schmidt and Becker (1989) had 19% nonunions, and Helal (1975), Winson et al. (1988), and Mulier et al. (1994) reported 15%, 14%, and 7% nonunions, respectively. Trmka et al. (1999) noted transfer metatarsalgia in 11/15 feet using the Helal osteotomy.

After excisional arthroplasty, where parts of the articular cartilage are resected, some degree of arthrofibrosis at the MTP joint usually occurs (Coughlin 1989). With the Weil osteotomy, decompression of the MTP joint is obtained by shortening without sacrificing the cartilage. Although the range of motion of the MTP joint is reduced, it is better than after excisional arthroplasty.

No funds have been received to support this study.

Barouk L S. Die Metatarsalosteotomie nach Weil zur Behandlung der Metatarsalgie. *Orthopade* 1996; 2531: 388-44.

Bhatia D, Myerson M S, Curtis M J, Cunningha, B W, Jinnah R H. Anatomical restraints to dislocation of the second metatarsophalangeal joint and assessment of a repair technique. *J Bone Joint Surg (Am)* 1994; 76: 1371-5.

- Branch H E. Pathological dislocation of the second toe. *J Bone Joint Surg (Am)* 1937; 37: 978-84.
- Coughlin M J. Subluxation and dislocation of the second metatarsophalangeal joint. *Orthop Clin North Am* 1989; 20: 535-51.
- Cracchiolo A III, Kitaoka H B, Leventen E O. Silicone implant arthroplasty for second metatarsophalangeal joint disorders with and without hallux valgus deformities. *Foot Ankle* 1988; 9: 10-8.
- Daly P J, Johnson K A. Treatment of painful subluxation or dislocation at the second and third metatarsophalangeal joints by partial proximal phalanx excision and subtotal webbing. *Clin Orthop* 1992; 278: 164-170.
- DuVries H L. Dislocation of the toe (Letter to the editor). *JAMA* 1956; 160: 728.
- Helal B. Metatarsal osteotomy for metatarsalgia. *J Bone Joint Surg (Br)* 1975; 57: 187-92.
- Helal B, Greiss M. Telescoping osteotomy for pressure metatarsalgia. *J Bone Joint Surg (Br)* 1984; 66: 213-7.
- Johnston R B III, Smith J, Daniels T. The plantar plate of the lesser toes: An anatomical study in human cadavers. *Foot Ankle Int* 1994; 15: 276-82.
- Kitaoka H B, Alexander I J, Adelaar R S, Nunley J A, Myerson M S, Sanders M. Clinical rating systems for the ankle-hindfoot, midfoot, hallux, and lesser toes. *Foot Ankle Int* 1994; 15: 349-53.
- Mulier T, Dereymaeker G, Victor J, Stuer P, Fabry G. Long-term functional results after the Helal osteotomy. *Foot Dis* 1994; 1: 69-77.
- Scheck M. Degenerative changes in the metatarsophalangeal joints after surgical correction of severe hammer-toe deformities. A complication associated with avascular necrosis in three cases. *J Bone Joint Surg (Am)* 1968; 50: 727-37.
- Schmidt K, Becker W. Spreizfussbehandlung mit der Metatarsalosteotomie nach Helal. *Z Orthop* 1989; 127: 322-5.
- Thompson F M, Hamilton W G. Problems of the second metatarsophalangeal joint. *Orthopedics* 1987; 10: 83-9.
- Trnka H J, Kabon B, Zetl R, Kaider A, Salzer M, Ritschl P. Helal metatarsal osteotomy for the treatment of metatarsalgia: a critical analysis of results. *Orthopedics* 1996; 19: 457-61.
- Trnka H J, Mühlbauer M, Zetl R, Myerson M S, Ritschl P. Comparison of the results of the Weil and Helal osteotomies for the treatment of metatarsalgia secondary to dislocation of the lesser metatarsophalangeal joints. *Foot Ankle Int* 1999; 20: 72-9.
- Winson I G, Rawlinson J, Broughton N S. Treatment of metatarsalgia by sliding distal metatarsal osteotomy. *Foot Ankle* 1988; 9: 2-6.