

# The ScanHip<sup>®</sup> total hip arthroplasty

## Radiographic assessment of 72 hips after 10 years

Toshiki Iwase<sup>1,3</sup>, Inga Wingstrand<sup>2</sup>, Björn M Persson<sup>1</sup>, Uldis Kesteris<sup>1</sup>,  
Yukiharu Hasegawa<sup>1,4</sup> and Hans Wingstrand<sup>1</sup>

Departments of Orthopedics, <sup>1</sup>Lund University Hospital, Lund, Sweden, <sup>2</sup>Helsingborg, Sweden, <sup>3</sup>Okazaki City Hospital, Okazaki, Japan, <sup>4</sup>Nagoya University School of Medicine, Nagoya, Japan. E-mail: iwaset@hotmail.com  
Submitted 01-03-24. Accepted 01-07-11

**ABSTRACT** – We analyzed the radiographic and clinical outcome of the ScanHip total hip arthroplasty in 70 patients after 10 years. The Swedish National Hip Register, in which the end-point of the survival analysis is defined as revisions, reported a 10-year survival rate of 94% with the ScanHip, but in the present series 13% of the femoral stems and 29% of the sockets met the criteria for aseptic loosening. Focal osteolysis was found around 8 sockets (11%) and 23 stems (32%) and had occurred significantly oftener around loose sockets, but not around femoral stems. Linear polyethylene wear was significantly increased in loose sockets, but no relationship was noted between polyethylene wear and stem loosening or was there a correlation between clinical symptoms or patients' satisfaction and component loosening. Therefore precise serial long-term radiographic follow-up is the only satisfactory method for detecting aseptic loosening of total hip arthroplasty. It gives the surgeon more detailed information about each case than survival analysis alone.

Long-term survival analysis, with revision as the end-point, is one of the commonest methods for assessing longevity after total hip arthroplasty (Herberts and Malchau 2000, Malchau et al. 2000). Clinical scores or self-assessment by patients are good indicators of the clinical results of the operation, and give the orthopedic surgeon much information.

However, as we will show in this article, these methods are not satisfactory for detecting the post-operative condition of these hips. In previous papers, we reported the survival rate (Kesteris et

al. 1998) and wear of the polyethylene socket of the ScanHip arthroplasty (Kesteris et al. 1996). In the present study, we analyzed the relationships between the radiographic appearance of the components, wear and clinical symptoms 10 years after surgery.

### Patients and methods

From November 1984 to February 1988, 244 hips in 230 patients underwent a primary cemented ScanHip total hip arthroplasty in the Department of Orthopedic Surgery in Helsingborg, Sweden. Of these cases, 72 hips in 70 patients had a complete 10-year radiographic and clinical follow-up. The reasons for exclusion were as follows: 89 patients (95 hips) had died with their original implants within 10 years of surgery; 33 patients (35 hips) declined to attend the follow-up because of other medical problems, not related to hip disease; 10 patients (13 hips) had had revision surgery because of aseptic loosening in 12 hips and periprosthetic fracture in one hip before the 10-year follow-up study; serial radiographs were not available in 28 patients (29 hips).

The average age of the patients who attended the complete 10-year follow-up was 66 (40–86) years. 28 were males (30 hips) and 42 females (42 hips). The average follow-up of these patients was 9 years and 10 months (9 years and 1 month–11 years and 9 months).

The indications for primary surgery had been osteoarthritis in 60 hips, complications of femoral

cervical fracture in 8 and rheumatoid arthritis in 4 hips.

The ScanHip (MitAB, Sweden) femoral component was a non-modular design made of CoCrMo alloy with collar. Although 22 and 32 mm diameter femoral heads for this component were available at that time, only 32 mm diameter heads were used. The cup has no metal backing and is made of machined ultra-high weight molecular polyethylene. This design was introduced in 1983.

The same surgical approach and cementing technique were used in all cases: a posterolateral incision without trochanteric osteotomy, cleaning with pulsating lavage, plugging of the femoral canal, and retrograde filling with Palacos bone cement with gentamicin prepared in a vacuum mixer syringe. No compression handle was used during cementation of the acetabulum, and the so-called “two thumbs method” without any special instruments was applied for pressurization of the femoral cementing before insertion of the implants.

### **Radiographic assessment**

Radiographic measurements were based on anteroposterior conventional radiographs of the pelvis and anteroposterior hip/upper femoral radiographs showing the entire femoral component. These radiographs were taken the day after the operation and at the final follow-up at about 10 years. All radiographic measurements and observations were made by one of the authors (T.I.), who was not participating in surgery at that time and did not know about the patients' clinical condition. Socket wear was measured using Livermore et al.'s method (1990). Each radiographic measurement for socket wear was done twice to the nearest 0.05 mm, using a manual caliper (Kesteris et al. 1996). The measurements were corrected for magnification by comparing the diameter of the femoral head on a radiograph with its actual diameter of 32 mm. This method has an accuracy of 0.075–0.4 mm (Livermore et al. 1990, Bankston et al. 1994).

Radiolucent lines and presence of osteolysis (scalloping changes around the socket or in the femoral cortex) in the cement-bone interface were recorded according to the three acetabular zones of DeLee and Charnley (1976), and the seven femoral zones of Gruen et al. (1979). The axial position of the stem was defined on each anteroposterior

radiograph by extending a line distally along the central axis of the distal part of the stem and determining whether it was parallel (neutral), varus or valgus in relation to the bisecting axis of the medullary canal at the isthmus.

Subsidence of the femoral stem was measured as follows: perpendicular lines were drawn to the bisecting axis of the medullary canal, at the top of the femoral head and at the tip of the great trochanter. The distance between both lines was measured on the initial postoperative and final follow-up radiographs. The difference between these measurements was defined as subsidence of the stem. Ectopic bone formation was recorded, using the classification system of Brooker et al. (1973), and femoral cementing condition was classified with the grading system proposed by Barrack et al. (1992).

Femoral component loosening was divided into two groups with Harris et al.'s method (1982). Definite loosening was defined as stem subsidence  $\geq 5$  mm, shift in the axial position  $\geq 5^\circ$ , cement fracture, or stem fracture. The stem was said to have probable loosening if a continuous radiolucent line at the cement-bone interface, surrounding the entire cement mantle, was seen on an anteroposterior radiograph.

Radiographic findings of sockets were assessed with the method described by Hodgkinson et al. (1988). Cases with type 3 (complete demarcation) or type 4 (socket migration) findings were regarded as aseptic loosening of the acetabular component. Migration of the acetabular component was defined as a tilt of  $\geq 5^\circ$  or a change in position of  $\geq 5$  mm.

### **Clinical assessment**

To correlate radiographic findings with patient satisfaction and clinical symptoms, the patients answered a questionnaire, concerning pain and patient satisfaction administered by one of the authors, a physiotherapist (I.W.), with no prior knowledge of the radiographic findings in the hips. Pain was classified as none (no pain), mild (slight occasional pain; patient has not changed types of activities or work), moderate (patient is active, but has had to modify or give up some activities, or both, because of pain), and severe (much pain and serious limitation). This classification of pain and satisfaction was proposed by Johnston et al. (1990).

## Statistics

Linear wear of sockets, age of the patients, and subsidence of stem were expressed as mean  $\pm$  standard deviation. The 95% confidence interval (CI) was calculated for linear wear of the sockets and subsidence of the stem. Differences in linear socket wear, according to the radiographic findings, and gender of the patients were analyzed with one-way analysis of variance and the Student's t-test. If the distribution of variance was not equal, we used the Mann-Whitney U-test for nonparametric analysis. The relationship between subsidence of the stem and the patients' age, and between linear socket wear and the patients' age were analyzed with Pearson's correlation coefficient. The relationships between presence of osteolysis, gender or clinical assessment and component loosening were evaluated with the chi-square test or Fisher's exact probability test. The distribution difference of degree of pain between component loosening cases and stable cases was analyzed with the Mann-Whitney U-test. All statistical analyses were done with the software StatView for Windows (ver. 4.54). A probability value (p-value) of  $\leq 0.05$  was considered significant.

## Results

### Femoral stem

The grading of cementing technique (Barrack et al. 1992) around the femoral stem was assessed on post-operative radiographs and they were grade A in 36 hips, grade B in 30, grade C in 6 hips and none were grade D. 66 stems were inserted in neutral position, 6 hips were in valgus position  $> 3^\circ$  relative to the axis of the femoral medullary canal on the postoperative radiograph and only one stem showed  $\geq 5^\circ$  movement of its axis with cement fracture at the 10-year follow-up.

The average subsidence of the stem 10 years after the operation was 2.9 (95% CI: 2.29–3.54) mm and 8 hips showed more than 5 mm subsidence at the 10-year follow-up. There was no relationship between the amount of stem subsidence at the 10-year follow-up and age at operation of each case ( $r = -0.092$ ,  $p = 0.4$ ) (Figure 1).

According to Harris et al.'s (1982) classification of cemented stems, 8 hips were definitely loose

and 1 hip probably loose. These 9 stems (13%) were regarded as "aseptic loosening".

Focal osteolysis around the femoral stem was seen in 23 hips (32%) and showed no special pattern of distribution. There was no statistically significant correlation between the osteolysis around the stem and stem loosening: 4 of 9 loose stems and 19 of 63 stable stems had some focal osteolysis around their stems.

No correlation was found between gender in loose stem (4 men and 5 women) and stable stem cases (26 men and 37 women) or average age at operation between stem loosening (64, SD 12 years) and stable stem cases (67, SD 8 years).

### Sockets

Complete demarcation around the cement-bone interface was seen in 10 sockets. Migration of  $\geq 5$  mm or change in the lateral inclination angle of  $\geq 5^\circ$  occurred in 11 sockets. These cases were classified as types 3 and 4 according to Hodgkinson et al. (1988), respectively, and these 21 sockets (29%) were defined as loose. 4 of these 21 patients also showed aseptic loosening of their stems.

Focal osteolysis around sockets was noted in 8 hips, all of which had osteolysis in the peripheral zones of DeLee and Charnley (zone 1 or 3). 1 hip showed severe osteolysis in all 3 zones. 5 of 21 loose socket cases and 3 of 51 stable socket ones had focal osteolysis around their sockets ( $p = 0.04$ ).

Ectopic bone formation was present in 31 hips. Using Brooker et al.'s method (1973) they were class I in 20 hips, class II in 5, class III in 4 and class IV in 2 hips.

The distribution of gender in the loose socket (10 males and 11 females) and stable socket cases (20 males and 31 females) was similar ( $p = 0.5$ ).

The average age of the patients at primary surgery in loose socket cases (68, SD 8 years) was significantly higher than that of stable socket ones (63, SD 10 years) ( $p = 0.02$ ).

### Relationships between liner socket wear and component loosening, osteolysis, gender or age

The average linear socket wear in all patients of this series was 1.53 (95% CI: 1.35–1.72) mm at the 10-year follow-up. We found no significant differ-

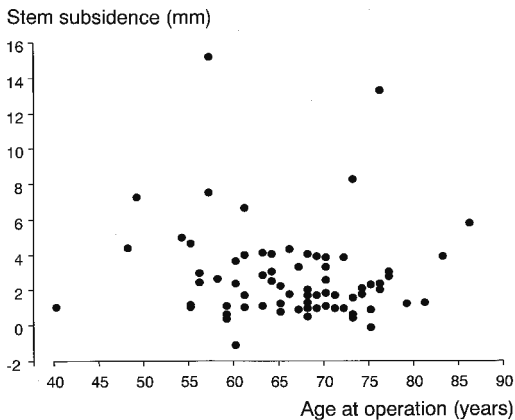


Figure 1. The relationship between stem subsidence at 10-year follow-up and age of the patients at operation.

Table 1. Relationships between component loosening and polyethylene linear wear on radiographs at 10-year follow-up

Linear wear versus loosening	Linear wear at 10-year follow-up mm, mean (SD)	P-value <sup>a</sup>
Stem loosening	1.69 (1.05)	0.8
No stem loosening	1.51 (0.76)	
Socket loosening	2.04 (0.83)	0.0003
No socket loosening	1.32 (0.68)	

<sup>a</sup> Student's t-test

ence in linear socket wear at the 10-year follow-up between loose stem (definite loosening and probable loosening according to Harris et al.) and stable stem cases (Table 1). However, in the loose socket ones (types 3 and 4 according to Hodgkinson et al.), average linear socket wear at the 10-year follow-up was significantly greater than that of stable socket cases (Table 1). Linear wear in patients with osteolysis anywhere around components on the 10-year radiographic follow-up was significantly greater than that in cases with no osteolysis (1.83, SD 0.78 mm vs. 1.34, SD 0.75 mm;  $p = 0.01$ ). The average linear wear in male patients at the 10-year follow-up was significantly greater than that in females (1.76, SD 0.89 mm vs. 1.37, SD 0.68 mm;  $p = 0.04$ ). We found no significant relationship between linear socket wear at the 10-year follow-up and the patients' age at primary surgery ( $r = -0.199$ ,  $p = 0.09$ ) (Figure 2).

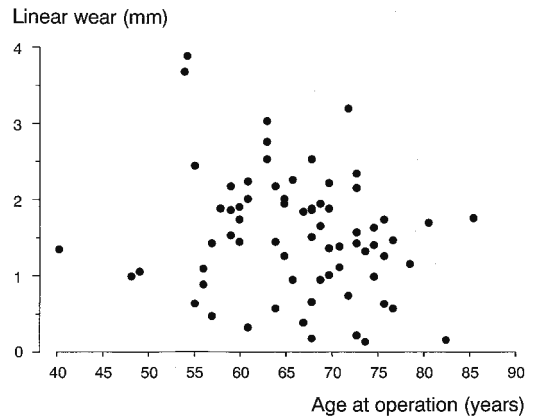


Figure 2. The relationship between linear wear at 10-year follow-up and age of the patients at operation.

Table 2. Relationship between degree of pain and component loosening

Degree of pain	Stable cases	Cases with loosening of any component
None	12	8
Mild	14	7
Moderate	17	9
Severe	3	2

$p = 0.8$  (Mann-Whitney U-test)

Table 3. Relationship between patients' satisfaction and component loosening

Patients' satisfaction	Number of patients	
	with any loose components	with stable components
Yes	17	37
No	9	9

$p = 0.2$  (chi-square test)

### Relationships between clinical assessments and component loosening

In 26 patients, one or both components had become loose at the 10-year follow-up. Of these, 8 patients had no pain. The distribution of the degree of pain did not differ significantly in patients with loose components or with stable components (Table 2).

Patient satisfaction at 10 years after primary surgery was similar in patients with stable or loose components (Table 3).

## Discussion

About 10,000 cemented total hip arthroplasties are performed a year in Sweden (Herberts and Malchau 2000, Malchau et al. 2000). Although many kinds of implants are commercially available worldwide, long-term radiographic and clinical follow-up studies have been done with only a few implant designs (Murray et al. 1995). To compare the clinical longevity of various implants, "survival" analysis with revision as the end-point, has been widely used. This type of analysis has affected the decisions of surgeons in their choice of implants and improved our method and long-term results in primary total hip arthroplasty (Herberts and Malchau 2000). However, survival analysis gives no information about the radiographic or clinical condition in each case, and provides only limited information (Murray et al. 1993, Kesteris et al. 1998). To clarify the issues of component stability and changes in the bone around the components, precise radiographic examination is necessary.

One of the important aims of clinical and radiographic follow-up in patients after total hip arthroplasty is to detect aseptic loosening as early as possible. If bone stock deficiency due to aseptic loosening around the components progresses, the revision will be complicated and even bone allograft may be necessary (Gie et al. 1993, Slooff et al. 1996). Longevity after complicated revision surgery is unpredictable and the strain of surgery on the patient is unduly severe (Kershaw et al. 1991, Eldridge et al. 1997, Meding et al. 1997). The patients' symptoms or degree of satisfaction with primary total hip arthroplasty in the present series had no relation to their radiographic findings as regards aseptic loosening. This means that the surgeon will fail to perform a revision when indicated if the patient's symptoms alone are used as a sign of component loosening.

According to the most recent report from the Swedish National Hip Register, the 10-year survival rate of the ScanHip total hip arthroplasty was 94% (Malchau et al. 2000), which was confirmed in a series with the same type of arthroplasty at Lund University Hospital, Sweden (Kesteris et al. 1998). These figures are comparable to the survival rates of other successful prostheses.

However, since the end-point of the survival analysis of the Swedish National Hip Register was revision surgery, the precise clinical, radiographic, or relationships between those findings of ScanHip total hip arthroplasty has still not been described. In addition to the revised cases, we found that 13% of the stems and 29% of the sockets in our series can be regarded as aseptic loosening. This means that the number of stable components is much less than that be expected from the Swedish National Hip Register report. Our findings emphasize the importance of serial, long-term radiographic follow up after total hip arthroplasty.

The cause, or causes, of aseptic loosening are still disputed (Mjöberg 1994, Robertsson et al. 1997, Aspenberg and Van der Vis 1998). Polyethylene wear is recognized as one of the factors related to component loosening or osteolysis (Harris 1995, Sochart 1999). In the present study, greater linear wear at the 10-year follow-up was seen in loose socket cases and those with osteolysis around the components, but not in loose stems. In the present study, we could not determine whether polyethylene wear induced socket loosening, or socket loosening induced greater linear wear. However, it seems obvious that stability of the cemented femoral stem at the 10-year follow-up is not correlated to polyethylene wear although there were some osteolysis lesions around the stem. Sochart (1999) reported that an increase in annual acetabular wear correlated strongly with aseptic loosening, failure and revision of the femoral Charnley prosthesis with the first generation cementing technique. The results of the analysis of the cementing technique in our series were almost ideal (grade A in 36 hips, grade B in 30 hips), which may be one reason why we found no relationship between polyethylene wear and stem loosening in our series. On the other hand, the cementing technique of the socket without pressurization may not be sufficient to achieve complete stability for 10 years and protect the bone-cement interface of sockets against polyethylene debris invasion. The peripheral osteolysis around sockets and its relation to socket loosening would accord with this view. The patients' bone quality may also have affected the stability of the sockets, since the patients' mean age in the loose socket group was higher than in the stable socket group.

In conclusion, aseptic loosening cases were detected in addition to the revised cases that were reported to the Swedish National Hip Register at the follow-up 10 years after ScanHip total hip arthroplasty. We found no correlations between clinical symptoms or patients' satisfaction and component loosening. Precise and serial long-term radiographic follow-up is the only satisfactory method for detecting aseptic loosening of total hip arthroplasty.

No benefits in any form have been or will be received from a commercial party related directly or indirectly to the subjects of this article.

- Aspenberg P, Van der Vis H. Migration, particles, and fluid pressure. A discussion of the cause of prosthetic loosening. *Clin Orthop* 1998; 352: 75-80.
- Bankston A B, Ritter M A, Keating E M, Faris P M. Measurement of polyethylene thickness in total hip arthroplasty. A technique analysis. *J Arthroplasty* 1994; 9 (5): 533-8.
- Barrack R L, Mulroy R D, Jr, Harris W H. Improved cementing techniques and femoral component loosening in young patients with hip arthroplasty. A 12-year radiographic review. *J Bone Joint Surg (Br)* 1992; 74: 385-9.
- Brooker A F, Bowerman J W, Robinson R A, Riley L H, Jr. Ectopic ossification following total hip replacement. Incidence and a method of classification. *J Bone Joint Surg (Am)* 1973; 55: 1629-32.
- DeLee J G, Charnley J. Radiological demarcation of cemented sockets in total hip replacement. *Clin Orthop* 1976; 121: 20-32.
- Eldridge J D, Smith E J, Hubble M J, Whitehouse S L, Learmonth I D. Massive early subsidence following femoral impaction grafting. *J Arthroplasty* 1997; 12: 535-40.
- Gie G A, Linder L, Ling R S, Simon J P, Slooff T J, Timperley A J. Impacted cancellous allografts and cement for revision total hip arthroplasty. *J Bone Joint Surg (Br)* 1993; 75: 14-21.
- Gruen T A, McNeice G M, Amstutz H C. "Modes of failure" of cemented stem-type femoral components. A radiographic analysis of loosening. *Clin Orthop* 1979; 141: 17-27.
- Harris W H. The problem is osteolysis. *Clin Orthop* 1995; 311: 46-53.
- Harris W H, McCarthy J C, O'Neil D A. Femoral component loosening using contemporary techniques of femoral cement fixation. *J Bone Joint Surg (Am)* 1982; 64: 1063-7.
- Herberts P, Malchau H. Long-term registration has improved the quality of hip replacement. A review of the Swedish THR register comparing 160,000 cases. *Acta Orthop Scand* 2000; 71 (2): 111-21.
- Hodgkinson J P, Shelley P, Wroblewski B M. The correlation between the roentgenographic appearance and operative findings at the bone-cement junction of the socket in Charnley low friction arthroplasties. *Clin Orthop* 1988; 228: 105-9.
- Johnston R C, Fitzgerald R H Jr., Harris W H, Poss R, Müller M E, Sledge C B. Clinical and radiographic evaluation of total hip replacement. A standard system of terminology for reporting results. *J Bone Joint Surg (Am)* 1990; 72: 161-8.
- Kershaw C J, Atkins R M, Dodd C A, Bulstrode C J K. Revision total hip arthroplasty for aseptic failure. A review of 276 cases. *J Bone Joint Surg (Br)* 1991; 73: 564-8.
- Kesteris U, Ilchmann T, Wingstrand H, Önnarfält R. Polyethylene wear in Scanhip<sup>®</sup> arthroplasty with a 22 or 32 mm head. *Acta Orthop Scand* 1996; 67 (2): 125-7.
- Kesteris U, Robertsson O, Wingstrand H, Önnarfält R. Cumulative revision rate with the Scan Hip<sup>®</sup> Classic I total hip prosthesis. *Acta Orthop Scand* 1998; 69 (2): 133-7.
- Livermore J, Ilstrup D, Morrey B. Effect of femoral head size on wear of the polyethylene acetabular component. *J Bone Joint Surg (Am)* 1990; 72: 518-28.
- Malchau H, Herberts P, Söderman P, Odén A. Prognosis of total hip replacement. Update and validation of results from the Swedish national hip arthroplasty register 1979-1998. Department of Orthopaedics, Göteborg University, Sweden 2000.
- Meding J B, Ritter M A, Keating E M, Faris P M. Impaction bone-grafting before insertion of a femoral stem with cement in revision total hip arthroplasty. A minimum two-year follow-up study. *J Bone Joint Surg (Am)* 1997; 79: 1834-41.
- Mjöberg B. Theories of wear and loosening in hip prostheses. Wear-induced loosening vs loosening-induced wear—a review. *Acta Orthop Scand* 1994; 65: 361-71.
- Murray D W, Carr A J, Bulstrode C J K. Survival analysis of joint replacements. *J Bone Joint Surg (Br)* 1993; 75: 697-704.
- Murray D W, Carr A J, Bulstrode C J. Which primary total hip replacement? *J Bone Joint Surg (Br)* 1995; 77: 520-7.
- Robertsson O, Wingstrand H, Kesteris U, Jonsson K, Önnarfält R. Intracapsular pressure and loosening of hip prostheses. Preoperative measurements in 18 hips. *Acta Orthop Scand* 1997; 68 (3): 231-4.
- Slooff T J, Buma P, Schreurs B W, Schimmel J W, Huiskes R, Gardeniers J. Acetabular and femoral reconstruction with impacted graft and cement. *Clin Orthop* 1996; 324: 108-15.
- Sochart D H. Relationship of acetabular wear to osteolysis and loosening in total hip arthroplasty. *Clin Orthop* 1999; 363: 135-50.