

The relation of the coracoclavicular ligament insertion to the acromioclavicular joint

A cadaver study of relevance to lateral clavicle resection

T Dirk Boehm, Stephan Kirschner, Annegret Fischer and Frank Gohlke

Department of Orthopaedic Surgery, Koenig-Ludwig-Haus, University of Wuerzburg, Germany
Correspondence: dr.dirkboehm@web.de
Submitted 02-06-07. Accepted 03-01-04

ABSTRACT Resection of the lateral end of the clavicle is a common procedure for arthrosis of the acromioclavicular joint (AC-joint). However, no anatomical data on the distance between the insertions of the coracoclavicular ligaments and the AC-joint have been reported.

In 36 cadaver shoulders (18 male), we studied the relation between the AC-joint and the insertions of the joint capsule, trapezoid and conoid ligaments.

The distance from the AC-joint to the medial end of its capsule was, on average, 0.7 cm (0.4–0.9) cm in women and 0.8 (0.4–1.2) cm in men. In women, the trapezoid ligament began, on average, at 0.9 (0.4–1.6) cm and ended at 2.4 (2.0–2.8) cm and in men, it began at 1.1 (0.8–1.6) cm and ended at 2.9 (2.1–3.8) cm medial to the AC joint. The corresponding figures for the conoid ligament were 2.6 (2.0–3.7) cm and 4.7 (3.9–6.2) cm. A resection of 1 cm of the lateral clavicle detaches 8%, a resection of 2 cm 60% and a resection of 2.5 cm 90% of the trapezoid ligament.

We recommend a maximum resection of 1 cm of the lateral clavicle because a resection of 2 cm or more may cause postoperative AC-joint instability and related pain.

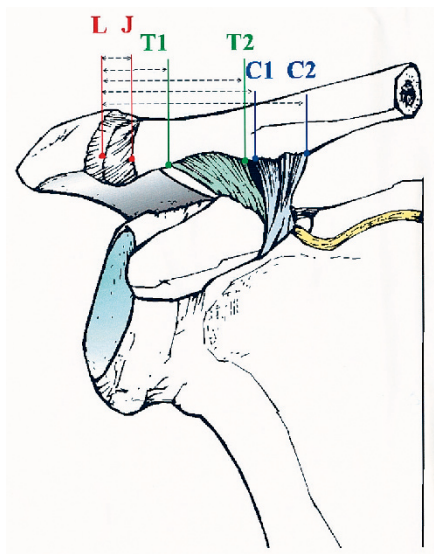
Lateral clavicle resection is a common open arthroscopic procedure for primary or secondary painful degenerative disease of the acromioclavicular joint. In 1941, Mumford and Gurd published independently their results using this open surgical procedure. Gurd (1941) described removal of the lateral third of the clavicle without detaching the coracoclavicular ligaments.

Mumford (1941) resected 1/2–1 inch (2.5 cm) in 4 patients with excellent results. Later recommendations and reports in the literature and textbooks about the amount of bone which should be resected during open procedures vary from 0.5 cm to 8 cm (Table 1).

The recommended amount of lateral clavicle resection in arthroscopic procedures is 0.5–1 cm (Gartsman et al. 1991, Flatow et al. 1992). Branch et al. (1996) found that only 5 mm of the distal clavicle needs to be resected to prevent bone-to-bone contact. A successful postoperative result should be achieved by resecting enough

Table 1. Literature review of recommended amount of bone removed during resection of the lateral clavicle

| | |
|--------------------------|--------------|
| Bateman 1972 | 1/2–3/4 inch |
| Blazar et al. 1998 | 1.5–2 cm |
| Branch et al. 1996 | 0.5 cm |
| Cook and Tibone 1988 | 1.9 cm |
| Curry and Lyttle 1955 | 3/4–2 inch |
| Eskola et al. 1996 | 1 cm |
| Flatow et al. 1992 | 0.5–1 cm |
| Hedtman et al. 1998 | 1 cm |
| Inman et al. 1962 | 1/2–3/4 inch |
| Jacobs and Wade 1966 | 3/4–1 inch |
| Lancaster et al. 1987 | 2 cm |
| Mumford 1941 | 1/2–1 inch |
| Novak et al. 1995 | 1.5–1.7 cm |
| Peterson 1983 | 1–2 cm |
| Post 1978 | Minimum 2 cm |
| Rockwood et al. 1996 | Minimum 2 cm |
| Rowe 1988 | 1 cm |
| Urist 1946 | 6–8 cm |
| Wirth and Breitner 1984 | 1.0–2.5 cm |
| Worcester and Green 1968 | 1 inch |



Measured distances; anterior view.

- the distance from the lateral end of the clavicle to the end of the AC-joint capsule (L–J).
- the lateral extent of the trapezoid ligament (L–T1).
- the medial end of the trapezoid ligament (L–T2).
- the lateral extent of the conoid ligament (L–C1).
- the medial end of the conoid ligament (L–C2).

bone to avoid contact of the lateral clavicle with the acromion and by preserving the stability of the lateral clavicle by respecting the coracoclavicular ligaments. Despite extensive studies of the ligamentous system of the acromioclavicular joint (DePalma 1963, Fukuda et al. 1963, Urist 1963, Salter et al. 1987), we have found no data about the distance of the trapezoid and conoid ligaments to the acromioclavicular joint. Therefore we analyzed the relationship between the coracoclavicular ligaments and the acromioclavicular joint in cadavers.

Material and methods

The entire clavicle and scapula with the attached ligamentous structures of 36 cadaveric shoulders (average age 84 (73–97) years) were harvested. The gender and side distributions were equal. All shoulders were fixed in a 70% alcohol solution. The measurements were made using a micrometer (1/10 mm accuracy) and a 5.0× loupe magnification (spherical lens).

The distance of the medial extent of the superior acromioclavicular ligament to the acromioclavicular joint was measured on the superior cortex of the clavicle.

Apart from the length of the clavicle, we measured 5 distances on the undersurface of the clavicle (Figure).

Statistics

For the statistical analysis, we used SPSS Software (Version 9.0 SPSS GmbH, Muenchen, Germany) with the t-test and Pearson's correlation coefficient.

Results

In women, the average length of the clavicle was 14.2 (12.2–16.8) cm and in men, 15.8 (14.5–17.2) cm. The distance of the superior acromioclavicular ligament to the lateral end of the clavicle was, on average, 0.75 cm. The distance of the beginning of the trapezoid ligament to the lateral end of the clavicle was, on average, 1.01 cm. The distance of the beginning of the conoid ligament to the lateral end of the clavicle was, on average, 2.62 cm (Table 2).

Table 2. Length of the clavicle and distances of the joint capsule, trapezoid and conoid ligaments to the lateral end of the clavicle

| | Average (cm) | SD | Women | SD | Men | SD |
|-----------------------------|----------------|------|----------------|------|----------------|------|
| Clavicle length | 15 (12–17) | 1.2 | 14 (12–17) | 1.2 | 16 (15–17) | 0.72 |
| End of joint capsule | 0.75 (0.4–1.2) | 0.19 | 0.68 (0.4–0.9) | 0.16 | 0.81 (0.4–1.2) | 0.19 |
| Beginning of trapezoid lig. | 1.0 (0.4–1.6) | 0.27 | 0.88 (0.4–1.6) | 0.26 | 1.1 (0.8–1.6) | 0.23 |
| End of trapezoid lig. | 2.6 (2.0–3.8) | 0.39 | 2.4 (2.0–2.8) | 0.20 | 2.9 (2.1–3.8) | 0.40 |
| Beginning of conoid lig. | 2.6 (2.0–3.7) | 0.47 | 2.3 (2.0–2.9) | 0.25 | 2.9 (2.4–4.1) | 0.46 |
| End of conoid lig. | 4.7 (3.9–6.2) | 0.53 | 4.4 (3.9–4.9) | 0.29 | 5.0 (4.4–6.2) | 0.54 |

Table 3. Amount of detachment of the acromioclavicular joint capsule, trapezoid and conoid ligaments after a 1-cm, 2-cm and 1-inch resection of the lateral clavicle

| Resected bone | Detachment of capsule | Detachment of trapezoid | Detachment of conoid |
|------------------|-----------------------|-------------------------|----------------------|
| 1 cm | 97% | 8 % | 0% |
| 2 cm | 100% | 60% | 1% |
| 1 inch (2.54 cm) | 100% | 90% | 6.3% |

The distance of the insertion of the trapezoid and conoid ligaments to the AC-joint increased with the length of the clavicle ($p < 0.01$, Pearson's correlation coefficient). The amount of detachment of the acromioclavicular joint capsule, trapezoid and conoid ligaments after a resection of 1 cm, 2 cm and 1 inch of the lateral clavicle is shown in Table 3.

Discussion

Some surgeons state that they want to respect the coracoclavicular ligaments, when possible, during lateral clavicle resection (Gurd 1941, Worcester and Green 1968, Post 1978). Rockwood et al. (1996) accept resection of the trapezoid ligament during this procedure if the conoid ligament remains intact. They argue, according to Fukuda et al. (1963), that the conoid ligament alone is a sufficient restraint on superior migration of the clavicle, but Eskola et al. (1996) found that the results of resection of more than 1 cm are significantly worse, as regards pain in posttraumatic and osteoarthrotic cases. They recommended a maximum resection of 1 cm. This was supported by biomechanical studies by Branch et al. (1996), which showed that a resection of 0.5 cm eliminates bone-to-bone contact of the acromion and the distal clavicle during rotation. They found no difference in the final results, whether or not the resection was performed via an inferior or superior approach leading to detachment of the inferior or superior acromioclavicular ligament, respectively. Fukuda et al. (1963) showed that the trapezoid ligament is the major constraint to axial compressive loading of the acromioclavicular joint. Our data indicate that not only superior and anteroposterior translation may occur after dissection of the

trapezoid ligament. After resection of more than 1 cm of the lateral clavicle, the trapezoid ligament may be detached completely and this causes painful contact during an axial load, such as cross body adduction or hyperabduction. Therefore, we agree with Gurd (1941) that the coracoclavicular ligaments should not be damaged when performing a lateral clavicle resection. Blazar et al. (1998) found, by using stress radiographs, that patients with an anteroposterior translation of more than 12 mm after distal clavicle resection had much more pain than those with less translation. However, they did not find that the amount of resected bone correlated with pain, and they gave no data concerning the horizontal stability or the amount of bone resected in the 2 patients with poor results. According to our findings, a resection of 1.5–2 cm, as Blazar et al. (1998) described, always detaches the acromioclavicular ligaments and therefore releases the major constraint against anteroposterior translation, which explains the poor outcome in these cases. Urist (1963) discussed the superior acromioclavicular ligament and joint capsule as primary anteroposterior stabilizers of the AC-joint, because he could completely dislocate the clavicle posteriorly after complete detachment of the joint capsule, but only sublaxate it superiorly. Only after additional dissection of the trapezoid and/or conoid ligaments could he perform a complete superior dislocation. In a biomechanical study, Branch et al. (1996) reported that the resection of 0.5 cm combined with complete dissection of the acromioclavicular ligaments increases the scapular rotation from 35° to 130°, which causes rotational and anteroposterior instability of the lateral clavicle. However, during standard open surgical procedures, the inferior acromioclavicular ligament remains intact and standard arthroscopic resections of the lateral clavicle preserve the superior acromioclavicular ligament. In these conditions, Branch et al. (1996) found that the rotation of the clavicle is limited sufficiently. They stated that postoperative pain is more likely to be caused by tension on the posterior aspect of the resected lateral clavicle rather than by “bony abutment”.

To avoid instability and the associated pain after lateral clavicle resection the maximum amount of bone resected from the lateral clavicle should be 0.8 cm in female and 1 cm in male subjects. If,

after resection of 0.8 cm and 1 cm, respectively, the hyperadduction and hyperabduction test still show compression between the resected clavicle and the acromion, we agree with Rowe (1988), who recommended resection of a part of the acromion that contribute to the AC-joint. During open lateral clavicle resection, the AC joint capsule should be preserved by a careful longitudinal split and complete closure after the bone resection to provide more rotational and anteroposterior stability.

No competing interests declared.

- Bateman J E. Acromioclavicular arthritis. In: *The shoulder and neck* (ed. Bateman J E). Philadelphia: Saunders, 1972: 266-9.
- Blazar P E, Ianotti J P, Williams G R. Anteroposterior instability after distal clavicle resection. *Clin Orthop* 1998; 348: 114-20.
- Branch TP, Brudette HL, Shahriari AS, Carter FM, Hutton WC. The role of the acromioclavicular ligaments and the effect of distal clavicle resection. *Am J Sports Med* 1996; 24: 293-7.
- Cook F, Tibone J E. The Mumford procedure in athletes. An objective analysis of function. *Am J Sports Med* 1988; 16: 97-100.
- Curry C S, Lyttle N. Expendable bone. *Am J Surg* 1955; 89: 819-33.
- DePalma A F. Surgical anatomy of the acromioclavicular and sternoclavicular joints. *Surg Clin North Am* 1963; 43: 1540-50.
- Eskola A, Santavirta S, Viljakka T, Wirta J, Partio T E, Hoikka V. The results of operative resection of the lateral end of the clavicle. *J. Bone Joint Surg (Am)* 1996; 78: 584-7.
- Flatow E L, Cordasco F A, Bigliani L U. Arthroscopic resection of the outer end of the clavicle from a superior approach: a critical quantitative radiographic assessment of bone removal. *Arthroscopy* 1992; 8: 55-64.
- Fukuda K, Craig E V, An K N, Cofield R H, Chao E Y S. Biomechanical study of the ligamentous system of the acromioclavicular joint. *J. Bone Joint Surg (Am)* 1963; 68: 434-9.
- Gartsman G M, Combs A H, Davis P F. Arthroscopic acromioclavicular resection: An anatomical study. *Am J Sports Med* 1991; 19: 2-5.
- Gurd F B. The treatment of complete dislocation of the outer end of the clavicle: A hitherto undescribed operation. *Ann Surg* 1941; 113: 1094-8.
- Hedtmann A, Fett H, Ludwig J. Die Behandlung veralteter, posttraumatischer Akromioklavikulargelenkinstabilitäten und -arthrosen. *Orthopäde* 1998; 27: 556-66.
- Inman V T, McLaughlin H D, Nevaizer J, Rowe C. Treatment of complete acromioclavicular dislocation. *J Bone Joint Surg (Am)* 1962; 44: 1008-11.
- Jacobs B, Wade P A. Acromio-clavicular joint injury. An end result study. *J Bone Joint Surgery (Am)* 1966; 48: 475-86.
- Lancaster S, Horowitz M, Alonso J. Complete acromioclavicular separations. *Clin Orthop* 1987; 216: 80-8.
- Mumford E B. Acromioclavicular dislocation. *J Bone Joint Surg* 1941; 23: 799-802.
- Novak P J, Bach B R, Romeo A A, Hager C A. Surgical resection of the distal clavicle. *J Shoulder Elbow Surg* 1995; 4: 35-40.
- Peterson C J. Resection of the lateral end of the clavicle. *Acta Orthop Scand* 1983; 54: 904-7.
- Post M. Dislocations of the shoulder. In: *The shoulder* (ed. Post M). Philadelphia: Lea & Febiger 1978: 429-508.
- Rockwood C A Jr, Williams G R, Young D C. Injuries to the acromioclavicular joint. In: *Fractures in adults* (eds. Rockwood C A Jr, Green D P, Buchholz R W, Heckman J D). Philadelphia: Lippincott Raven 1996: 1341-413.
- Rowe C R. Acromioclavicular and sternoclavicular joints. In: *The shoulder* (ed. Rowe C R). New York: Churchill Livingstone 1988: 293-327.
- Salter E G, Nasca R J, Shelley B S. Anatomical observations on the acromioclavicular joint and supporting ligaments. *Am J Sports Med.* 1987; 15: 199-206.
- Urist M R. Complete dislocation of the acromioclavicular joint. *J Bone Joint Surg (Am)* 1946; 28: 813-37.
- Wirth C J, Breitner S. Resection of the acromial end of the clavicle in acromioclavicular joint arthrosis. *Z Orthop Ihre Grenzgebiete* 1984; 122 (2): 208-12.
- Worcester J N, Green D P. Osteoarthritis of the acromioclavicular joint. *Clin Orthop* 1968; 58: 69-73.