

Experiences from tissue microarray in soft tissue sarcomas

M. Nilbert and J. Engellau

Dept of Oncology, University Hospital, Lund, Sweden
mef.nilbert@onk.lu.se, jacob.engellau@onk.lu.se

ABSTRACT The tissue microarray (TMA) technology was introduced in 1998 as a tissue preserving, high-throughput technique that allows studies of multiple markers in large sample sets. TMA slides can be analyzed using techniques such as immunohistochemistry and *in situ* hybridization and represents a powerful tool for the investigation of potential diagnostic and prognostic markers identified in DNA microarray studies. We review the TMA method, its reproducibility, advantages, limitations and future perspectives with specific focus on soft tissue sarcomas.

Recent advances in genetics and biotechnology have contributed to the development of microarray technologies that allow rapid and large-scale screening of samples. Thereby, tumor classification schemes based on biological markers are increasingly identified, and recent data demonstrate that gene expression profiles can be of diagnostic value in soft tissue sarcomas (Lee et al. 2003). However, these markers need to be evaluated in large and independent sample sets in order to define their biological importance. Large, and preferably population-based, tissue banks linked to clinical databases will be a major resource for these studies. Conventional techniques for tumor analysis using whole-tissue sections are labour intensive and time consuming. The tissue microarray (TMA) technique was developed in 1998 for high-throughput analysis of multiple tumor samples in a single experiment and is now becoming an important tool for further investigation of information derived from DNA microarray studies (Kononen et al. 1998, Bubendorf et al. 1999, Rimm

et al. 2001, Howbrook et al. 2003). TMA utilizes 0.6-mm core needle biopsies, which are obtained from archival paraffin-embedded tissue blocks and thereafter re-embedded in a novel paraffin array block. Thereby, TMA allows a large number of archival specimens to be analyzed simultaneously. TMA facilitates studies of molecular alterations at the DNA, RNA and protein level in large tumor materials and thereby provides a powerful tool to detect associations between molecular markers, histopathological subsets and clinical endpoints (Schraml et al. 1999, Camp et al. 2000, Andersen et al. 2002, Nielsen et al. 2003).

The subclassification of sarcomas is sophisticated and immunohistochemistry has been introduced as a complement to morphology in routine diagnosis. Immunohistochemical expression of a number of antibodies has also been studied with respect to their prognostic value. Although several markers have shown correlations with prognosis, no consistent, strong and independent prognostic or predictive factor has yet been identified in soft tissue sarcomas. Considering the various genetic characteristics, ranging from single chromosomal translocations with their respective fusion proteins in e.g. synovial sarcomas and liposarcomas to the complex genetic alterations that characterize e.g. leiomyosarcomas and malignant fibrous histiocytomas, this is perhaps expected rather than surprising. Alternatively, the conflicting data on the clinical correlations may be explained by differences in methodology and interpretations, rather than by a true variation in tumor biology. In order to minimize the latter effect guidelines for immunostaining and application of TMA are needed.

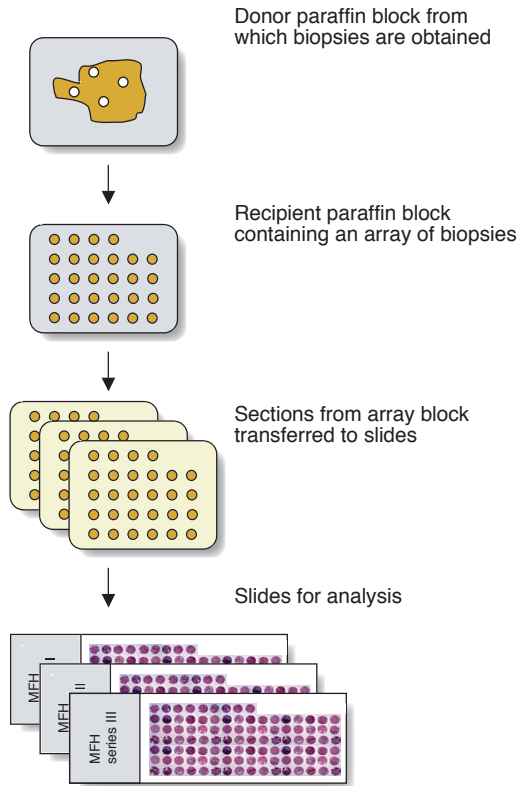


Figure 1. Schematic presentation of the tissue microarray method.

Method (Figure 1)

When performing TMA, representative paraffin-embedded tumor blocks should be selected. Optimally, well-preserved tissue without necrosis and tumor blocks containing tumor tissue throughout the block should be chosen since the thickness of the donor block influences the number of usable slides obtained from the array block. A fresh section is made and is stained with hematoxylin and erythrosin B (H&E). Representative tumor areas—and if applicable also an area containing normal tissue—are marked on the H&E-stained slide. The number of areas depends on the design of the study, but in order not to lose information most investigators aim at obtaining 3 cylinder biopsies from each tumor.

Once the defined tumor material has been collected, TMA is performed at a speed of 30–70 biopsies per hour and 500–1000 biopsies can be evaluated on a single microscope slide (Kononen et al. 1998, Rimm et al. 2001). Retrieval of the

0.6-mm tumor biopsies utilized for TMA results in minor, usually negligible, damage to the donor block. Multiple such biopsies can therefore be obtained from most paraffin blocks, which allow construction of several replicate array blocks, each containing the same tumor at a given coordinate. Indeed, applying TMA to a 10-mm diameter tumor will allow >10,000 analyses (Schraml et al. 1999). TMA thereby increases the number of markers that can be investigated within the same tumor set and contributes to tissue preservation. Whereas 100–200 sections can generally be obtained from a regular paraffin embedded tissue block, several thousands of TMA sections can be generated from a paraffin block.

A novel paraffin block, referred to as the array block, is made. Ideally, the array block should be thicker than the blocks used for routine histopathology to allow the entire length of the cylinder biopsy to be introduced into the array block. The tissue arrays utilize two separate core needles to punch the donor and the recipient tumor blocks. A hole is punched in the newly made array block using the smaller (0.6-mm) cylinder, whereafter the larger (0.8-mm) cylinder is used to obtain a biopsy from the original, donor, block. The tumor-containing cylinder is introduced into the hole leaving a small part of the tumor cylinder above the surface of the array block. Care should be taken not to introduce the cylinders too low in the array block. The next cylinder biopsy is made 0.8-mm from the first one leaving 0.1-mm spacing between the samples. The system utilizes a micrometer-precise coordinate system for the assembly of the array and 500 specimens or more can be assembled in an array block, but we have for practical purposes generally utilized array blocks containing 200–400 cylinder biopsies. When constructing the array block an asymmetrical positioning, e.g. leaving space between the rows every 5 to 10 rows and/or leaving half a row at one end, is important for correct orientation during analysis (Figure 2). When the array block is full it is incubated at 37° C for 15 min, a glass slide is placed on top of the block and gentle pressure is applied in order ensure that the cylinders are at the same level and to obtain an even surface. Thereafter, the TMA blocks can be sectioned at 3–4- μ m for immunohistochemistry (Figure 3).

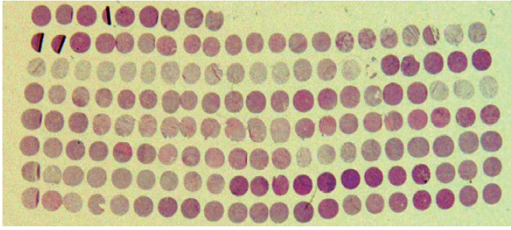


Figure 2. Overview of a TMA slide stained with H&E. The half-filled row facilitates orientation. Thorn and partly folded TMA sections can be seen.

Reproducibility

When TMA was introduced concern was raised regarding the reproducibility of a method that analyzed only a minute sample of tumor tissue. Indeed, each cylinder section encompasses only about 0.3 mm². However, TMA data have been found to reproduce information gained from studies that have utilized whole tissue sections and have confirmed clinicopathological correlations reported from studies applying immunostaining on large tissue sections or using DNA isolated from entire tumor pieces or paraffin sections. These studies have included different tumor types, including colorectal cancer, breast cancer, bladder cancer, prostate cancer, and soft tissue sarcoma

(Kononen et al. 1998, Bubendorf et al. 1999, Schraml et al. 1999, Camp et al. 2000, Richter et al. 2000, Engellau et al. 2001, Hoos et al. 2001, Nocito et al. 2001, Torhorst et al. 2001, Fernebro et al. 2002, Hoos et al. 2002, Mucci et al. 2002, Nielsen et al. 2003). Studies comparing immunostaining of TMA sections with whole-tissue sections have generally shown good agreement between the methods. Engellau et al. (2001) found on average 9% higher Ki-67 expression in the TMA sections in a study of 47 tissue blocks from 11 MFH. Hoos et al. (2001) evaluated the markers Ki-67, p53 and pRB in 59 fibroblastic tumors through comparison between TMA and whole-tissue sections. Reliable readings from triplicate cores were obtained in 96% for Ki-67, 98% for p53 and in 91% for pRB. Both methods showed a correlation between overexpression of Ki-67 and survival. Nielsen et al. (2003) performed cDNA microarray profiling of synovial sarcoma and further evaluated well-established as well as candidate antibodies for their specificity in synovial sarcoma using TMA-based immunostaining. The results showed distinct clustering of the synovial sarcomas based on their immunostaining profiles, which were in accordance with previously published data from whole-tissue studies. A somewhat lower fraction of tumors positive for CD99

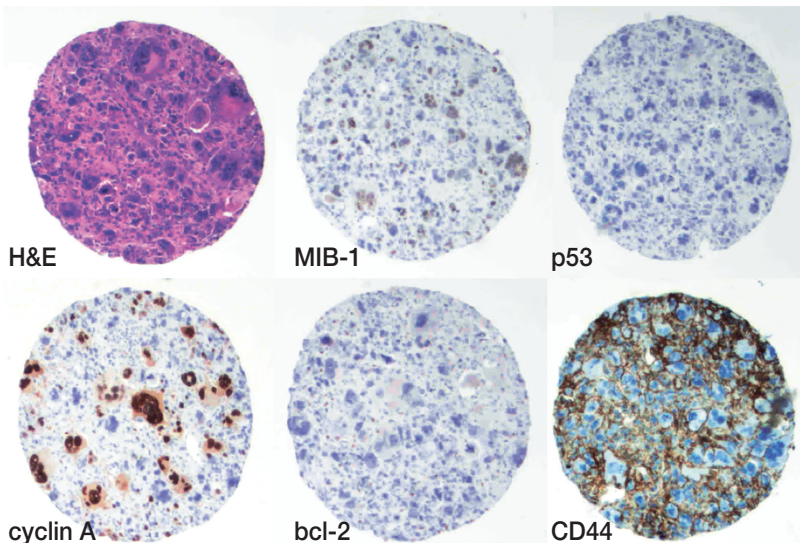


Figure 3. TMA core sections from the same malignant fibrous histiocytoma stained for H&E and immunostained for the markers MIB-1, p53, cyclin A, bcl-2 and CD44. Both negative and positive staining patterns are seen.

and S100 were reported, perhaps because of under-recognition of focal staining in the TMA cores (Nielsen et al. 2003).

The ability to identify clinicopathological correlations using TMA is perhaps more important than the absolute comparison between the results from studies applying TMA or whole-tissue sections. Indeed, the TMA technology was developed in order to survey large tumor populations rather than to characterize expression patterns in individual tumors. Studies applying TMA to breast cancer have confirmed clinicopathological correlations such as amplification of ERBB2 and MYC in steroid receptor negative tumors, p53 expressing tumors (Kononen et al. 1998, Torhorst et al. 2001). Camp et al. (2001) obtained an accuracy rate of >95% if 2–3 core biopsies were used to study immunohistochemical expression of ER, PgR and Her2/neu in breast cancer and Nocito et al. (2001) reliably assessed histological grade and Ki-67 labelling index using 4 replica TMA sections from bladder cancer. Despite discrepancies in individual cases, clinicopathological associations found in studies using whole-tissue sections, have successfully been demonstrated with TMA-based analyses. In a TMA study applying FISH to study oncogene amplification in different histopathologic tumor types, 73% of the amplification data collected through multiple previous investigations could be reproduced in one single experiment (Schraml et al. 1999).

Loss of TMA sections

Loss of TMA sections during the array process is another reason for obtaining 3–4 replica biopsies from each tumor. Most TMA series report loss of about 10–15% of the sections, either due to empty spots on the slide or due to sections of poor technical quality, most commonly necrotic, torn or folded sections (Mucci et al. 2000, Hoos et al. 2001). A low number of cores will result in a higher loss and a lower concordance between the readings. If 3 core biopsies are obtained from each tumor 98% of the tumors are estimated to be successfully analyzed using immunostaining (Hoos et al. 2002). In addition, Engellau et al. (2001) showed that analyzing an increasing number of tumor areas is feasible up to 3 areas, whereafter additional areas have only a minor impact on the variability of the

scoring. Retrieval of core biopsies from multiple paraffin-embedded tumor blocks may, however, provide an even better estimate of the tumor's biology, with lower variability compared to analysis of multiple biopsies from the same block (Engellau et al. 2001). Depending on the marker studied and the quality of the material within the array sections 1–2 array sections are generally required to evaluate the staining. Disagreement between the different core sections from the same tumor probably depend on the marker studied, but is generally a minor problem and Hoos et al. (2001) reported disagreement in 2% of the cores. The recommendation of using triplicate TMA sections for analysis is in accordance with the results of several studies in different tumor types and will minimize loss of data, ensure concordant readings in most cases and thereby provide a reliable immunohistochemical expression profile. Studies that have applied FISH analysis to TMA sections generally report a somewhat lower rate of successful analysis and concordant results than studies applying immunostaining (Schraml et al. 1999, Andersen et al. 2002). However, also the gene amplification surveys report successful analysis of many tumor types, good correlations with previously identified amplifications, and identification of clinicopathologic correlations based on TMA data (Schraml et al. 2001).

Evaluation

In order to maximize the number of evaluable TMA sections and to provide a true estimate of the marker studied, heterogeneity in both tumor tissue and staining patterns needs to be taken into account. Nuclear stainings and patterns evaluated based on a presence or an absence of staining can often be determined from one TMA section containing representative tumor tissue. In contrast, stainings that are dominantly cytoplasmic, markers that produce heterogeneous staining patterns or staining patterns evaluated in three or more categories will result in a higher number of non-assessable samples due to discordant readings and thus generally require two or more TMA sections to obtain an acceptable level of reproducibility (Hoos et al. 2001). The fraction of tumors with heterogeneous findings is probably also dependent on the tumor type studied. Heterogeneous staining patterns and discordant readings between the

TMA sections influence the number of assessable tumors. Markers with a high degree of intra-tumor heterogeneity and with different staining patterns in the periphery and in the center of the tumor are likely to be more vulnerable to TMA-based interpretations. Thus, obtaining core biopsies from the periphery as well as the center of the tumor may be required for a correct immunohistochemical characterization for some markers (Camp et al. 2000). Furthermore, parameters such as growth patterns, vascular invasion and microscopic tumor necrosis generally require evaluation of larger tumor areas, and may thus be hard to determine from TMA sections.

Archival paraffin-embedded specimens

Since TMA offers the possibility to study large tumor cohorts with long follow-up the question of antigen durability was studied by Camp et al. (2000) who found that most 50–70 years old archival tumors are suitable for immunohistochemical analysis. However, antigen preservation may depend on fixation, paraffin embedding, block storage and the method applied for antigen retrieval. Previous handling of the tumor tissue may also affect the structure and consistency of the tissue and may thereby also influence the sectioning of the array block. For these reasons a validation of the results obtained in older archival specimens may be needed at each institution. Optimization of the TMA technique will also increase the success rate. Therefore, each laboratory should optimally apply a standard procedure for the construction of TMAs. Such an effort could include obtaining a standardized number of core biopsies from the tumors, retrieval of tissue from the periphery as well as the center of the tumor and optimally also from normal surrounding tissue, and to have the TMAs constructed by experienced laboratory personnel. In our experience, the number of successful arrays and stainings thereof increase with increasing experience. The regular arrangement of the arrayed specimens facilitates efficient evaluation of the stained sections and allow for automated array construction and analysis. Automated TMA will probably also minimize the technical problems recognized using manual arrayers. The samples will be automatically positioned at equal levels within the array block, which will presum-

ably reduce the number of folded, or torn arrays as well as the number of empty spots on the TMA sections. The possibility of evaluating multiple samples simultaneously also has the advantage that all specimens are processed under identical conditions in a single experiment, which should facilitate a standardized and homogenous evaluation of the results.

Future perspectives

The impressive number of new candidate markers identified using the novel techniques applied in genomics and proteomics will require evaluation in large and clinically well characterized tumor series in order to diagnose markers with diagnostic, prognostic and therapeutic possibilities. Tissue preservation will in this regard be fundamental in order to evaluate potentially important markers. Many studies investigating molecular markers in various tumor types have been small and have thus not been powered to detect possible clinicopathological associations. Use of multi-tumor TMAs constructed to contain different histopathological tumor types within the array will probably provide a quick and efficient means to evaluate involvement of newly discovered markers in different tumor types. Novel TMA applications, such as microdissection of the core biopsies followed by PCR-based analyses will probably appear. The 200-1000 cells present in a core section will thereby also allow assessment of specific mutations. Furthermore, cell microarrays that contain clusters of cells that express a defined gene product are being developed (Ziauddin and Sabatini 2001). Statistical analyses have traditionally applied individual analysis of each marker, or marker combination. Because of the large amounts of data that are generated in TMA-based studies, investigators may want to consider alternative statistical methods such as hierarchical cluster analysis, which has the advantage of taking the weight of the results into account. Thereby, complex results are converted into a visual format that outlines large-scale patterns and allows presentation of large amounts of data.

Summary

The minute tumor samples obtained using TMA have in several studies been found to reproduce

data obtained from studies of whole-tissue sections and to be sufficiently representative of the tumor to allow establishment of previously identified associations between molecular alterations, pathological characteristics and clinical endpoints. Thereby, TMA data may contribute to the identification of diagnostic profiles and predictive expression profiles. Several large-scale studies have also applied TMA to determine expression patterns using immunohistochemical staining and FISH analysis. The large new cDNA based technologies that allow genome-wide expression studies will put forward a large number of potentially interesting diagnostic as well as prognostic markers and the possibility to combine the different array-techniques is a fundamental step towards the application of novel markers in clinical decision-making. TMA offers a challenging potential to accelerate translational research since it allows rapid evaluation of the basic research findings in different tumor types and marker validation in large and clinically well-characterized tumor materials.

Annette Persson, Kristina Lövgren and Eva Rambech are acknowledged for technical assistance in preparing and staining the TMAs.

- Andersen CL, Monni O, Wagner U, Kononen J, Bärlund M et al. High-throughput copy number analysis of 17q23 in 3520 tissue specimens by fluorescence in situ hybridization to tissue microarrays. *Am J Pathol* 2002; 161: 73-9.
- Bubendorf L, Kononen J, Koivisto P, Schraml P, Moch H et al. Survey of gene amplification during prostate cancer progression by high-throughput fluorescence in situ hybridization on tissue microarrays. *Cancer Res* 1999; 59: 803-6.
- Camp RL, Charette LA, Rimm DL. Validation of tissue microarray technology in breast carcinoma. *Lab Invest* 2000; 80: 1934-49.
- Engellau J, Åkerman M, Andersson H, Domanski HA, Rambech E et al. Tissue-array technique in soft tissue sarcoma; immunohistochemical Ki-67 expression in malignant fibrous histiocytoma. *Appl Immunohist Mol Morphol* 2001; 9: 358-63.
- Fernebro E, Dictor M, Bendahl P-O, Fernö M, Nilbert M. Evaluation of the tissue microarray technique for immunohistochemical analysis in rectal cancer. *Arch Pathol Lab Med* 2002; 126: 702-5.
- Hoos A, Urist MJ, Stojadinovic A, Mastorides S, Dudas ME et al. Validation of tissue microarrays for immunohistochemical profiling of cancer specimens using the example of human fibroblastic tumors. *Am J Pathol* 2001; 158: 1245-51.
- Hoos A, Nissan A, Stojadinovic A, Shia J, Hedvat CV et al. Tissue microarray molecular profiling of early, node-negative adenocarcinoma of the rectum: a comprehensive analysis. *Clin Cancer Res* 2002; 8: 3841-9.
- Howbrook DN, van der Valk AM, O'Shaughnessy MC, Sarker DK, Baker SC et al. Developments in microarray technologies. *Drug Discov Today* 2003; 8: 642-51.
- Kononen J, Bubendorf L, Kallioniemi A, Bärlund M, Schraml P et al. Tissue microarrays for high throughput molecular profiling of tumor specimens. *Nat Med* 1998; 7: 844-7.
- Lee YF, John M, Edwards S, Clark J, Flohr P et al. Molecular classification of synovial sarcomas, leiomyosarcomas and malignant fibrous histiocytomas by gene expression profiling. *Br J Cancer* 2003; 88: 510-5.
- Mucci NR, Akdas G, Manely S, Rubin MA. Neuroendocrine expression in metastatic prostate cancer: evaluation of high throughput tissue microarray to detect heterogenous protein expression. *Hum Pathol* 2002; 31: 406-14.
- Nielsen TO, Hsu FD, O'Connell JX, Gilks CB, Sorensen PHB et al. Tissue microarray validation of epidermal growth factor receptor and SALL2 in synovial sarcoma with comparison to tumors of similar histology. *Am J Pathol* 2003; 163: 1449-56.
- Nocito A, Bubendorf L, Tinner EM, Suess K, Wagner U et al. Microarrays of bladder cancer tissue are highly representative of proliferation index and histological grade. *J Pathol* 2001; 195: 349-57.
- Richter J, Wagner U, Kononen J, Fijan A, Bruderer J et al. High-throughput tissue microarray analysis of cyclin E gene amplification and overexpression in urinary bladder cancer. *Am J Pathol* 2000; 157: 787-94.
- Rimm DL, Camp RL, Charette LA, Costa J, Olsen DA et al. Tissue microarray: a new technology for amplification of tissue resources. *Cancer J* 2001; 7: 24-31.
- Schraml P, Kononen J, Bubendorf L, Moch H, Bissig H et al. Tissue microarrays for gene amplification surveys in many tumor types. *Clin Cancer Res* 1999; 5: 1966-75.
- Torhorst J, Bucher C, Kononen J, Haas P, Zuber M et al. Tissue microarrays for rapid linking of molecular changes to clinical endpoints. *Am J Pathol* 2001; 159: 2249-56.
- Ziauddin J and Sabatini DM. Microarrays of cells expressing defined cDNAs. *Nature* 2001; 41: 107-10.