

## Fracture of fully hydroxyapatite-coated titanium femoral stem of a total hip replacement—a report of 3 cases

Dinesh K Sharma<sup>1</sup>, Stuart Brooks<sup>1</sup>, Stuart Creasey<sup>2</sup> and Brian Lewis<sup>2</sup>

<sup>1</sup>Birmingham Heartlands & Solihull (Teaching) Hospitals, Birmingham, <sup>2</sup>Materials Research Institute, Sheffield Hallam University, Sheffield, UK

Correspondence DKS: dksharma@doctors.org.uk

Submitted 03-07-27. Accepted 04-03-07

Fracture of the femoral stem of a total hip replacement has become an unusual but well recognised complication when using cement. Fracture of the femoral stem in an uncemented total hip replacement is rare, however. We report 3 cases of fracture of the femoral stem (2 of which were done in our hospital and 1 that was referred from outside) with a hydroxyapatite-coated prosthesis where the metal was fully covered by the hydroxyapatite coating.

The femoral prosthesis used was the JRI (Joint Replacement Instrumentation Ltd. or Furlong THR, London, UK), made of wrought titanium alloy with the surface completely covered with vacuum plasma sprayed hydroxyapatite coating. This coating is of 96% purity, has a thickness of 150 microns and a bond strength of 60 Mpa. It is attached to a 50-micron thick porous titanium undercoating. The stem has 3 parts. The rectangular proximal third with a small fin to counteract rotation is placed in the trochanter area. Further distally, there is a cone section to create mechanical stability. The distal portion is cylindrical. The design allows the distal femur to be over-reamed by 2 mm.

### Case 1

A 66-year-old, 91 kg, 180 cm tall man underwent a left total hip replacement for osteoarthritis. A JRI size 9 femoral stem was used. 8 years after surgery, he suddenly developed severe pain in his left thigh on getting out of the car and could not bear weight. Radiographs revealed a fracture of the femoral prosthesis, which was revised (using the same stem design) to femoral stem size 10.

### Case 2

A 58-year-old lady, 170 cm tall and weighing 95 kg had a left JRI total hip replacement, with femoral stem size 9, for osteoarthritis. She remained

asymptomatic but at review 3 years after surgery, a routine radiograph showed a fracture of the femoral stem (Figure 1). Revision was done (using the same stem design) to stem size 11.

### Case 3

A 51-year-old man weighing 85 kg and 175 cm tall had a right JRI total hip replacement, with femoral stem size 10, for osteoarthritis. Some 8 years later he developed pain in his thigh while playing golf, causing him to fall to the ground. Radiographs showed stem fracture. At revision the same type of implant was used, the stem being revised to size 11.

All 3 patients had also had a JRI total hip replacement in their contralateral hip without problems. In all 3 cases, radiographs showed osteolysis proximally and the fracture just distal to the cone of the femoral stem. These stems were subjected to metallurgical analysis

### Surgical technique

All 3 components were retrieved using a hole in the intermedullary canal made distal to the tip of the femoral stem. In each case, the proximal component was loose with osteolysis and had lost all evidence of the hydroxyapatite coating. The distal part of each prosthesis was bonded firmly to the bone. This, in turn, was the cause of difficult revision as it was first separated from the medullary canal by bone gouge and was then removed by punching the component proximally. There was no evidence of infection in any of the cases, based on cultures or clinical assessment.

### Metallurgical analysis

Metallurgical analysis of one of the failed stems (Figure 2) was done using a Philips XL40 scanning electron microscope equipped with an Oxford

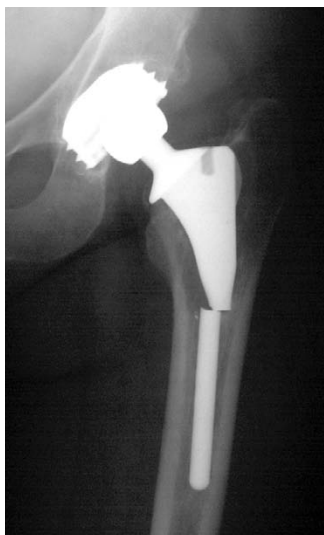

Figure 1. Fracture of femoral stem.

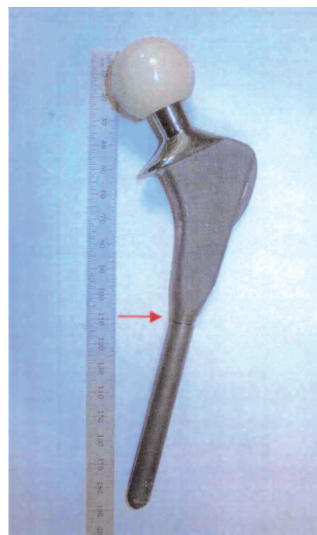


Figure 2. The failed stem as it was received, with the location of the fracture indicated by the arrow at the top of the distal tip. The hydroxyapatite (HA) coating was shown to be lost, which was thought to be due to an infection that generates environmental conditions conducive to dissolution of the coating.

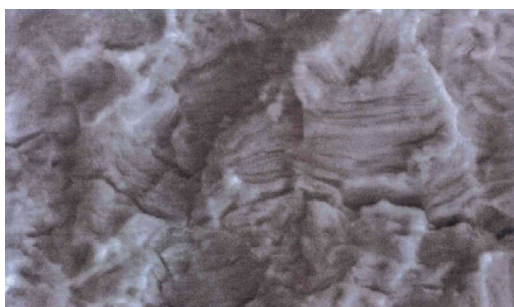


Figure 3. High-resolution SEM image of the fracture surface taken at the central region, where both fine fatigue striations and a number of secondary cracks were evident.

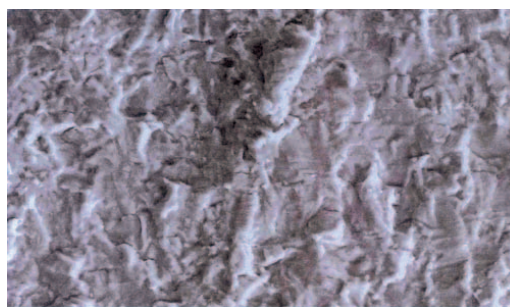


Figure 4. SEM image close to the final failed region, still showing some evidence of fine fatigue striations. This region is generally associated with overload failure, as the stem can no longer support the stresses acting upon it.

Instruments ISIS 300 Energy Dispersive X-ray (EDX Atmospheric Thin Window (ATW) analyser detector system at Sheffield Hallam University Laboratory, Sheffield, UK. Scanning electron microscopy (SEM) imaging by Secondary Electron (SE) was used, as it provided good depth of field topographical images of the fracture surfaces.

EDX analysis was carried out on features of interest such as foreign particles and coating material. It was concluded that failure of the stem at the top of the distal tip was by a mechanism of fatigue. Most of the fracture surface exhibited low material deformation which is associated with fatigue. An initiation site was observed at the surface, which had associated cracking. The presence of fine secondary cracks and fine striation marks (Figures 2 and 3) found on the fracture surfaces also supports

the mechanism of fatigue. Particulate contamination was also found adjacent to the initiation site. The foreign particle was found to be rich in silicon, and was thought to be some form of oxide or possibly silicate material. The particle was not associated with the grit blasting process, as only aluminium particles are used. There were traces of titanium and iron at the same site without any evidence of hydroxyapatite.

## Discussion

The reported incidence of femoral stem failure varies from 0.23% by Charnley (1975) to 0.67% by Carlsson et al. (1977), and to as high as 11% (Martens et al. 1974). Earlier, it was considered that the

main problem was the alloys used to manufacture the femoral stems for cemented total hip replacement. With better cementing techniques, altered femoral component design and alteration in the metallurgy of the femoral components, fracture of femoral components in cemented total hip replacement has become much less frequent.

There have been much fewer case reports of uncemented femoral components fracturing, and these have involved porous coated uncemented total hip replacement (Gilbert et al. 1994). To our knowledge, fracture of the femoral stem in hydroxyapatite-coated total hip replacement has not been reported.

Hydroxyapatite is osteoconductive i.e. it is capable of supporting ingrowths of osteoprogenitor cells into the graft or an implant. This has been well documented in the retrievals (Furlong and Osborn 1991, Hardy et al. 1991) as well as in clinical results (Soballe et al. 1993, Geesink and Hoefnagels 1995, Onsten et al. 1996, McNally et al. 2000). De Groot et al. (1987) found that fatigue fracture occurred commonly in coatings thicker than 100 microns, and bioresorption was unacceptably rapid with coating less than 30 microns. These authors found that the ideal coating thickness of hydroxyapatite to be 50 microns.

The femoral component of the JRI total hip replacement has a high success rate (Geesink and Hoefnagels 1995, McNally et al. 2000). In our series, 2 of 3 cases had their implants for 8 years before the stem failed, whilst 1 had only had the implant for 3 years. In all 3 cases, it appears that the distal part of the prosthesis had bonded to bone, though the proximal part had failed to bond. It is likely that micromovements occurred in the proximal part, eventually causing fracture of the metallic component. The use of hydroxyapatite coating on femoral stems has increased in popularity in recent years. In many cases, only the proximal part of the femoral stem is hydroxyapatite-coated. This raises the question as to whether in the case of this prosthesis, fracture would not have occurred had only the proximal part of the prosthesis been hydroxyapatite-coated. According to the surgical technique, the distal part of the femoral stem of the femur should be over-reamed by 2 mm; however, it is not clear from the literature whether this is recommended to attempt to stop bonding

of the hydroxyapatite distally without proximal incorporation. The only reported complication with hydroxyapatite is hydroxyapatite particulate debris and resultant third-body wear (Bloebaum and Dupont 1993, Bloebaum et al. 1994).

Hydroxyapatite coating of a femoral component may become a significant problem if the proximal part of the femoral component fails to osteo-integrate, causing excess loading on the distal part of the femoral component. This causes subsequent metal fatigue and fracture, leading to difficult surgical revision. We believe that further consideration needs to be taken as to whether a femoral stem should be fully hydroxyapatite-coated or hydroxyapatite-coated only proximally.

We thank Mr. H. Rahman, Consultant Orthopaedic, for contributing one case to this study.

- Bloebaum R D, Dupont J A. Osteolysis from a press-fit hydroxyapatite-coated implant. A case study. *J Arthroplasty* 1993; 8: 195-202.
- Bloebaum R D, Beeks D, Dorr L D, et al. Complications with hydroxyapatite particulate separation in total hip arthroplasty. *Clin Orthop* 1994; (29): 19-26.
- Carlsson A S, Gentz C F, Stenport J A N. Fracture of femoral prostheses in total hip replacement. *Acta Orthop Scand* 1977; 48: 650-5.
- Charnley J. Fracture of femoral prostheses in total hip replacement. A clinical study. *Clin Orthop* 1975; (11): 105-20.
- De Groot K, Geesink R, Klein C P, Serekian P. Plasma sprayed coating of hydroxyapatite. *J Biomed Mater Res* 1987; 21: 1375-81.
- Furlong R J, Osborn J F. Fixation of hip prostheses by hydroxyapatite-coated total hip replacement. *J Bone Joint Surg (Br)* 1991; 73: 741-5.
- Geesink R G T, Hoefnagels N H M. Six-year results of hydroxyapatite-coated total hip replacement. *J Bone Joint Surg (Br)* 1995; 77: 534-47.
- Gilbert J L, Buckley C A, Jacobs J A, et al. Intergranular corrosion-fatigue failure of cobalt-alloy femoral stems. *J Bone Joint Surg (Am)* 1994; 76: 110-5.
- Hardy D C R, Frayssinet P, Guilhem A, et al. Bonding of hydroxyapatite-coated femoral prostheses: Histopathology of specimens from four cases. *J Bone Joint Surg* 1991; 73: 732-40.
- Martens M A R C, Aernoudt E, De Meester P, et al. Factors in the mechanical failure of the femoral component in Total hip prosthesis. *Acta Orthop Scand* 1974; 45: 693-710.

McNally S A, Shepperd J A N, Mann C V, Walczak J P. The result of nine to twelve years of the use of a hydroxyapatite-coated femoral stem. *J Bone Joint Surg (Br)* 2000; 82: 378-82.

Onsten I, Carlsson A S, Sanzen L, Besjakov J. Migration and wear of hydroxyapatite-coated hip prosthesis. A controlled roentgen stereophotogrammetric study. *J Bone Joint Surg (Br)* 1996; 78: 85-91.

Soballe S, Hansen E S, Rasmussen H B, Bunger C. Hydroxyapatite coating converts fibrous tissue to bone around loaded implants. *J Bone Joint Surg (Br)* 1993; 75: 270-8.