

Positive pivot shift after ACL reconstruction predicts later osteoarthritis

63 patients followed 5–9 years after surgery

Håkan Jonsson¹, Katrine Riklund-Åhlström² and Jonas Lind²

Departments of ¹Orthopaedics and ²Diagnostic Radiology, University Hospital of Northern Sweden, Umeå, Sweden

Correspondence HJ: Hakan.Jonsson@orthop.umu.se

Submitted 03-03-08. Accepted 04-02-20

Background Rupture of the anterior cruciate ligament (ACL) may cause osteoarthritis (OA) and functional impairment. We wanted to find out whether the degree of knee stability obtained after ACL reconstruction correlates with radiographic and clinical outcome.

Patients and methods We examined 63 patients 2 and 5–9 years after anterior cruciate ligament (ACL) reconstruction. Knee stability was assessed 2 years after surgery by recording AP laxity using radiostereometric technique (RSA) and by performing the pivot shift test. Degeneration of the knee joint was evaluated with bone scintigraphy, and radiographically. Functional outcome was assessed with Lysholm score, Tegner activity scale and with the one-leg hop test.

Results Radiographic signs of osteoarthritis at the most recent follow-up (5–9 years) did not correlate with knee stability. Patients with positive pivot shift test 2 years after surgery showed increased scintigraphic activity of the subchondral bone at the most recent follow-up, and inferior subjective functional outcome 2 years after surgery. Knees having had meniscus resections had more often OA. Radiographical signs of OA were associated with higher scintigraphic uptake in the operated knee relative to the contralateral knee.

Interpretation The ability to obliterate the pivoting by ACL reconstruction appears to be more important than normalizing the AP laxity in order to prevent later OA.

Anterior cruciate ligament (ACL) rupture may cause osteoarthritis and disability in terms of reduced knee function (Noyes et al. 1983). ACL reconstruction has been advocated to prevent OA and functional impairment (Kannus and Järvinen 1987, Andersson and Gillquist 1992, Hazel et al. 1993, Neyret et al. 1993, Dye and Chew 1994). However, most long-term studies have been retrospective (Lohmander and Roos 1994, Gillquist and Messner 1999). The main aim of the study was to assess whether there is any association between degree of knee stability 2 years after surgery and signs of OA at a later follow-up.

Patients and methods

Between 1984 and 1990, 68 patients (23 women) with mean age 25 (15–40) years and with chronic ACL injuries had an ACL reconstruction (the index surgery) with a quadriceps tendon – patellar tendon strip augmented with a polypropylene braid (Kennedy-LAD, 3M Company) (Marshall et al. 1979, Kennedy et al. 1980). 39 patients had the ACL graft placed over the top on the femoral side (Kennedy et al. 1980, Jonsson et al. 1992) and 29 had it placed isometrically (Odensten and Gillquist 1986, Jonsson et al. 1994). The grafts were fixed to the femur either with two barbed staples, or with a screw and washer. 3 weeks or more before surgery, the patients had tantalum beads implanted into both knees. The mean time between injury and surgery

was 3.6 (0.5–15) years. We examined the patients 2 years and 6.6 (4.9–9.6) years after surgery.

Methods

Pivot shift was graded as being either absent or present. The status of the menisci was retrieved from the most recent surgical report (the index surgery or arthroscopy performed later) of the reconstructed knee and classified as being either no resection or resection (partial to total meniscectomy). Functional outcome was evaluated with the Lysholm score and Tegner activity scale and performance was assessed with the one-leg hop test (quotient reconstructed/contralateral knee) (Tegner and Lysholm 1985, Tegner et al. 1986).

Anterior-posterior (AP) laxity was measured with the knee in 30° of flexion with anterior traction of 150 N and posterior traction of 80 N. The displacement between these endpoints along a line perpendicular to the tibial longitudinal axes was measured using radiostereometric (RSA) technique (Kärrholm et al. 1988b). Side-to-side difference between the operated and the contralateral knee was calculated. To reduce radiation, the AP laxity values of the contralateral knee measured before the ACL surgery were used. Instability was defined as a side-to-side difference of 2.5 mm or more (Jonsson et al. 1993).

A scintigraphic bone study was performed at the latest follow-up. Static images taken 4 hours after injection were obtained. A gamma camera with two detectors and general purpose collimators was used (General Electric, Milwaukee, USA). Images including both knees were obtained in anterior/posterior and medial/lateral views. All images were recorded in a 256 × 256 matrix with 10 min acquisition time. On the scintigraphic pictures of the knees, 3 areas were defined manually. These areas or regions of interest, “ROIs”, covered the entire knee, the medial and the lateral joint compartment. The ROIs were defined in both the AP and lateral-medial projections. In the lateral-medial images, the joint spaces were covered with only one ROI. To analyze the same area in both knees, the ROIs from the operated knee were duplicated and adjusted in localization to fit to the contralateral knee. The geometrical mean was calculated in each region in both knees. Differences between the geometrical means in the different volumes of the

knee were calculated, with the contralateral knee as a reference.

The knees were examined with flexion weight bearing radiographs, AP and lateral views 5–9 years after surgery. Joint spaces were measured medially and laterally. To assess the “normal” joint space distance, 23 of the patients in this study (with no history of injury to the contralateral knees) had both knees investigated. The mean and SD for the joint space distance in the contralateral knees were calculated. A joint space distance less than the calculated mean for the contralateral knees minus 2 SD was regarded as being abnormal in the operated knees. A radiographic evaluation of OA in the operated knees according to Fairbank (1948) was performed blindly. A scale based on Fairbank signs and joint space narrowing was used (Maletius and Gillquist 1997). Grade 0: normal joint space distance and no Fairbank signs; grade 1: normal joint space distance and any of the Fairbank signs (sharpening of edges, beginning of osteophyte formation, sclerosis and flattening of the condyles); grade 2: grade 1 and reduced joint space distance (more than mean minus 2 SD of the contralateral knees) but less than 50% reduction on either the medial or lateral side; grade 3: grade 1 and joint space reduction of 50% or more.

For the quantitative variables, paired or unpaired t-tests and one-way ANOVA were used. Non-parametric tests (Wilcoxon’s signed rank test, Mann-Whitney U-test and Jonckheere-Terpestra test) were used for ordinal and nominal variables. Pearson and Spearman tests and also linear regression were used at a rejection level of 5%.

Results

2 patients who had undergone index surgery could not be found for follow-up. 3 patients who did not want to participate in the follow-up examination were interviewed (Lysholm score and Tegner activity scale). The remaining 63 patients had clinical and radiographic knee examinations and AP laxity tests using RSA technique. 2 patients declined bone scintigraphy, and for 2 patients the scintigraphic data were lost. 9 patients sustained a contralateral ACL injury during the observation time, verified by clinical examination and arthroscopy.

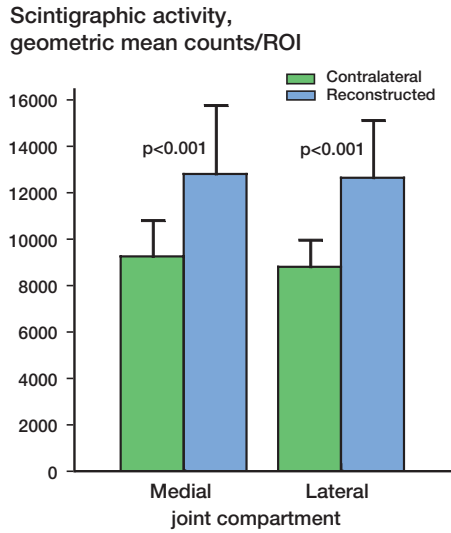


Figure 1. Scintigraphic uptake (geometric mean values and SD) 4 hours after injection over the medial and lateral joint compartment in 51 patients. Comparison between the ACL reconstructed and the contralateral knees. Bilateral ACL injured patients excluded.

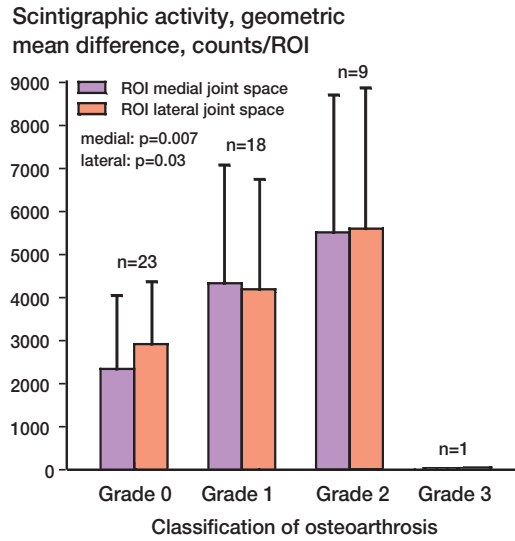


Figure 2. Grading of OA and difference in bone scintigraphic uptake (geometric mean), ACL reconstructed – contralateral knees (mean values and SD) in 51 patients.

They were excluded from calculations including the contralateral knee. 4 of them had an ACL reconstruction performed during the follow-up time. 10 patients were examined with arthroscopy during the observation time. 7 patients had a partial meniscectomy done at the arthroscopy. 2 patients had hardware removed, and 1 had the synthetic graft removed.

The Lysholm score and Tegner activity scale values did not differ between the patients with stable or unstable knees (AP laxity) after two years, or at the most recent follow-up. A slight improvement in the one-leg hop quotient was observed in the unstable group (AP laxity) between two years and the latest follow-up (0.92–0.95, $p = 0.002$). The stable group did not change (0.90–0.92) and the difference at the latest follow-up was not significant. The mean side-to-side difference did not change between 2 years (4.0 mm SD 2.8) and the latest follow-up (4.3 mm SD 3 mm, $p = 0.3$). 2 years after surgery, 18 patients had stable knees and 49 had unstable knees. The corresponding figures at the latest follow-up were 17 and 46.

The reconstructed knees had about 20% higher mean scintigraphic uptake compared to the contralateral knees. The difference in uptake was even higher at the medial and lateral joint space (38%

and 44%, Figure 1). The medial and lateral joint space displayed increased scintigraphic uptake with increased signs of OA (Figure 2). The mean joint space distance on the medial side on the AP view was 5.5 mm (SD 0.7) and on the lateral side 6.8 mm (SD 1.3) in the 23 patients with uninjured contralateral knees. Distances less than 4.1 mm (mean minus 2 SD) on the medial side and 4.2 mm on the lateral side were regarded as abnormal. The OA classification of the patients is presented in Table 1. The scintigraphic difference (reconstructed vs. contralateral knees) was not affected by the time between injury and the latest follow-up in any of the ROIs ($p = 0.1–0.5$, linear regression).

Table 1. Osteoarthritis classification and AP laxity

Osteoarthritis grade	n	Classification	
		Stable ^a ≤ 2.5 mm n (%)	Unstable ^a > 2.5 mm n (%)
0	25	5 (28)	20 (44)
1	26	7 (39)	19 (42)
2	10	5 (28)	5 (11)
3	2	1 (6)	1 (2)
Total	63	18	45

^a side-to-side difference reconstructed–contralateral knee 2 years after surgery

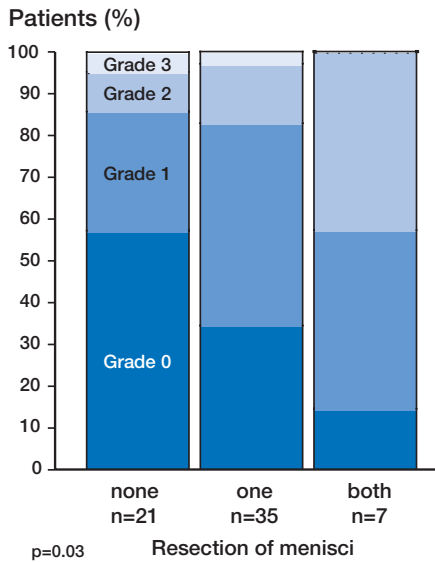


Figure 3. Resection of the menisci and OA grading at follow-up, 5–9 years after surgery.

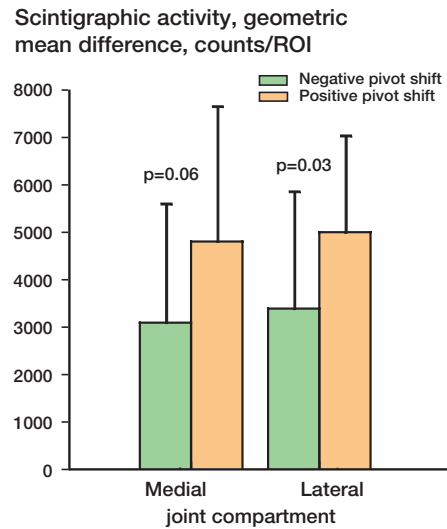


Figure 4. Results of pivot shift test 2 years after surgery in 50 patients and difference in scintigraphic uptake (geometric mean) 5–9 years after surgery. ACL reconstructed – contralateral knees (mean values and SD).

Table 2. Functional outcome 2 years and 5–9 years after surgery (the latest follow-up), and results of pivot shift 2 years after surgery

Functional outcome	Pivot shift test 2 years after surgery			Pivot shift test at the latest follow-up		
	Negative n = 49	Positive n = 17	P-value	Negative n = 49	Positive n = 17	P-value
Lysholm score, median (range)	91 (58–100)	76 (34–100)	0.006	90.5 (52–100)	82 (26–100)	0.02
Tegner activity scale, median (range)	7 (3–10)	5 (0–8)	0.02	7 (3–10)	6 (1–10)	0.1
One-leg hop, mean (SD) ^a	0.92 (0.09) n = 46	0.84 (0.13) n = 17	0.002	0.96 (0.07)	0.92 (0.15)	0.3

^a Ratio, reconstructed/contralateral knee. Bilateral ACL injured patients excluded.

The time between injury and observation did not affect the amount of radiographical signs of OA ($p = 0.3$, Jonckheere-Terpstra test). The patients with more signs of osteoarthritis on the weight bearing radiographs also had had more meniscus resections performed (Figure 3, $p = 0.02$). Resection of the medial meniscus did not affect the scintigraphic uptake difference in the medial joint space ($p = 0.5$). Resection of the lateral meniscus resulted in about 60% higher scintigraphic uptake difference over the lateral joint line compared to the non-resected patients (geometric mean counts/ROI: resected 5028, SD = 2713; intact 3119, SD = 1977; $p = 0.006$).

Patients having a positive pivot shift 2 years after the ACL reconstruction had greater difference in bone scintigraphic uptake at the 5 to 9-year follow-up (Figure 4) over the entire knee (67%, $p = 0.03$), as well as over the lateral (50%, $p = 0.03$) but not over the medial joint space ($p = 0.06$). The radiographic grading of OA at the latest follow-up was not affected by the presence or absence of the pivot shift—either at two years, or at the latest follow-up ($p = 0.1–0.6$). Patients having negative pivot shift test 2 years after surgery had better subjective knee function, activity and performance at the same time, and better knee function at the latest follow-up (Table 2). The pivot shift test at

the latest follow-up did not affect signs of OA, Lysholm score, Tegner activity scale or one-leg hop quotient.

The stable patients (AP laxity) at 2 years did not differ from the unstable ones regarding radiographic signs of OA at the 5 to 9-year follow-up ($p = 0.09$, Table 1). Also, no difference could be observed in bone scintigraphic uptake difference ($p = 0.2$ – 1.0) for the entire knee, or for the lateral or medial joint compartment, between the stable and unstable patients (AP laxity). There was no difference between the patients with stable and unstable knees (two years or at the latest follow-up) regarding signs of OA, Lysholm score, Tegner activity scale or one-leg hop quotient. Meniscus resections, the time between injury and follow-up, or signs of OA did not affect the subjective knee function, activity or one-leg hop quotient.

Discussion

Abnormal pattern of motion in knees with an insufficient ACL (Kärrholm et al. 1988a, Jonsson et al. 1989) as well as episodes of giving-way (Galway and MacIntosh 1980) may result in mechanical osseous trauma and increased scintigraphic uptake in the subchondral bone (Dorchak et al. 1993, Fritschy et al. 1993). The increased scintigraphic uptake at the 5 to 9-year follow-up that we observed in knees with positive pivot shift test recorded 2 years after surgery, indicates the importance of the pivoting for deterioration of the knee joint. Brandson and coworkers (2000) found abnormal knee kinematics in ACL reconstructed knees despite the AP laxity being restored. The pivot shift test seems to reflect pathological knee kinematics better than the AP laxity tests, and thereby the success of ACL surgery. On the other hand, positive pivot shift at the 5 to 9-year follow-up did not imply increased scintigraphic uptake. Other factors such as injury to the menisci and manifest cartilage injuries may, in time, take on greater importance for the bone metabolism.

Meniscal pathology also alters bone metabolism (Mooar et al. 1987, Dorchak et al. 1993). We assumed that resections of the menisci would result in abnormal wear in the corresponding joint compartment, because of increased uptake in the lateral

joint compartment in patients with lateral meniscus resection. Dorschak and coworkers (1993) observed increased scintigraphic uptake in the lateral joint compartment in the ACL injured knees and concluded that the reason was higher loading compared to the medial side. This loading might add to the adverse effects of a resected meniscus in the lateral joint compartment and explain the difference between the compartments seen in our study. The status of the menisci was evaluated from the latest surgical report and not in connection with the scintigraphic examination, thus restricting the conclusions that can be drawn.

Surgery as such also affects bone metabolism in the knee joint. Fritschy and coworkers (1993) observed increased scintigraphic uptake in the ACL-reconstructed knees compared to the contralateral ones, many years after surgery. They considered that the open surgical approach, also used by us, might be responsible for this. Incomplete covering of the synthetic braid by the autologous graft and degradation of the synthetic material inducing an inflammatory process (Dye and Chew 1994) is also a potential risk.

Increased scintigraphic uptake seems to precede radiological signs of OA by many years (Hutton et al. 1986). We found that patients having radiological signs of OA at the latest follow-up also had higher scintigraphic uptake. The AP laxity or the pivot shift at two years, or at the 5 to 9-year follow-up, did not relate to the OA. A follow-up that is too short and a sample size that is too small might explain the lack of association. OA is assumed to be the end result of many adverse factors. Subchondral and cartilage injuries at the time of the ACL injury (Rosen et al. 1991) and meniscal injuries (Fairbank 1948) may be of increasing importance with time. With increasing signs of OA, less of our patients had both menisci intact, which stresses the importance of intact menisci for the long-term fate of the knee. The number of ACL injured patients with radiographic signs of OA increases with time, regardless of the type of treatment (Lohmander and Roos 1994, Gillquist and Messner 1999). We could not confirm any association between time after injury and scintigraphy or radiographic changes, probably due to the sample size being too small and to the follow-up time being too short (Neyret et al. 1993).

This study was supported by the Medical Faculty, University of Umeå, Svenska Läkarsällskapet (the Swedish Medical Society), Centrum för Idrottsforskning (Swedish National Centre for Research in Sports) and the Trygg Hansa Insurance Company. We thank Professor Olle Svensson, Department of Orthopedics, University Hospital of Northern Sweden, Umeå, Sweden, for constructive discussions.

- Andersson C, Gillquist J. Treatment of acute isolated and combined ruptures of the anterior cruciate ligament. A long-term follow-up study. *Am J Sports Med* 1992; 20: 7-12.
- Brandson S, Karlsson J, Swärd L, Kartus J, Eriksson B I, Kärrholm J. Kinematics and laxity of the knee after anterior cruciate ligament reconstruction. Pre and post-operative radiostereometric studies. In: Anterior cruciate ligament injury. Results after reconstruction in terms of function, postoperative pain and kinematics. Thesis, Gothenburg 2000: 116-26.
- Dorchak J D, Barrack R L, Alexander A H, Dye S F, Dresser T P. Radionuclide imaging of the knee with chronic anterior cruciate ligament tear. *Orthop Rev* 1993; 22: 1233-41.
- Dye S F, Chew M H. The use of scintigraphy to detect increased osseous metabolic activity about the knee. *Instr Course Lect* 1994; 43: 453-69.
- Fairbank T J. Knee joint changes after meniscectomy. *J Bone Joint Surg (Br)* 1948; 30: 664-70.
- Fritschy D, Daniel D M, Rossman D, Rangger C. Bone imaging after acute knee hemarthrosis. *Knee Surg Sports Traumatol Arthrosc* 1993; 1: 20-7.
- Galway H R, MacIntosh D L. The lateral pivot shift: a symptom and sign of anterior cruciate ligament insufficiency. *Clin Orthop* 1980; (147): 45-50.
- Gillquist J, Messner K. Anterior cruciate ligament reconstruction and the long-term incidence of gonarthrosis. *Sports Med* 1999; 27: 143-56.
- Hazel W J A, Rand J A, Morrey B F. Results of meniscectomy in the knee with anterior cruciate ligament deficiency. *Clin Orthop* 1993; (292): 232-8.
- Hutton C W, Higgs E R, Jackson P C, Watt I, Dieppe P A. ^{99m}Tc HMDP bone scanning in generalised nodal osteoarthritis. I. Comparison of the standard radiograph and four hour bone scan image of the hand. *Ann Rheum Dis* 1986; 45: 617-21.
- Jonsson H, Kärrholm J, Elmqvist L G. Kinematics of active knee extension after tear of the anterior cruciate ligament. *Am J Sports Med* 1989; 17: 796-802.
- Jonsson H, Elmqvist L G, Kärrholm J, Fufl Meyer A. Lengthening of anterior cruciate ligament graft. Roentgen stereophotogrammetry of 32 cases 2 years after repair. *Acta Orthop Scand* 1992; 63: 587-92.
- Jonsson H, Kärrholm J, Elmqvist L G. Laxity after cruciate ligament injury in 94 knees. The KT-1000 arthrometer versus roentgen stereophotogrammetry. *Acta Orthop Scand* 1993; 64: 567-70.
- Jonsson H, Elmqvist L G, Kärrholm J, Tegner Y. Over-the-top or tunnel reconstruction of the anterior cruciate ligament? A prospective randomised study of 54 patients. *J Bone Joint Surg (Br)* 1994; 76: 82-7.
- Kannus P, Järvinen M. Conservatively treated tears of the anterior cruciate ligament. Long-term results. *J Bone Joint Surg Am* 1987; 69: 1007-12.
- Kärrholm J, Selvik G, Elmqvist L G, Hansson L I. Active knee motion after cruciate ligament rupture. Stereoradiography. *Acta Orthop Scand* 1988a; 59: 158-64.
- Kärrholm J, Selvik G, Elmqvist L G, Hansson L I, Jonsson H. Three-dimensional instability of the anterior cruciate deficient knee. *J Bone Joint Surg (Br)* 1988b; 70: 777-83.
- Kennedy J C, Roth J H, Mendenhall H V, Sanford J B. Presidential address. Intraarticular replacement in the anterior cruciate ligament-deficient knee. *Am J Sports Med* 1980; 8: 1-8.
- Lohmander L S, Roos H. Knee ligament injury, surgery and osteoarthritis. Truth or consequences? *Acta Orthop Scand* 1994; 65: 605-9.
- Maletius W, Gillquist J. Long-term results of anterior cruciate ligament reconstruction with a Dacron prosthesis. The frequency of osteoarthritis after seven to eleven years. *Am J Sports Med* 1997; 25: 288-93.
- Marshall J L, Warren R F, Wickiewicz T L, Reider B. The anterior cruciate ligament: a technique of repair and reconstruction. *Clin Orthop* 1979; (143): 97-106.
- Mooar P, Gregg J, Jacobstein J. Radionuclide imaging in internal derangements of the knee. *Am J Sports Med* 1987; 15: 132-7.
- Neyret P, Donell S T, Dejour H. Results of partial meniscectomy related to the state of the anterior cruciate ligament. Review at 20 to 35 years. *J Bone Joint Surg (Br)* 1993; 75: 36-40.
- Noyes F R, Matthews D S, Mooar P A, Grood E S. The symptomatic anterior cruciate-deficient knee. Part II: the results of rehabilitation, activity modification, and counseling on functional disability. *J Bone Joint Surg (Am)* 1983; 65: 163-74.
- Odensten M, Gillquist J. A modified technique for anterior cruciate ligament (ACL) surgery using a new drill guide for isometric positioning of the ACL. *Clin Orthop* 1986; (213): 154-8.
- Rosen M A, Jackson D W, Berger P E. Occult osseous lesions documented by magnetic resonance imaging associated with anterior cruciate ligament ruptures. *Arthroscopy* 1991; 7: 45-51.
- Tegner Y, Lysholm J. Rating systems in the evaluation of knee ligament injuries. *Clin Orthop* 1985; (198): 43-9.
- Tegner Y, Lysholm J, Lysholm M, Gillquist J. A performance test to monitor rehabilitation and evaluate anterior cruciate ligament injuries. *Am J Sports Med* 1986; 14: 156-9.