

Catastrophic failure of an uncemented acetabular component due to high wear and osteolysis

An analysis of 154 Omnifit prostheses with mean 6-year follow-up

Thord von Schewelov, Lennart Sanzén, Ingemar Önsten and Åke Carlsson

Department of Orthopedics, Malmö University Hospital, SE-205 02 Malmö, Sweden

Correspondence TvS: Thord.von_Schewelov@orto.mas.lu.se

Submitted 03-05-24. Accepted 03-11-16

Background The purposes of this study were (1) to evaluate the wear pattern of the hydroxyapatite-coated “Dual Radius” Omnifit cup, (2) to investigate whether wear is correlated to any demographic or prosthesis-related factors, and (3) to describe micromotion of both the cup and the stem.

Patients and methods 154 hips were implanted between 1990 and 1996 and followed for an average of 6 years. Wear was measured according to the “Charnley-duo” method and, in 79 hips, with radiostereometry (RSA). RSA was also used to evaluate micromotion. We analyzed the femoral heads using scanning electron microscopy, energy dispersive X-ray spectroscopy and an atomic force microscope.

Result 66 cups were revised and had a mean annual wear of 0.32 mm compared to 0.12 mm in hips not revised. Osteolytic processes were observed in 35 hips but at revision osteolysis was present in 51 cases. 43/66 sockets were loose. Micromotion evaluated by RSA, weight, age, side, size of cup, screws, polyethylene thickness or shelf-life of the polyethylene did not correlate to wear, whereas male gender did.

Interpretation It is still unclear why about half of our cases had an abnormal wear rate. Annual wear exceeding 0.2 mm is prognostic of late failure and should be considered a warning sign.

Multicentre clinical trials of the hydroxyapatite-coated Omnifit prosthesis (Stryker Howmedica Osteonics) commenced in 1987. The main and excellent long-term clinical and radiographic

outcome has been reported (Manley et al. 1998, D’Antonio et al. 2001). The HA-coated Omnifit cup was manufactured with three designs—“Dual Radius”, “Dual Geometry” and as a “Screw cup”. The company also manufactured an uncoated “microstructured” Omnifit cup (Figure 1). All of these cups had the same type of polyethylene insert and the same locking mechanism. Of the three designs, only the screw cup has proved to have an acceptable revision rate, whereas the revision rate for the other designs has been high (Table 1). Here we report the first analysis of the micromotion of the Omnifit stem and the Omnifit “Dual radius” cup, the survival rates and the wear pattern of the polyethylene insert.

Patients and methods

From 1990 to 1996, 154 consecutive primary, Omnifit total hip replacements were performed on 146 patients (75 women). 8 patients were operated bilaterally. Their mean age at the time of operation was 50 (19–83) years and their mean body weight was 76 kg.

In 109 hips the diagnosis was primary arthrosis, and in 45 cases it was secondary arthrosis. In the latter group 7 were caused by avascular necrosis, 12 by Perthes’ disease, 3 (2 patients) by physeolysis, 7 by complications after a fracture of the proximal femur, 2 by an acetabular fracture and 4 hips by septic arthritis. There were also 10 dysplastic hips, 5 of which had been treated with an oste-




Figure 1. Omnifit HA-coated Dual radius (a), Dual geometry (b) press fit cups, HA-coated threaded cup (c) and porous-coated (microstructured) press fit cups, available as Dual radius (d) and Dual geometry (e) designs. Omnifit stem (f).

Table 1. Results of the different Omnifit acetabular components from different centers

Acetabular component study	Mean FU (years)	Revisions/total number (%)	Osteolysis ^a (pelvis and/or femur)	Annual wear (mm/year)
HA-coated press fit				
Manley 1998 ^b	7.9	41/188 (22)	Min. 12%	nr
D'Antonio 2001 ^b	11	33/116 (28)	13% ^c	nr
Present study	6.3	66/154 (43)	38%	0.20
Porous-coated press fit				
Manley 1998	7.9	7/109 (6)	Min. 7%	nr
D'Antonio 2001	11	6/99 (6)	13% ^c	nr
D'Lima 1999	3.5	0/59 (0)	0%	0.19
Hsieh 2002	10	7/173 (4)	Min. 28%	0.15
HA-coated threaded				
Manley 1998	7.9	4/131 (3)	2%	nr
D'Antonio 2001	11	9/143 (4)	13% ^c	nr

^a Radiographic osteolysis rate in pelvis and/or femur

^b Partly the same material

^c 13% is the rate of osteolysis in the total material of 358 cups, but the distribution is not reported.

nr not reported

otomy of the proximal femur. During hip replacement, 2 dysplastic hips had a structural autograft from the femoral head fixated to the lateral edge of the acetabulum.

2 hips were reoperated within 3 weeks, to prevent dislocation because of an inclination of the cup that was too steep (58° and 67°). As these reoperations were uneventful, the patients were included in the material. 14 patients were lost to

follow-up—7 because of death unrelated to the hip replacement, 4 because the patients had moved abroad and 3 because the patients refused further examination; they were monitored at their last control examination.

Examinations within 1 week postoperatively, after 3 and/or 6 months, 1, 2, 3, 4, 5, 7 and 10 years included a clinical assessment, radiography, and in 79 hips radiostereometric analysis. The mean

follow-up time at the last examination or at the last examination before revision was 6 (0.5–12) years. For the clinical evaluation, we used the Harris (1969) hip score.

The radiographic examination included an AP view of the hip and pelvis and a lateral view of the hip. The films were scrutinized simultaneously by 2 of the authors (ÅC and TvS). Progressive and nonprogressive radiolucent lines were looked for in the acetabulum according to DeLee and Charnley (1976), and in the femur they were evaluated according to Gruen et al. (1979). Osteolytic processes and a change of position of either component were looked for, both in the pelvis and the femur. Bone apposition and signs of instability of the stem were evaluated according to Engh et al. (1990).

Prosthesis and operative technique

3 surgeons (ÅC, LS and IÖ) performed the operations in a clean-air enclosure. Systemic antibiotics were used routinely. The patients were operated on in the supine position and the hip exposed through a lateral approach without trochanteric osteotomy.

The Omnifit, press fit, Dual radius cup (Figure 1) (Stryker Howmedica Osteonics) has a metallic shell of titanium alloy with multiple holes for additional screw fixation. The unused holes were not plugged. According to the manufacturer, the surface was plasma sprayed to give a 50 µm covering of hydroxyapatite of >97% purity, <3% porosity, >70% crystallinity and with a Ca/P ratio of 1.7. 1 screw was used in 19 cases, 2 in 19 cases and in the remaining 116 hips no screws were used. The acetabulum wasreamed to the same size as the smaller of the two diameters of the socket. Shells with 42–62 mm (median 54) diameters were used. The polyethylene inserts were beveled at 10° to the plane of the opening of the shell. A metallic wire connected to 4 hooks in the shell secured the liner. The mean polyethylene thickness was 10.8 (6.1–15.6) mm. The PE inserts, made from base resin GUR 415, had been irradiated and stored in air.

A modular Omnifit stem made from the same titanium alloy as the cup and with a Morse taper was used. The proximal one-third of the stem was covered with plasma-sprayed hydroxyapatite of the same characteristics as for the shell. The stem was inserted after slight underreaming of the

Table 2. RSA limits for significant movement at a 99% confidence limit for migration (mm), rotation (degrees) and wear (mm), according to Önsten (1998)

	Longitudinal	Transverse	Sagittal	Total
Migration				
Socket	±0.2	±0.2	±0.3	
Stem	±0.2	±0.2	±0.5	±0.5
Rotation				
Socket	±0.7	±0.7	±0.3	
Wear				±0.2

femoral canal. A 26-mm modular cobalt–chrome head was used.

Radiostereometric analysis (RSA)

Throughout the whole study period, patients scheduled for Omnifit total hip arthroplasty were asked to participate in the RSA study, provided they were otherwise healthy and that the diseased hip was considered suitable for receiving uncemented components. In the pelvic bone and the proximal femur, about 8 tantalum beads 0.8 mm in diameter were inserted in 79 hips (76 patients) at the index operation. The polyethylene liner was marked with 9 0.8-mm beads. RSA was performed with the patient in supine position using the uniplanar technique (Selvik 1989). Motion of the socket was evaluated relative to the pelvic bone. Motion of the femoral head was evaluated relative to the proximal femur. Wear of the polyethylene was calculated as the displacement of the femoral head in relation to the socket. The latter displacement was calculated both as proximal and total displacement, i.e., the length of the resulting vector. Limits for significant movements and wear, including 99% confidence intervals, have been reported (Önsten et al. 1998) (Table 2). The ethics committee of our university approved this part of the study.

In Table 3, the number of examinations after each time interval is presented as well as the accumulated number of revised RSA hips at each time point. Due to dislocation after 18 and 46 months, 2 patients were reoperated in order to implant a head with a longer neck. As this did not affect the radiostereometric cup migration or wear, they remained in the study, but the 2 stems were excluded after the revision.

Table 3. Mean RSA values for migration (mm) and rotation (degrees) of 78 acetabular and 79 femoral components. Last RSA follow-up after a mean of 65 (23–126) and 64 (12–126) months, respectively. 1 SD shown within brackets

Months	3	6	12	24	36	48	60	84	Last
n	37	26	71 (1)	74 (2)	68 (5)	61 (8)	54 (18)	32 (33)	78 (39)
Acetabular components									
Transverse migration	0.13	0.17	0.16	0.22	0.19	0.25	0.27	0.36	0.27
SD	(0.11)	(0.30)	(0.16)	(0.33)	(0.19)	(0.30)	(0.36)	(0.39)	(0.31)
Longitudinal migration	0.13	-02	0.08	0.08	0.05	0.12	0.29	0.16	0.15
SD	(0.09)	(0.12)	(0.26)	(0.26)	(0.24)	(0.41)	(0.42)	(0.66)	(0.52)
Sagittal migration	0.17	0.21	0.23	0.23	0.30	0.29	0.38	0.47	0.42
SD	(0.22)	(0.37)	(0.29)	(0.30)	(0.45)	(0.48)	(0.54)	(0.81)	(0.70)
Transverse rotation	0.47	0.36	1.05	0.93	0.87	1.02	1.10	1.36	1.37
SD	(0.39)	(0.29)	(4.38)	(2.00)	(1.65)	(2.55)	(2.42)	(2.16)	(2.59)
Longitudinal rotation	0.41	0.36	0.66	1.01	0.64	0.96	1.08	1.15	1.14
SD	(0.39)	(0.35)	(1.72)	(3.09)	(1.15)	(1.95)	(2.03)	(1.81)	(2.02)
Sagittal rotation	0.23	0.47	0.40	0.60	0.79	0.96	1.06	1.11	1.43
SD	(0.35)	(0.88)	(0.66)	(1.01)	(1.89)	(1.94)	(2.40)	(2.31)	(2.94)
Femoral components									
Transverse migration	0.18	0.20	0.22	0.24	0.27	0.28	0.24	0.36	0.30
SD	(0.13)	(0.14)	(0.22)	(0.24)	(0.20)	(0.24)	(0.24)	(0.45)	(0.33)
Longitudinal migration	0.24	0.25	0.28	0.31	0.32	0.34	0.35	0.51	0.37
SD	(0.33)	(0.28)	(0.40)	(0.40)	(0.40)	(0.42)	(0.41)	(0.72)	(0.63)
Sagittal migration	0.27	0.33	0.30	0.38	0.37	0.42	0.46	0.74	0.46
SD	(0.26)	(0.30)	(0.35)	(0.48)	(0.48)	(0.46)	(0.50)	(0.84)	(0.66)
Total	0.46	0.54	0.56	0.66	0.71	0.75	0.76	1.04	0.84
SD	(0.23)	(0.34)	(0.55)	(0.66)	(0.61)	(0.60)	(0.62)	(1.14)	(0.97)

Last = Last RSA examination or last examination before revision. All values are presented as absolute except the longitudinal (Y) values, which are presented as signed. A positive longitudinal value indicates distal migration. n = number of measurable hips, with the accumulated number of revisions within brackets.

Wear measurements using the Charnley-Duo technique

The AP radiographs made 2–7 days postoperatively and the last radiographs were scanned in a Vidar VXR-12 plus film digitizer (Herndon, USA). We used Imagika (CMC Corp., Upper Saddle River, USA) software and designed a program to measure the shortest distance between the edge of the head and the edge of the cup. Wear was calculated by subtracting this distance in the latest examination from that in the first examination, according to the Charnley Duo method (Charnley and Halley 1975). The mean of three measurements on each film was used.

Shelf life

The date of production of the polyethylene liner was identified with the help of the producer. The time elapsed between production and the index operation was called the “shelf life”, and we correlated this shelf life to annual wear, measured according to the Charnley-Duo method.

Technical analysis of the femoral head

To further analyze the reason for the unexpected wear characteristics, we performed a pilot study. The investigation was performed at the Institute for Product Development, Lyngby, Denmark. To ascertain that the unused heads were exactly similar, two unused heads of the same design as those used in this study were compared to two unused Charnley Elite heads (DePuy, Leeds, England) regarding surface characteristics and roundness. Scanning electron microscopy (SEM) and energy dispersive X-ray spectroscopy (EDAX) analyses were performed to search for surface contamination. An atomic force microscope (AFM, Dualoscope) (DeChiffre et al. 1996) was used for surface characterization. Two areas, without apparent damage from the revision operation, were identified around the equator of each ball by light microscopy. These areas were then analyzed with four AFM scans. The mean roughness of the surface (Ra) was recorded as the arithmetic mean value of the surface roughness with reference to

Table 4. Number of cups revised due to loosening, osteolysis, wear or combinations thereof. The group “not revised” includes hips revised for other reasons, such as dislocation. Pain at last follow-up or before revision implies that the Harris pain score was less than the possible 44 points

	Total no.	No. measured	No. with pain	Linear wear ^a mm mean (SD) range	Annual wear ^b mm mean (SD) range	Annual wear > 0.2 mm ^b	Osteolysis ^c rad./rev.	Loose ^c rad./rev.
Revisions	66	61	54	1.83 (1.62) –0.14 to 9.36	0.32 (0.24) –0.05 to 0.92	41	35 / 51	26 / 43
Scheduled for revision	5	5	4	1.15 (1.00) 0.36 to 2.73	0.14 (0.16) 0.04 to 0.30	1	3 /	2 /
Not revised	83	77	13	0.72 (0.58) –0.46 to 2.25	0.12 (0.12) –0.09 to 0.32	12	3 ^d /	–
Total	154	143	71	1.20 (1.26) –0.46 to 9.36	0.20 (0.20) –0.09 to 0.92	54	41	51

^a Linear wear at last examination, mm (SD) range as measured by the Charnley-Duo method.

^b Wear as measured by the Charnley-Duo method.

^c Osteolysis and mechanical loosening identified at last radiography/revision

^d Patients declined revision but they were followed regularly.

a least-squares plane. The difference between the lowest and the highest peak of the surface was measured (Ry). We used AFM for the surface characterization of 12 excised heads. Two of the excised heads with large roughness values were analyzed by AFM profile analysis and SEM including EDAX to find possible traces of Ca and P, which are constituents of hydroxyapatite. One each of the new Charnley and Omnifit heads was analyzed for roundness at the Center for Geometric Metrology (the Technical University of Denmark). Roundness was analyzed with an instrument with a rotating pick-up in accordance with procedure RC-502, in a plane around the equator of the head and in two planes 7° to each side of the equator.

Statistics

The chi-squared test, the t-test, the Spearman rank order correlation, the Pearson correlation and analysis of covariance using logarithmic transformations were used for the statistical evaluation. As only 8 patients were operated on bilaterally, all hips were reported as independent observations.

Results

1 hip was reoperated due to ectopic bone formation, and 2 hips due to recurrent dislocations. In the 2 latter cases the original head was exchanged for a head with an extended neck. These 3 hips are not included in the following results as “revisions”.

Clinical results

58 of the 71 cases that had undergone, or were scheduled for, cup revision had a Harris pain score of 40 or less prior to revision. Thus, 13 patients in this group were painless but they were operated on because of osteolysis and/or excessive wear. In the group of 83 cases who had not undergone cup revision, 70 had no pain, whereas 13 had a Harris pain score ranging between 20 and 40. 1 hip underwent exchange of the stem but not the cup. This latter case is described below.

Cup revisions (Table 4)

66 acetabular components have been revised after a mean of 75 (7–150) months. In addition, 5 hips are scheduled for cup revision. In all of these cases, the reason was wear, loosening, osteolysis or a combination thereof. 43 hips were judged to be loose at revision. 51 hips had pelvic osteolysis and 40 liners were noticeably worn. 1 patient sustained an acetabular fracture as a consequence of no more than a very mild trauma. The fracture was fixed with a reconstruction plate. As the fracture was most likely due to pelvic osteolysis, we included this hip. 43/66 revised cups were bone grafted, 7 with structural grafts and the remainder with morselized allografts. The acetabular components were changed to cemented Charnley Ogee cups (DePuy, Leeds, UK) in 35 hips, uncemented Trilogy cups (Zimmer Inc., Warsaw, Indiana) in 29 hips and a new Omnifit cup in 1 hip. In 1 case, only the liner was changed, while the metallic shell was fixed to the underlying bone.

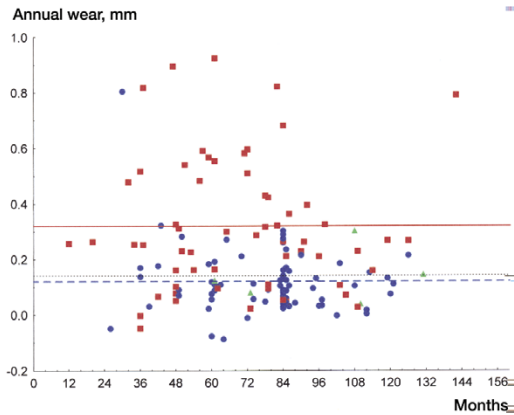


Figure 2. Annual wear in mm (Charnley-Duo) at last follow-up of 143 cups. The lines represent mean annual wear. Not revised (broken line), revised (full line), and pending revision (dotted line).

At revision we regularly changed the modular head to a new one of 22 mm or 28 mm diameter.

Stem revisions

Only 1 stem was exchanged because of thigh pain, radiographic cortical atrophy and suspected osteolysis along almost the whole stem. This failure was most likely aseptic, as all 10 intraoperative cultures were negative. At the revision, we found the stem to be well fixed but it had migrated 0.45 mm distally, as measured by RSA, after 3 years. The new stem was fixated with bone cement and without the need of grafts.

Radiographic and RSA observations

Cup. At the radiographic evaluation, 28 cups were deemed to be loose. All of these cases had been revised or were scheduled for revision. At revision we judged 43 to be loose, and thus 15 cases of cup loosening were not diagnosed by our radiographic evaluation.

Radiolucent lines were seen in 22 hips, 21 of which were revised or waiting for revision. The radiolucent lines were present in zone 1–3 in 20 hips, and in zone 1–2 in two hips.

RSA showed that compared to the results at 24 months (Önsten et al. 1995), migration values along the longitudinal and sagittal axes, as well as rotation values around the transverse and sagittal axes, had doubled at 65 months (Table 3).

Osteolysis. Osteolysis, either in the pelvis or the proximal part of the femur, was observed in the

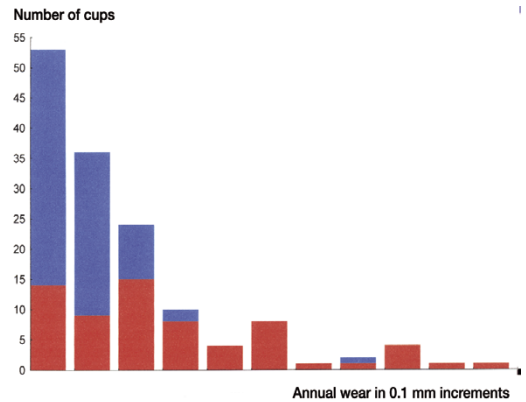


Figure 3. Annual wear in mm (Charnley-Duo) at last follow-up of 143 cups. Frequency distribution within 0.1 mm increments. Red part of bar represents revisions, or cases pending revision.

pre-revision radiographs in 35 of the 67 revised hips but intraoperatively in 51 cases. Thus, in 16 hips osteolysis could not be detected in the radiographs. Osteolysis was seen in all zones around the socket (zone 1: 15, 2: 20, 3:12). In 6/38 cases in which screws had been used, the osteolytic process seemed to follow the screws. In the 87 non-revised cases, osteolysis was observed in 3 cases only. These patients have been given the option of a revision but have decided to wait.

Osteolysis in the proximal part of the stem was observed in 20 hips and was usually seen medially along the resected neck of the femur and in the greater trochanter (Gruen zones 1 and 7). In 8/20 cases with osteolysis in the proximal femur, osteolysis was also observed in the pelvis. 8 of these 20 hips have had the cup revised or are waiting for revision.

Wear. Using the Charnley-Duo method, the mean annual wear rate at the last follow-up examination ($n = 143$) was 0.20 (-0.09–0.92) mm/year. The mean annual wear rate in the non-revised group was 0.12, as compared to 0.32 mm/year in the revised hips ($p < 0.001$) (Table 4, Figure 2). Frequency distribution for annual wear as measured by the Charnley Duo method is presented in Figure 3.

Multiple covariance analysis of annual wear, as measured by the Charnley-Duo method, showed that women had a significantly lower annual wear rate ($p = 0.03$). No correlation was found regarding weight ($p = 0.7$), age ($p = 0.06$), side ($p = 0.2$),

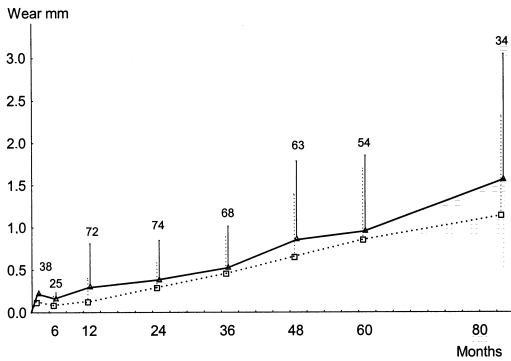


Figure 4. RSA values for wear along the longitudinal axis (full line, signed values). Total vector wear (dotted line). Whiskers represent 1 SD. The number above each whisker shows how many cases were measured after each time interval.

size of the cup ($p = 0.1$), use of screws ($p = 0.5$), polyethylene thickness ($p = 0.2$) or shelf life of the polyethylene ($p = 0.6$).

At the last follow-up investigation (mean 64 months, $n = 78$), the mean wear along the longitudinal axis (Y) was 0.90 (-1.04–5.89) mm and the total vector wear was 1.22 (0.09–6.08) mm. The annual total vector wear was 0.22 (0.02–0.88) mm/year (Figures 4 and 5).

The mean annual wear (Charnley-Duo method) for the 38 sockets found to be loose at revision was 0.30 (0.05–0.92) mm, and it was 0.36 (0.01–0.82) mm for the 24 sockets judged to be stable at revision. No statistically significant correlation was found between micromotion (RSA) along or rotation around any of the axes and annual wear (Spearman correlation, $R = 0.01$ –0.14, $p = 0.2$ –0.9).

Femur. The fixation score, according to the criterion of Engh et al. (1990), was 9.9 (5–10). 4 stems got a reduced score due to lack of spot welds. The stability score was 16 (8.5–17). Two stems had migrated in a distal direction and one hip had an undetermined pedestal formation with unfixed end. Neither of these cases had any pain, nor complications.

There was no major radiostereometric difference in migration of the stem along any of the axes after a mean of 64 months compared to the result in our earlier report (Önsten et al. 1995) or the result in this study after 24 months (Table 3). With the one exception described under the heading “Revisions”, the Omnifit stems had no tendency to migrate with time.

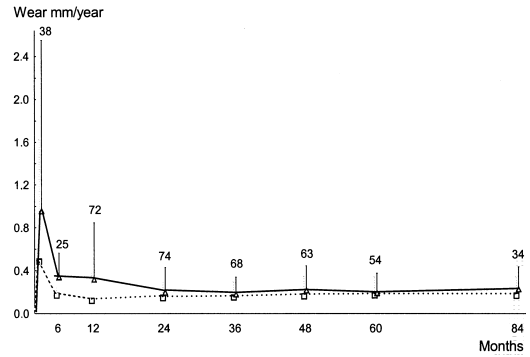


Figure 5. RSA annual wear in mm. Wear along the longitudinal axis (red, signed values). Total vector wear (blue). Whiskers represent 1 SD. The number of measured cases after each time interval is given above each whisker.

Shelf life of the polyethylene. The mean shelf life was 14 (1–64) months. Only 1 liner had been stored longer than 36 months. We found a statistically weak correlation between shelf life and annual wear ($R = 0.26$, Pearson correlation, $p = 0.05$). The multiple covariance analysis did not confirm this finding ($p = 0.6$).

The surface of the femoral head. The “out-of-roundness” for the two types of unused femoral heads differed slightly. The mean deviation from roundness in all three planes for the Omnifit head was 1.52 μm (range 1.41–1.61, uncertainty 34–38%), and for the Charnley head it was 0.94 μm (range 0.74–1.02, uncertainty 55–67%). The out-of-roundness diagram appears asymmetrical (Figure 6).

In unused Omnifit and Charnley Elite femoral heads there was no difference regarding the surface roughness (Ra) (Figure 7), although SEM and AFM demonstrated a difference in surface texture. The Omnifit heads were characterized by polishing marks that were not as prominent on the Charnley heads. The Charnley heads were instead characterized by small holes. The EDAX analysis revealed particles of cobalt, chrome, iron and aluminum on both types of heads. Aluminum particles were probably remnants from the polishing process. Titanium particles were found on one Omnifit head.

Although microscopically undamaged areas on the excised Omnifit heads were selected, structural changes were present at the nanometer level (Figure 7). The profile analysis of the excised

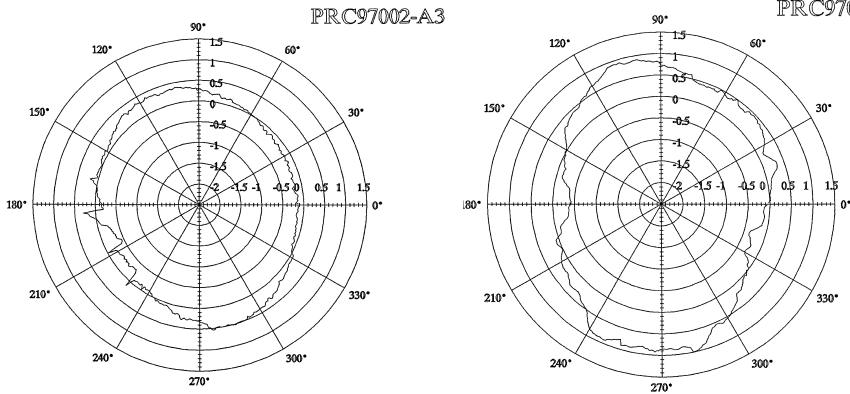


Figure 6. Diagram of roundness at the equator for new Charnley (left) and Omnifit (right) heads (micrometer).

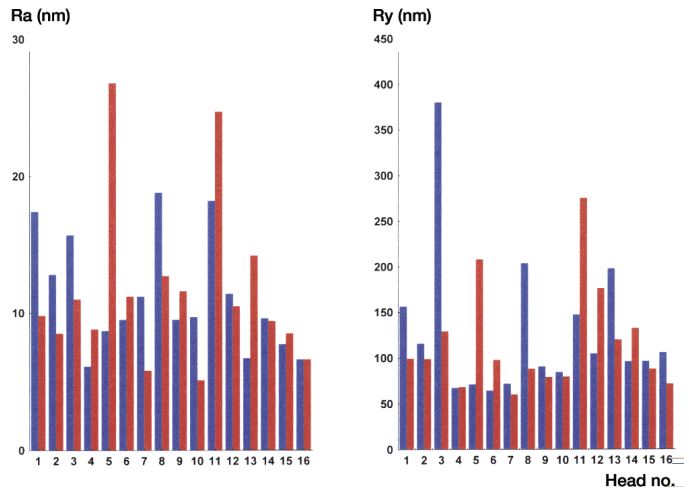


Figure 7. Mean surface roughness. Ra the arithmetic mean value of surface roughness with reference to a least squares plane. Ry difference between the lowest and the highest peak of the surface. Implants 1–12 are excised heads. Numbers 13–14 are new Omnifit and 15–16 are new Charnley heads.

heads numbers 5 and 11 showed deep grooves surrounded by banks. EDAX analysis of these two heads showed traces of potassium, chloride, copper, sulfur, calcium, aluminum and titanium. No traces of phosphorus were found on these two heads.

Discussion

Revisions

Due to the extremely high failure rate of the uncemented and HA-coated Omnifit prosthesis, with a mean time to revision of only 6 years for 66 of our 154 cases (44%), the design has not been used at our clinic since 1996. With one exception, all failures occurred on the acetabular side due to wear

and/or osteolysis and/or loosening related to high PE-wear.

The metal shell of the modular Omnifit cup has been produced with several outer configurations, but all of them have the same polyethylene insert and the same locking mechanism (Figure 1). A summary of clinical studies on all these variants of the sockets is presented in Table 1. From the American-European multicentre study (Manley et al. 1998, D'Antonio et al. 2001) the lowest revision rates (3–6%) have been reported for the “HA-coated threaded” and the uncoated “porous pressfit” type of the Omnifit cup. In these studies the HA-coated pressfit version of the Omnifit cups had a revision rate of 22–28%. In our study, with a similar length of follow-up, the revision rate was still higher, namely 44%.

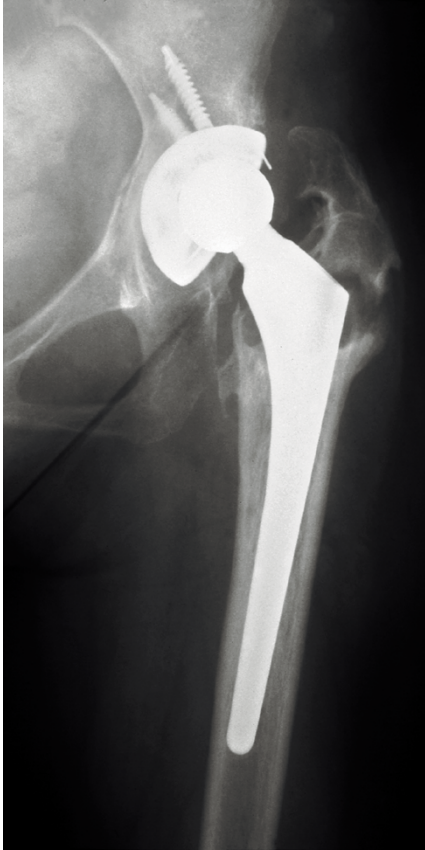

Figure 8. 11 years postoperatively, showing massive osteolysis in the pelvis and trochanter. The tip of the trochanter has fractured spontaneously.

The uncemented Omnifit stem performed well in our series, as in a multicentre study involving 380 cases (D'Antonio et al. 2001). Only 1 stem was revised due to pain and "cortical atrophy". Similar cases have been reported by others (Buma and Gardeniers 1995, D'Antonio et al. 2001).

Wear rates

Only two studies on the wear rate have been presented for the Omnifit prosthesis (D'Lima et al. 1999, Hsieh et al. 2002). Both of these studies were on the "porous pressfit" cup design and with mean annual wear rates of 0.19 and 0.15 mm, respectively, i.e., of about the same size as in our study on a non-porous pressfit, but HA-coated design. In the study by D'Lima et al. (1999) the time of observation was only 3 years, but in the study by Hsieh et al. (2002) the observation period was 10 years. In

the latter report, 7 of 173 acetabular components were revised. Pelvic osteolysis was observed in only 9%, but 28% had osteolysis in the femur. Mean annual wear was 0.15 mm and wear exceeding 0.2 mm was observed in one-third of the cases (Hsieh et al. 2002). Thus, future revisions can be predicted in this group of patients. D'Lima et al. (1999) reported an annual wear rate of 0.17 mm in "Porous coated pressfit" cups. This cup differs from the Omnifit, press fit, Dual radius cup in our study by lacking HA and having a microstructured surface, but a high wear rate is obviously a problem nevertheless. The publications on HA-coated and threaded Omnifit cups contain no information on wear rates (Table 1).

We also measured wear by the RSA technique. The annual total wear at the last follow-up was 0.22 mm (SD 0.21), which is significantly higher than the 0.1 mm rate found in a series of Charnley arthroplasties with a 22.2 mm head made of stainless steel (Önsten et al. 1998). Also in a series of uncemented Harris-Galante I cups combined with a 22.2 mm Charnley stem, the annual wear rate averaged 0.1 mm (Önsten et al. 1998). For other prosthesis designs with a 28 or 32 mm head, annual wear, measured by the same method, has ranged from 0.07–0.13 mm (Franzén and Mjöberg 1990, Kärrholm et al. 1994, Nivbrant and Kärrholm 1997). Thus, these latter values also are clearly lower than in our study.

The majority of the revised sockets had considerably increased annual wear rate, whereas the corresponding value in unrevised cups in the majority of the cases had a "normal" wear rate (Dumbleton et al. 2002). The only variable which correlated with annual wear was male gender, which has been observed in several other studies (Wright and Goodman 2001).

Osteolysis

The relationship between rapid PE wear and osteolytic processes is well documented (Livermore et al. 1990, Jacobs et al. 1994, Jasty et al. 1994, Shih et al. 1997, Dowd et al. 2000, Dumbleton et al. 2002). A strong correlation between these two phenomena was also found in our study.

Osteolytic processes, however, may be difficult to reveal in conventional radiographs. In our 66 revised cups, osteolysis was observed intraop-

eratively in 51 cases. However, these osteolytic processes could be seen in the preoperative radiographs of only two thirds of these cases (35), despite a serial evaluation of AP and lateral views and awareness of the phenomenon.

In severe cases, the osteolysis had also advanced 1–2 cm down the proximal femur and also into the greater trochanter. The trochanter may even be transformed into a cyst-like formation with very thin walls, which may fracture (Figure 8). In our experience, the femoral osteolytic processes should be curetted and filled with morselized allografts, leaving the stem in place, whereas the cups should be exchanged and the defects packed with morselized allografts.

Recently it has been shown that CT with modern software capable of reducing noise from metal implants reliably detects osteolytic processes (Puri et al. 2002). We have started to use CT when conventional radiographs are not conclusive.

Migration

There were no major differences with respect to migration and rotation of the cup compared to the results of an earlier analysis (Önsten et al. 1995) in which part of the present material is included. However, a number of uncemented Omnifit sockets suddenly tilted, despite the fact that they had been stable at the most recent RSA examination.

Technical analyses

The technical analysis of a small number of unused Charnley-Elite and Omnifit femoral heads revealed differences in roundness and surface roughness, but the results were not entirely conclusive. Analysis of a larger number of heads is required to ascertain whether true differences exist.

The technical analysis of excised heads demonstrated surface damage such as grooves often surrounded by banks. Ra values of up to 30 nm were observed. It is well known that such banks imply increased wear (Besong et al. 1997, Falez et al. 2000), but we are uncertain to what extent this was the cause in our series.

It has been proposed that HA particles damage the joint surfaces, with increased wear as a result (Morscher et al. 1998, Rokkum et al. 2002). In the two excised heads with the highest surface roughness (Ra value), we performed an EDAX analysis

and found some calcium but no phosphorus. If the damage was the result of third body wear due to HA particles, it seems likely that some remnants of phosphorus would have been found in the EDAX analysis.

Shelf life

Ageing of the polyethylene due to long “shelf life” may be a problem (Besong et al. 1997, Hardaker 2001), notably if the polyethylene, as in our sockets, has been irradiated and stored in air. However, only one of our sockets had a shelf life exceeding 3 years and this time is presumably too short to influence the ageing process and wear characteristics. This might explain why we found only a weak correlation between shelf life and wear, and that the multiple covariance analysis was not significant for wear and shelf life.

Reason for bad performance and other studies

Manley et al. (1998) and D’Antonio et al. (2001) suggest that the interface between bone and the smooth press fit socket cannot withstand the tensile stress as well as microstructured and threaded sockets. This theory cannot fully explain the excessive wear and osteolysis found in our material.

Lee et al. (2000) analyzed radiographs from 887 Omnifit, dual-geometry, microstructured cups and found seven liners with a broken locking mechanism. In an earlier report from the D’Antonio multicentre study (Manley et al. 1998, D’Antonio et al. 2001) it was pointed out that both the liners and the locking mechanisms used were the same for all shell types and thus could not be responsible for the failure of the Omnifit cups in our series.

There is reason to calculate wear and look for osteolytic lesions in the radiographic films of all patients who have received uncemented sockets of any design. It is also clear that an osteolytic process may sometimes be observed first in the proximal femur (Hsieh et al. 2002). With the findings in our study in mind, an annual wear of 0.2 mm or more should be a warning sign.

In a paper by Dowd et al. (2000) and in a literature review by Dumbleton et al. (2002), it was even concluded that an annual wear between 0.1 and 0.2 mm implied a risk of osteolysis. A CT scan should

be considered when the wear rate is abnormal but no osteolytic lesions can be demonstrated by conventional radiography.

We thank Jan-Åke Nilsson, Senior Statistician at the Department of Internal Medicine, Malmö University Hospital, and Patrik Markusson, Medical Technician at the Department of Orthopedics, Malmö University Hospital.

No competing interests declared.

- Besong A, Hailey J, Ingham E, Stone M, Wroblewski B, Fisher J. A study of the combined effects of shelf ageing following irradiation in air and counter face roughness on the wear of UHMWPE. *Biomed Mater Eng* 1997; 7: 59-65.
- Buma P, Gardeniers J M. Tissue reactions around a hydroxyapatite-coated hip prosthesis. *J Arthroplasty* 1995; 10: 389-95.
- Charnley J, Halley D K. Rate of wear in total hip replacement. *Clin Orthop* 1975; 12: 170-9.
- D'Antonio J A, Capello W N, Manley M T, Geesink R. Hydroxyapatite femoral stems for total hip arthroplasty. *Clin Orthop* 2001; 393: 101-11.
- DeChiffre L, Hansen H N, Bronstein A. Investigation on the surface topography in polishing using atomic force microscopy. *Ann ICRP* 1996; 45/1.
- DeLee J G, Charnley J. Radiological demarcation of cemented sockets in total hip replacement. *Clin Orthop* 1976; 121: 20-30.
- D'Lima D, Walker R, Colwell C. Omnifit-HA stem in total hip arthroplasty. *Clin Orthop* 1999; 363: 163-9.
- Dowd J, Sychterz C, Young A, Engh C. Characterization of long-term femoral-head-penetration rates. *J Bone Joint Surg (Am)* 2000; 82: 1102-7.
- Dumbleton J, Manley M, Edidin A. A literature review of the association between wear rate and osteolysis in total hip arthroplasty. *J Arthroplasty* 2002; 17: 649-61.
- Engh C A, Massin P, Suthers K E. Radiographic assessment of the biologic fixation of porous surfaced femoral components. *Clin Orthop* 1990; 257: 107-28.
- Falez F, La Cava F, Panegrossi G. Femoral prosthetic heads and their significance in polyethylene wear. *Int Orthop (SICOT)* 2000; 24: 126-9.
- Franzén H, Mjöberg B. Wear and loosening of the hip prosthesis. A roentgen stereophotogrammetric 3-year study of 14 cases. *Acta Orthop Scand* 1990; 61: 499-501.
- Gruen T A, McNeice G M, Amstutz H C. Modes of failure of cemented stem type femoral components: A radiographic analysis of loosening. *Clin Orthop* 1979; 141: 17-27.
- Hardaker C S. A comparison of the in vivo and in vitro wear rates of retrieved Charnley acetabular cups. M.Sc. thesis, University of Leeds, 2001.
- Harris W H. Traumatic arthritis of the hip after dislocation and acetabular fractures: Treatment by mold arthroplasty. An end-result study using a new method of result evaluation. *J Bone Joint Surg (Am)* 1969; 51: 737-55.
- Hsieh P, Shih C, Lee P, Chen C Yang W. Primary total hip arthroplasty without the use of bone cement: A 10-year follow-up of 157 hips. *Chang Gung Med J* 2002; 25: 298-305.
- Jacobs J, Shanbhag A, Glant T, Black J, Galante J. Wear debris in total joint replacements. *J Am Acad Orthop Surg* 1994; 2: 212-20.
- Jasty M, Bragdon C, Jiranek W, Chandler H, Maloney W, Harris W. Etiology of osteolysis around porous-coated cementless total hip arthroplasties. *Clin Orthop* 1994; 308: 111-26.
- Kärholm J, Borssén B, Löwenhielm G, Snorrason F. Does early micromotion of femoral stem prostheses matter? 4-7-year stereoradiographic follow-up of 84 cemented prostheses. *J Bone Joint Surg (Br)* 1994; 76: 912-7.
- Lee P, Shih C, Yen W, Yang W, Tu Y, Tai C. Complications of liner locking system in Microstructured Omnifit acetabular components. *Acta Orthop Scand* 2000; 71: 31-3.
- Livermore J, Ilstrup D, Morrey B. Effect of femoral head size on wear of the polyethylene acetabular component. *J Bone Joint Surg (Am)* 1990; 72: 518-28.
- Manley M T, Capello W N, D'Antonio J A, Edidin A A, Geesink R G. Fixation of acetabular cups without cement in total hip arthroplasty. A comparison of three different surfaces at a minimum duration of follow-up of five years. *J Bone Joint Surg (Am)* 1998; 80: 1175-85.
- Morscher E W, Hefti A, Aebi U. Severe osteolysis after third-body wear due to hydroxyapatite particles from acetabular cup coating. *J Bone Joint Surg (Br)* 1998; 80: 267-72.
- Nivbrant B, Kärholm J. Migration of hip prostheses fixed with a standard or cold curing bone cement. *Proceedings of the Orthopaedic Research Society, San Francisco* 1997: 309-52.
- Puri L, Wixson R L, Stern S H, Kohli J, Hendrix R W, Stulberg S D. Use of helical computed tomography for the assessment of acetabular osteolysis after total hip arthroplasty. *J Bone Joint Surg (Am)* 2002; 84: 609-14.
- Rokkum M, Reigstad A, Johansson C B. HA particles from well-fixed HA-coated stems. *Acta Orthop Scand* 2002; 73: 298-306.
- Selvik G. A roentgen stereophotogrammetric method for the study of the kinematics of the skeletal system. Thesis, University of Lund, 1974. Reprinted as Roentgen stereophotogrammetry. A method for the study of the kinematics of the skeletal system. *Acta Orthop Scand (Suppl 232)* 1989.
- Shih C H, Lee P C, Chen J H, Tai C L, Chen L F, Wu J S, Chang W H. Measurement of polyethylene wear in cementless total hip arthroplasty. *J Bone Joint Surg (Br)* 1997; 79: 361-5.
- Wright T, Goodman S Editors. *Implant wear in total joint replacement*. American Academy of Orthopaedic Surgeons 2001: 13-9.

Önsten I, Carlsson Å S, Sanzén L, Besjakov J. Migration and wear of a hydroxyapatite-coated hip prosthesis. A controlled roentgen stereophotogrammetric study. *J Bone Joint Surg (Br)* 1995; 77: 18-22.

Önsten I, Carlsson Å S, Besjakov J. Wear in uncemented porous and cemented polyethylene sockets. A randomised radiostereometric study. *J Bone Joint Surg (Br)* 1998; 80: 345-50.