

Low accuracy of stem implantation in THR using the CASPAR-system

Anteversion measurements in 10 hips

Farhad Mazoochian¹, Christoph Pellengahr², Armin Huber³, Jörn Kircher¹, Hans Jürgen Refior² and Volkmar Jansson¹

Departments of Orthopedics, ¹University of Rostock, ²University Hospital Großhadern, Ludwig-Maximilians-University of Munich, and ³Department of Radiology, University Hospital Großhadern, Ludwig-Maximilians-University of Munich, Germany
Correspondence FM: farhad.mazoochian@med.uni-rostock.de
Submitted 02-10-07. Accepted 03-08-26

ABSTRACT We studied 10 patients by means of pre- and postoperative CT who underwent computer-assisted total hip replacement using the CASPAR-system (OrthoMaquet GmbH, Rastatt, Germany).

The anteversion angles of the stem and translational deviations measured after surgery were compared to the preoperatively planned ones as a quality control. We found an average difference of 7.8° (SD 6.3°; 95% CI 3.3°–12.3°) in the angles and an average difference of 1.8 (SD 1.7; 95% CI 0.6–3.0) mm and 1.2 (SD 1.4; 95% CI 0.25–2.2), respectively, in the medial and lateral deviation.

In conclusion, we could not confirm the same accuracy of implant position as that claimed by the manufacturer.

Primary stability is important for long-term fixation of cementless implants in total hip replacement. Implant design, the surface structure, properties of the material used and positioning are factors that affect optimal osseointegration and, consequently, primary stability. Computer-assisted stem implantation was introduced to obtain an optimal and reproducible fit and placement of the stem component.

We compared the postoperative implant position with the preoperative planned one in 10 hips.

Patients and methods

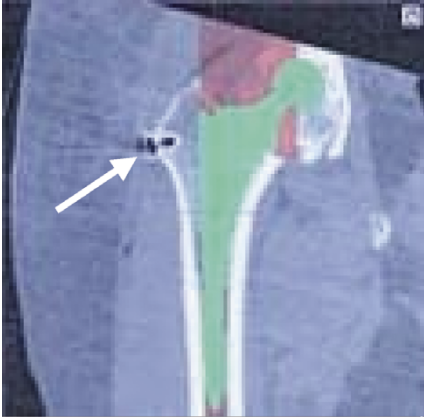
Patients

Between January 1999 and September 2000, 16 patients underwent computer-assisted total hip replacement with the CASPAR-system in the Department of Orthopedics at the University of Munich. 10 of the 16 patients were postoperatively evaluated with CT. 6 patients were unwilling to be exposed to radiation for the check-up with CT. The average age of the 10 in the study, 7 of whom were men, was 59 (53–69) years. 7 were left and 3 right hips and all patients had primary osteoarthritis. The patients in this study were given a Vision 2000 straight stem system (Depuy GmbH, Sulzbach, Germany).

The CASPAR-system

The CASPAR-system consists of two components, the planning station and the computer-guided robot. Using preoperative CT scans, we reconstructed the proximal femur and the femoral condyles. The scans provide information about the bone density. This system resembles the CAD systems used in industry to see 3-D objects. (Borner et al. 1997a, b).

It is necessary to implant pins (small titanium screws) in the femur to obtain distinct anatomical landmarks. Accuracy is best when the distance between the pins is as great as possible. We used the greater trochanter and the medial femoral con-



CASPAR workstation with anteroposterior view of the right hip joint by means of CT reconstruction. The arrow points to the marker pin in the greater trochanter. The endoprosthesis planning template is shown in green.

dyle. A subsequent CT scan with a slice width of 3 mm from the top of the femoral head to the lesser trochanter minor, a 6-mm width to the femoral condyle and a 3-mm width again in the condylar area gives the necessary digital data for planning. Thus the whole area for stem implantation is visualized and the data for calculation of femoral anteversion becomes available. The data are transferred to the planning station. The 3-D matrix is calculated and displayed on high-resolution monitors. Each femur is analyzed for the neck-shaft angle, anteversion angle, head diameter, center of rotation, neck length and diameter of the shaft.

The 3 windows on the screen facilitate planning in the frontal, axial and sagittal planes at the same time (Figure).

Using the planning program, a virtual operation is planned for the placement of a cementless femoral implant. The implant can be chosen from a pull-down menu and moved freehand on the screen until the best position is found.

Other users of the CASPAR-system have reported an accuracy better than 1 mm for the preoperatively-planned implant position, as regards axial translation and 0.1° for rotation (Birke et al. 2000). The burring itself is thought to have an accuracy of 0.04 mm (Okoniewski et al. 2000).

Methods

Translational deviations in the frontal plane (distance between the medial and lateral borders of the implant to the medial or lateral cortex, respectively) and differences in the preoperatively planned and postoperatively measured anteversion angles were studied.

Measurements were recorded at the level of the greater trochanter (lateralization) and the lesser trochanter (medialization) on CT print-outs. The data obtained from the preoperative planning were adjusted, using the preoperatively inserted pin at the greater trochanter as reference (Figure).

The anteversion angles were calculated by the radiologists during CT scanning and separately checked on print-out films by the authors. The principal author did all the measurements, except the calculation of anteversion angles, which was done by the CT machine based on landmarks defined by the radiologist. The data of the 10 patients were not normally distributed and therefore we used the Wilcoxon test for non-parametric related samples. Measurements of anteversion angles, medialization and lateralization on the CT printouts were repeated 3 times and checked for intraobserver error, using the Friedman test for non-parametric related samples and the intraclass correlation coefficient (ICC).

Results

The repeated evaluation of anteversion angles, lateralization and medialization on CT print outs showed no significant difference ($p = 0.6$; ICC 0.99, $p = 0.1$; ICC 0.99, and $p = 0.3$, ICC 0.99, respectively).

The average postoperative medial deviation, as compared to the preoperatively planned position was 1.8 (SD 1.7; 95% CI 0.6–3.0) mm.

The average postoperative lateral deviation, as compared to the preoperatively planned position was 1.2 (SD 1.4; 95% CI 0.25–2.2) mm.

The average difference in the preoperatively planned and postoperatively measured anteversion angles of the stem, based on computer tomography, was 7.8° (SD 6.3; 95% CI 3.3–12).

Table

Patient	Anteversión angle (degrees)					Lateralization (mm) ^c			Medialization (mm) ^d		
	Preop CT-scan	Postop CT-scan	Postop. Manual ^a	Difference CT-scan	Difference Manual ^b	Preop	Postop	Difference	Preop	Postop	Difference
1	14.0	4.9	4.0	9.1	10.0	7.8	7.0	0.8	3.1	3.5	0.4
2	14.0	23.0	23.0	9.0	9.0	10.2	10.0	0.2	2.0	3.2	1.2
3	13.0	13.9	14.0	0.9	1.0	12.7	12.9	0.2	2.1	2.6	0.5
4	3.0	12.4	11.0	9.4	8.0	8.9	10.1	1.2	3.6	4.5	0.9
5	13.0	22.8	21.0	9.8	8.0	18.6	18.6	0.0	5.6	4.7	0.9
6	3.0	12.3	13.0	9.3	10.0	15.5	11.2	4.3	1.9	6.7	4.9
7	18.0	-4.0	-3.0	22.0	21.0	15.5	16.3	0.8	3.1	7.9	4.8
8	14.0	15.7	17.0	1.7	3.0	14.0	15.3	1.3	2.8	4.1	1.3
9	10.0	17.0	18.0	7.0	8.0	18.7	21.8	3.1	2.2	3.1	0.9
10	22.0	22.2	25.0	0.2	3.0	6.2	5.6	0.6	0.1	1.9	1.8

^a Anteversión angles on postoperative CT print-outs recorded manually.

^b Difference between preoperative anteverción angles on CT scans and postoperative anteverción angles on CT print-outs recorded manually in absolute values.

^c Lateralisation of the femoral stem recorded at the CASPAR workstation based on preoperative and postoperative CT scans and difference in absolute values between preoperative and postoperative lateralization.

^d Medialization of the femoral stem recorded at the CASPAR workstation based on preoperative and postoperative CT scans and difference in absolute values between preoperative and postoperative medialization.

Discussion

Several authors emphasize the importance of a physiological anteverción angle to restore physiological joint mechanics, which is frequently neglected in conventional hip replacement surgery (Daly and Morrey 1992, Grossmann et al. 1994, Börner et al. 1997a, b).

The manufacturer of the CASPAR-system (OrthoMaquet, Rastatt, Germany) claims an accuracy of 1 mm concerning the reproducibility of the preoperatively planned implant position for computer-assisted stem implantation in total hip replacement. The accuracy of preoperative planning based on CT-data at the workstation, should be 0.1° for rotation and 0.1 mm for axial translation (Börner et al. 1997a, Jerosch et al. 1998). Okoniewski et al. (2000) reported accurate burring of the robot up to 0.04 mm thus providing a bone bed, which allows an exact fit of the implant.

In experimental studies, several authors have found that small changes in the postoperative anteverción angles significantly affect joint mechanics. The hip joint rotators and horizontal fibers of the gluteus muscles with a short overall muscle length undergo a substantial change in length and change in the position of their insertions in the greater trochanter, which leads to muscular imbalance

(Daly and Morrey 1992, Jerosch et al. 1997).

Daly and Morrey (1992) emphasized the importance of correct anteverción of the stem to reduce the risk of anterior dislocation.

We found an average difference in the preoperatively planned and postoperatively measured anteverción angles of 7.8° and an average difference in the medial and lateral deviations of 1.8 mm and 1.2 mm, respectively (Table). We therefore cannot confirm the data provided by the manufacturer as regards the accuracy of the CASPAR-system. Nor can we confirm the data by Jerosch et al. (1998) who found deviations in the anteverción angle of 0.4 mm in the computer-assisted group in a randomized double-blind study including 14 human cadaveric femurs.

An explanation of the difference in the detected accuracy for in vivo and in situ experiments may be undetected motion of the patient during the operation. Such motions are detected to some extent in robot-assisted operations by the system. If these motions exceed a certain amount, the system stops, and recalibration becomes necessary (Pellengahr et al. 2002). We cannot answer whether the detected or undetected motions of the patients are the main reason for those differences.

We conclude that experimental results cannot be directly transferred to the clinical situation con-

cerning the accuracy of computer-assisted surgery in total hip replacement.

No competing interests declared.

- Birke A, Reichel H, Hein W, Schietsch U, Hube R, Bernstein A, Kruger T. [ROBODOC--a path into the future of hip endoprosthetics or an investment error?]. *Z Orthop Ihre Grenzgeb* 2000; 138 (5): 395-401.
- Börner M, Bauer A, Lahmer A. Computer-assisted robotics in hip endoprosthesis implantation. *Unfallchirurg* 1997a; 100 (8): 640-645.
- Börner M, Bauer A, Lahmer A. [Computer-guided robot-assisted hip endoprosthesis]. *Orthopäde* 1997b; 26 (3): 251-257.
- Daly P J, Morrey B F. Operative correction of an unstable total hip arthroplasty. *J Bone Joint Surg (Am)* 1992; 74 (9): 1334-1343.
- Grossmann P, Braun M, Becker W. [Dislocation following total hip endoprosthesis. Association with surgical approach and other factors]. *Z Orthop Ihre Grenzgeb* 1994; 132 (6): 521-526.
- Jerosch J, Steinbeck J, Stechmann J, Guth V. Influence of a high hip center on abductor muscle function. *Arch Orthop Trauma Surg* 1997; 116 (6-7): 385-389.
- Jerosch J, von Hasselbach C, Filler T, Peuker E, Rahgozar M, Lahmer A. [Increasing the quality of preoperative planning and intraoperative application of computer-assisted systems and surgical robots--an experimental study]. *Chirurg* 1998; 69 (9): 973-976.
- Okoniewski M, Birke A, Schietsch U, Thoma M, Hein W. Early results of a prospective study in patients with computer-assisted femur shaft preparation in total hip endoprosthesis implantation (Robodoc system)-indications, outcome, complications. *Z Orthop Ihre Grenzgeb* 2000; 138 (6): 510-514.
- Pellengahr C, Huber A, Jansson V, Refior HJ. Irregular rotation and shift of computer-assisted femoral stem implantation in THA- an experimental study. *Orthopaedic Trauma Surgery* 2002.