

Stable fixation of the ulnar component in the Kudo elbow prosthesis

A radiostereometric (RSA) study of 13 prostheses with 2-year follow-up

Hans Rahme, Per Mattsson and Sune Larsson

Department of Orthopedics, University Hospital, SE-751 85 Uppsala, Sweden
Correspondence HR: Hans.Rahme@telia.com
Submitted 04-01-18. Accepted 04-06-27

Background Concern has been expressed about the large number of radiolucent lines around the ulnar component of the Kudo elbow prosthesis in medium-term follow-up.

Patients and methods We studied the metal-backed cemented ulnar component in 13 Kudo elbow prostheses (type 5) using radiostereometric analysis (RSA). All patients had rheumatoid arthritis. There were 2 men and 9 women with a mean age of 55 years. 2 were operated bilaterally. The metal-backed ulnar component was marked with three 0.8 mm tantalum spheres and the proximal ulna with 5 spheres of 0.8 or 1.0 mm diameter. The initial RSA examination was performed during the first week after the operation. Further examinations were done at 4, 12 and 24 months. Conventional radiographs were taken during the first week postoperatively, and at 12 and 24 months.

Results Translations (medial/lateral, antero/posterior and proximal/distal) were less than 0.5 mm in all but 1 patient who had a maximal translation of 3.4 mm distally. The mean rotations around all three axes were less than 0.4 degrees. The patient who had a translation of 3.4 mm also had varus angulation exceeding 4 degrees. This patient also had progressive circumferential radiolucent lines on conventional radiographs. The Mayo elbow score increased from 40 (25–65) before surgery to 92 (45–100) at 2 years.

Interpretation The fixation of the metal-backed ulnar component of the Kudo elbow prosthesis at 2 years is good.

The Kudo prosthesis is the commonest elbow implant used in Sweden (Rahme et al. 2001). In an earlier study, concern was expressed about the large number of radiolucent lines around the ulnar components in a medium-term follow-up (Rahme 2002). We therefore initiated this radiostereometric (RSA) study of the metal-backed ulnar component. The main purpose was to use RSA to study the fixation of a cemented metal-backed ulnar component and to correlate the findings of migration to the presence of radiolucencies in conventional radiographs.

Patients and methods

Between 1997 and 2001, 12 patients received a Kudo total elbow prosthesis in our department. The diagnosis was rheumatoid arthritis in all patients. The elbows were in stages 3–5, according to Larsen et al. (1977). All had severe disabling pain and radiographic signs of arthritis. 2 patients had both elbows operated. 1 patient (elbow) had to be excluded due to dislocation, fracture and subsequent loosening of the ulnar component, leaving 13 elbows in 11 patients (mean age 55 (34–67) years, 9 women), all of which were followed according to the study protocol (Table).

The same surgeon (HR) operated on all patients with the Kudo elbow prosthesis type 5 (Kudo et al. 1999). The humeral component was partially cemented below the condyles in 8 elbows, and uncemented in 5. A metal-backed ulnar component

Characteristics of the patients

A	B	C	D	E	F	G	H	I	J	K	L	M	N	O	P	Q
1	F	67	24	IV	2	–	25	90	40–135	30–150	2	2	1			
2	F	53	24	V	2	1	55	85	35–95	20–145	2	2	1		1, 2	M
3	F	53	28	IV	2	–	50	75	45–140	55–145	1	1	1			
4	F	50	22	IV	2	–	65	100	30–125	30–140	1	2	1			
5	M	63	35	V	2	–	15	65	30–135	40–150	2	2	1	CRR		
6	F	62	25	III	1	–	45	100	0–140	30–150	2	2	1			
7	M	65	29	IV	1	–	25	85	20–140	25–145	1	0	1	CRR	1	
8	M	59	30	III	2	–	65	95	35–125	45–140	2	2	1		1	
9	F	50	26	III	2	–	25	45	45–95	55–105	0	0	3			
10	F	64	24	IV	2	–	35	85	70–130	55–145	0	2	1			
11	F	61	24	IV	1	–	35	100	30–140	35–140	1	1	1			
12	F	34	24	III	1	–	45	80	30–130	30–150	1	1	1			
13	F	36	25	III	2	–	35	95	30–130	20–140	1	2	1			

<p>A Elbow</p> <p>B Sex</p> <p>C Age</p> <p>D Months of clinical follow-up</p> <p>E Stage according to Larsen's classification</p> <p>F Cementation technique</p> <p>1 Ulna cemented, humerus uncemented</p> <p>2 Ulna cemented, humerus cemented under condyles</p> <p>G Perioperative complications</p> <p>1 Ulnar component did not adhere to the cement</p> <p>H Preoperative Mayo score</p> <p>I Mayo score at 2 years</p> <p>J Range of motion preoperative</p> <p>K Range of motion at 2 years</p>	<p>L Pro- and supination preoperatively</p> <p>0 Below 60° together</p> <p>1 Both pro- and supination between 30 and 60°</p> <p>2 Both pro- and supination more than 60°</p> <p>M Pro- and supination at 2 years</p> <p>N Patient satisfaction</p> <p>1 Satisfied</p> <p>2 Uncertain</p> <p>3 Dissatisfied</p> <p>O Previous surgery</p> <p>CRR Caput radii resection</p> <p>P Radiolucent lines ulnar component at 2 years</p> <p>1 Proximal</p> <p>2 Stem</p> <p>Q RSA result</p> <p>M Migration</p>
---	--

was cemented with Palacos R with gentamicin cement (Schering-Plough, Malmö, Sweden) in all cases.

During surgery, 5 tantalum markers of 0.8 or 1.0 mm diameter were inserted in the olecranon. The ulnar components were premarked with 3 tantalum markers. The markers were spaced as widely as possible to optimize the subsequent radiostereometric (RSA) evaluation (Figure 1a).

The RSA examinations were done with the patient sitting. The elbow was placed in a calibrating box. The two X-ray tubes that allowed simultaneous exposure were placed at about 90° to each other in front of the patient, with horizontal beam direction. Exact positioning of the tubes was not critical, since the three-dimensional coordinates of each X-ray tube were calculated at each examination. The film-focus distance was about 100 cm. The first RSA examination (reference examination) was done 5–7 days after surgery. The following examinations were done at 4 months, and 1 and 2 years postoperatively.

The radiostereometric technique allows a three-dimensional high resolution assessment of motion between segments defined by the tantalum markers. The technique has been described extensively and used preferentially for assessment of micromotion of hip and knee prostheses (Kärrholm 1989, Selvik 1989, Kärrholm et al. 1994).

The radiostereometric measurements were done with the UmRSA system (RSA Biomedical Innovations, Umeå, Sweden). The movements of the ulnar component in relation to the ulna were recorded using the markers in the ulna as the fixed reference segment. The linear movements were expressed as translations along the transverse (x-axis, medial-lateral translation), longitudinal (y-axis, proximal-distal translation), and sagittal (z-axis, anterior-posterior translation) axes of the elbow joint. The angular movements were expressed as rotations about the transverse (x-axis, forward-backward), longitudinal (y-axis, outward-inward), and sagittal (z-axis, varus-valgus) axes of the elbow joint, respectively (Figure 1).

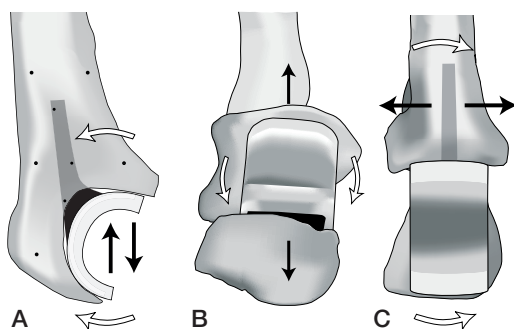


Figure 1. Drawing of a metal-backed ulnar component and movements assessed using radiostereometric analysis (RSA).

- A. Black arrows: proximal/distal translation; white arrows: forward/backward rotation; black spots: tantalum markers.
 B. Black arrows: anterior/posterior translation; white arrows: outward/inward rotation.
 C. Black arrows: medial/lateral translation; white arrows: varus/valgus rotation.

At 4 months, a double examination was done in all patients to evaluate the precision of the method (Kärrholm 1989). Thus, the critical levels for significant ($p < 0.05$) translations were > 0.07 mm (transverse axis), > 0.08 mm (longitudinal axis), and > 0.07 mm (sagittal axis), respectively. The corresponding critical levels for significant rotations were $> 0.41^\circ$ (transverse axis), $> 0.60^\circ$ (longitudinal axis), and $> 0.50^\circ$ (sagittal axis).

Conventional anterior-posterior and lateral radiographs were taken postoperatively and at 1

and 2 years. The first postoperative radiographs were compared (with respect to radiolucencies) with those obtained at the 1- and 2-year follow-up by a radiologist without knowing the RSA results. The cement-bone interface around the ulnar component was divided into 2 zones: ulnar stem and proximal part of ulnar component. A progressive radiolucent zone of 2 mm or more around the entire component, or a detectable shift in position, was regarded as a definitive loosening (Gill and Morrey 1998).

The clinical follow-up included range of motion, patient satisfaction and the Mayo Elbow performance score (Gill and Morrey 1998).

Results

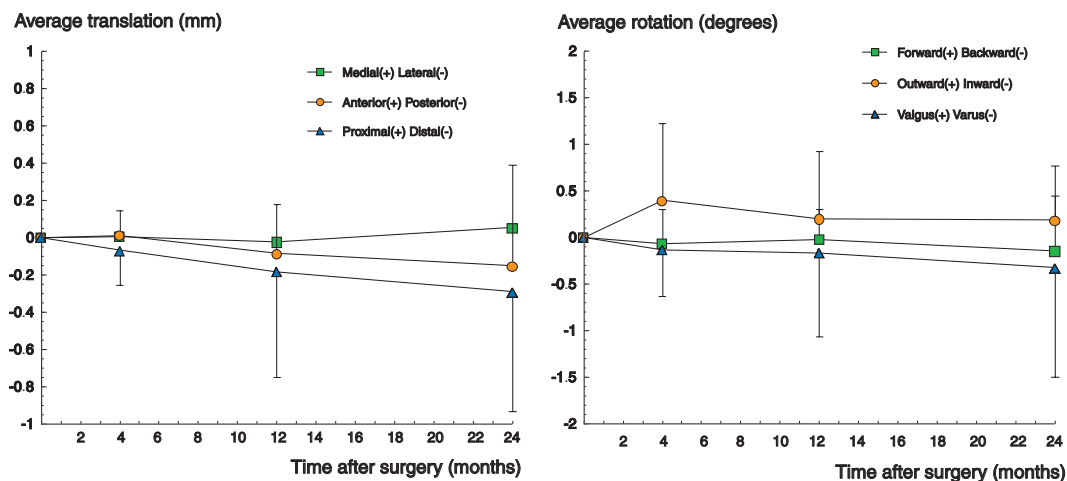
Clinical results

All but 1 patient (elbow 9) were satisfied with the result. The preoperative Mayo Elbow performance score averaged 40 (25–65) and was 92 (45–100) at the 2-year follow-up (Table).

Radiographic results

1 elbow (elbow 2) had progressive radiolucent lines around the entire ulnar component. 2 elbows had radiolucent lines around the proximal part of the ulnar component (elbows 7 and 8) which developed between the 1-year and the 2-year follow-up.

Figure 2. Translation and rotation of the ulnar component with respect to the ulna during 2-year follow-up.



Translation along the 3 coordinate axes (n=13; mean ± SD).

Rotations around the 3 coordinate axes (n=13; mean ± SD).

1 humeral stem was radiographically loose, with an obvious shift in position at the 2-year follow-up (elbow 2).

RSA results

The patterns of translations and rotations of the ulnar component in relation to the ulna are shown in Figure 2. Translations at 2 years after surgery in the medial/lateral, anterior/posterior and proximal/distal directions were less than 0.5 mm in all but 1 elbow (no. 2), which had a translation of 3.4 mm distally. Varus-valgus angulation was less than 0.5° in all elbows except for the elbow that had a translation of 3.4 mm, where a varus angulation of more than 4° had occurred at the 2-year follow-up. Average angulation around the longitudinal axes was less than 0.5°, with a tendency to outward angulation in most elbows.

Discussion

Radiostereometric analysis (RSA) has been widely used to evaluate hip and knee implants and their fixation (Kärrholm 1989, Kärrholm et al. 1994, Ryd et al. 1995). We have found 1 report regarding fixation of elbow prostheses studied with RSA (Valstar et al. 2002). These authors found that the ulnar component of the Souter-Strathclyde elbow prosthesis was well fixated in the ulna, while the humeral component was regarded as being at risk from aseptic loosening in 8 of 18 replacements. The conclusion was that development of new types of the Souter-Strathclyde elbow prosthesis should concentrate on improving fixation of the humeral component. However, in a 5-year follow-up of the Kudo prosthesis, circumferential radiolucencies were seen in 7/27 of the ulnar components and around the proximal part of the ulnar component in 18/26 (Rahme 2002). Concern was expressed about the ulnar component being the potentially weakest part of the Kudo prosthesis. Based on this concern, we decided to study the ulnar component with RSA in order to measure the fixation of the ulna component more accurately.

The mean translations along the 3 coordinate axes were less than 0.4 mm and the mean rotations were less than 0.4°. All but 1 ulnar component stabilized between the 1- and 2-year follow-up. The

ulnar component that continued to translate and rotate (elbow 2) was regarded as loose, and also had progressive circumferential radiolucent lines on conventional radiographs. The explanation for this may be that the component had to be cemented twice during the index operation since it did not adhere to the cement at the first attempt. All other ulnar components were regarded as stable, indicating that the initial fixation is good after 2 years. It was not possible to assess the significance of radiolucencies further in relation to RSA, due to the small number of patients with radiolucent lines at 2 years in this series. Perhaps the rheumatoid process is responsible for radiolucencies that develop with time, despite the fact that the initial fixation of the ulnar component is good. We will continue to follow these patients with RSA and conventional radiographs to find out whether an initially stable component will become unstable some time in the future.

We thank Lars Wikblad for interpreting the conventional radiographs.

No competing interests declared.

Gill D R, Morrey B F. The Coonrad-Morrey total elbow arthroplasty in patients who have rheumatoid arthritis. A ten to fifteen-year follow-up study. *J Bone Joint Surg (Am)* 1998; 80: 1327-35.

Kudo H, Iwano K, Nishino J. Total elbow arthroplasty with a nonconstrained humeral component inserted without cement in patients who have rheumatoid arthritis. *J Bone Joint Surg (Am)* 1999; 81: 1268-80.

Kärrholm J. Roentgen stereophotogrammetry. Review of orthopedic applications. *Acta Orthop Scand* 1989; 60: 491-503.

Kärrholm J, Borssén B, Löwenhielm G, Snorrason F Does early micromotion of femoral stem prostheses matter? 4-7-year stereoradiographic follow-up of 84 cemented hip prostheses. *J Bone Joint Surg (Br)* 1994; 76: 912-7.

Larsen A, Dale K, Eek M. Radiographic evaluation of rheumatoid arthritis and related conditions by standard reference films. *Acta Radiol* 1977; 18: 481-91.

Rahme H. The Kudo elbow prosthesis in rheumatoid arthritis. A consecutive series of 26 elbow replacements in 24 patients followed prospectively for a mean of 5 years. *Acta Orthop Scand* 2002; 73: 251-6.

Rahme H, Jacobsen M B, Salomonsson B. The Swedish elbow register and the Swedish shoulder arthroplasty register. Two new Swedish arthroplasty registers. *Acta Orthop Scand* 2001; 72: 107-12.

Ryd L, Albrektsson B E J, Carlsson L, et al. Roentgen stereophotogrammetric analysis as a predictor of mechanical loosening of knee prostheses. *J Bone Joint Surg (Br)* 1995; 77: 377-83

Selvik G. Roentgen-stereophotogrammetric method for the study of the kinematics of the skeletal system. *Acta Orthop Scand (Suppl 232)* 1989: 1-51

Valstar E R, Garling E H, Rozing P M. Micromotion of the Souter-Strachclyde total elbow prosthesis in patients with rheumatoid arthritis. 21 elbows followed for 2 years. *Acta Orthop Scand* 2002; 73 (3): 264-72.