

# Uncemented Harris-Galante total hip arthroplasty in patients with osteonecrosis of the femoral head

## A 10–16-year follow-up study

Yong-Goo Kim, Shin-Yoon Kim, Byung-Chul Park, Poong-Taek Kim, Joo-Chul Ihn and Ik-Dong Kim

Department of Orthopaedic Surgery, School of Medicine, Kyungpook National University, Sam-Duck 2 Ga 50, Jung-gu, Daegu, 700-721 Korea

Syukim@knu.ac.kr

Submitted 04-04-22. Accepted 04-09-09

**Background** There have only been a few reports regarding the long-term results of uncemented THAs in patients with osteonecrosis.

**Patients and methods** We evaluated the long-term results of 65 consecutive uncemented total hip arthroplasties (Harris-Galante type I prostheses) in 54 men (59 hips) and 5 women (6 hips) with osteonecrosis of the femoral head. The mean age was 53 (33–64) years. The mean duration of follow-up was 12.5 (10–16) years.

**Results** 9 femoral stems and 3 acetabular metal shells were revised. 2 polyethylene liners were changed due to excessive wear. A girdlestone procedure was done in 2 patients (2 hips) due to delayed deep infection. The mean polyethylene wear was 0.14 mm per year. 3 non-revised hips had pelvic osteolysis and 18 had femoral osteolysis. The 15-year survival rates, using failure defined as the removal of any component for any reason, were 85 (95% CI; 79–91)% for the acetabular and 80 (74–86)% for the femoral component and 70 (63–77)% for any of the components.

**Interpretation** The first generation of the HGP design was frequently associated with pain, unstable fixation, and osteolysis. Excessive wear was frequent. The cup showed better durability than the stem.

arthroplasty. Continued use of steroids, ongoing systemic disease, increased body weight, high activity level associated with young age, high prevalence of bilaterality, poor bone quality, and extensive necrosis of bone have been proposed to be contributing factors (Isono et al. 1987, Clarke et al. 1989, Fye et al. 1998, Xenakis et al. 2001). Although the aseptic loosening rates for the uncemented designs have been reported to decrease after the midterm follow-up, unexpected problems such as thigh pain, stress shielding, and osteolysis have been reported (Lins et al. 1993, Piston et al. 1994, Kim et al. 1995, D'Antonio et al. 1997, Stulberg et al. 1997, Fye et al. 1998, Hartley et al. 2000). To our knowledge, there has been no long-term report regarding uncemented THAs with the use of the porous coated Harris-Galante Type I prosthesis (HGP – I, Zimmer, Warsaw, IN, USA) in patients with osteonecrosis of the femoral head. We evaluated results after a minimum of 10 years of follow-up of the uncemented HGP-1 in patients with osteonecrosis of the femoral head.

### Patients and methods

Between 1986 and 1991, 72 patients (81 hips) with a diagnosis of Ficat and Arlet stage III or IV osteonecrosis of the femoral head (Ficat and Arlet 1980) were operated consecutively with uncemented HGP-1 prostheses. 10 patients died during the study period (13 hips) due to causes

Total hip arthroplasty (THA) is considered to be the best treatment for individuals with disabling hip pain due to advanced osteonecrosis with collapse of the femoral head. Patients with this disease have, however, a higher rate of failure after

Table 1. Age distribution of patients

Age	No. of patients (hips)	
30–39	6	(7)
40–49	21	(23)
50–59	21	(22)
60–69	11	(13)
Total	59	(65)

unrelated to the THA, and 3 patients (3 hips) were lost to follow-up, leaving 59 patients (65 hips) to be studied, 6 with bilateral prostheses. The average age at the time of the index operation was 53 (33–64) years (Table 1). There were 54 men (59 hips) and 5 women (6 hips). The average weight was 68 (54–82) kg and the average height was 170 (155–181) cm. The average time to follow-up was 12.5 (10–16) years. 31 patients (33 hips) were involved in sports activities at recreational level, 23 patients (25 hips) were involved in other strenuous activities, and the remaining 5 patients were sedentary or semi-sedentary.

The presumed cause of osteonecrosis was alcohol abuse in 35 hips, idiopathic in 19 hips, steroid use in 7 hips and the result of trauma in 4 hips. Arthroplasty was the first surgical procedure in 58 hips. 4 hips had been operated previously with internal fixation procedures and 3 hips had been operated with core decompression.

The acetabular component is hemispherical with a titanium metal fiber coating and multiple screw

holes. It was implanted using line-to-line reaming and fixed with an average of 3 (2–5) screws. The femoral component is straight and has 3 proximal non-circumferential titanium fiber metal pads excluding the lateral side. A 28-mm modular cobalt-chrome head and a posterolateral approach were used in all patients. Postoperative rehabilitation included non-weight bearing ambulation for 6 weeks, followed by gradually increased weight bearing for an additional 6 weeks.

The patients were evaluated preoperatively, at 6 weeks postoperatively, and at 6 months, 1 year, and yearly thereafter using the Harris hip scoring system (HHS) (Harris 1969). The results were classified as excellent (90–100), good (80–89), fair (70–79), and poor (<70). The radiographic evaluations from the preoperative and follow-up periods included assessment of the fixation of the femoral and acetabular components, polyethylene wear, osteolysis, and heterotopic ossification. The stability of the cup was classified as optimal, suboptimal, or definitely unstable (Engh et al. 1990). The abduction angle of the cup was measured from the horizontal line joining the teardrop across the maximum diameter of the cup edge on an anteroposterior (AP) radiograph of the pelvis (Figure 1A). The anteversion was measured by an angle between the vertical line and a line across the maximum diameter of the cup edge on a cross-leg lateral view radiograph (Figure 1B). Migration of the cup and angular changes were measured on AP radiographs of the pelvis (Figure 1A) using the technique described by Massin et al.

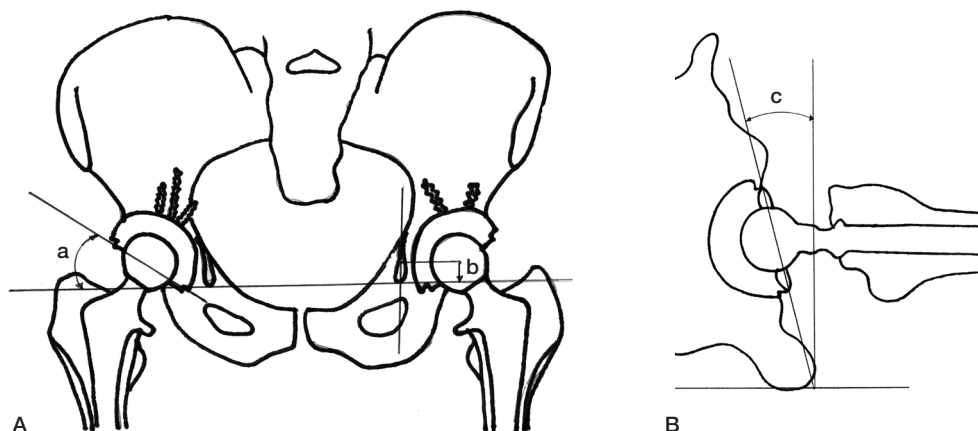


Figure 1. Illustration of measurements made on the anteroposterior (A) and the lateral radiograph (B) of the pelvis. Inclination (a), migration (b), and anteversion (c) are shown.

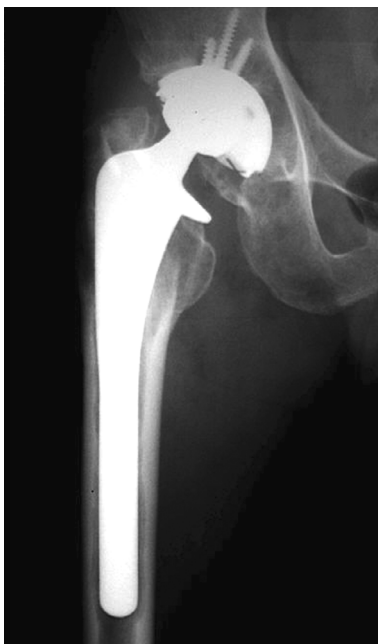
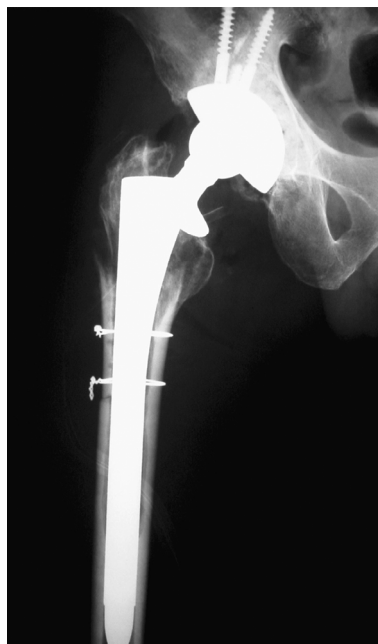
Figure 2. A) The right hip of a 61-year-old man, 12 years after implantation, with diffuse expansile pelvic osteolysis with eccentric polyethylene wear, and diffuse diaphyseal osteolysis of the femur.



B) Revision surgery was done with uncemented acetabular cup and screws using allograft at the pelvic side, and with an uncemented porous coated long stem at the femoral side.

(1989) The acetabular component was considered to be loose if there was a change in the inclination greater than  $4^\circ$ , 5 or more mm of change in the position, and a circumferential radiolucent line wider than 1 mm on both the AP and the lateral radiograph. The stability of the stem was classified as bone ingrown, stable fibrous ingrown, or definite instability (Engh et al. 1990). Osteolysis was defined as cystic or scalloped lesions exceeding 2 mm in diameter and not present on the immediate postoperative radiograph. Osteolytic lesions were classified according to their pattern (Zicat et al. 1995) and location (DeLee and Charnley 1976).

The femur was divided into a proximal region including the porous pads, and distal diaphyseal region. Linear wear was measured according to Livermore et al. (1990) by independent observers (YGK, BCP). A digital caliper (Mode No CD-15B, Mitutoyo Co., Tokyo, Japan) with an accuracy of 0.01 mm was used.

### Statistics

We used Student two-tailed t tests, analysis of variance, and linear regression (Senghas 1992). Significance was set at  $p < 0.05$ . Survival was analyzed

(Kaplan-Meier) with failure – defined as reoperation for any reason – as the end point. SPSS version 10 was used (SPSS, Chicago, IL, USA).

## Results

### Reoperations, complications and survival

Neither of the patients who died, nor the patients lost before the minimum 10 year follow-up, had required an implant revision. In 10 patients who died before the 10 years of follow up, the mean time between index operation and death was 7.2 (3.5–9.2) years. There were 2 deep infections with *Staphylococcus aureus* in 2 hips (2 patients) after 7 and 11 years. These were treated by removal of both components. At operation, the acetabular shells were found to be well-fixed and the femoral stems were loose.

There were 9 femoral revisions in 9 patients (8 for aseptic loosening and 1 for periprosthetic fracture). The fracture occurred after about 6 years due to progressive osteolysis. It was treated by insertion of a longer uncemented stem (Figure 2). The 8 hips that underwent femoral revision for aseptic

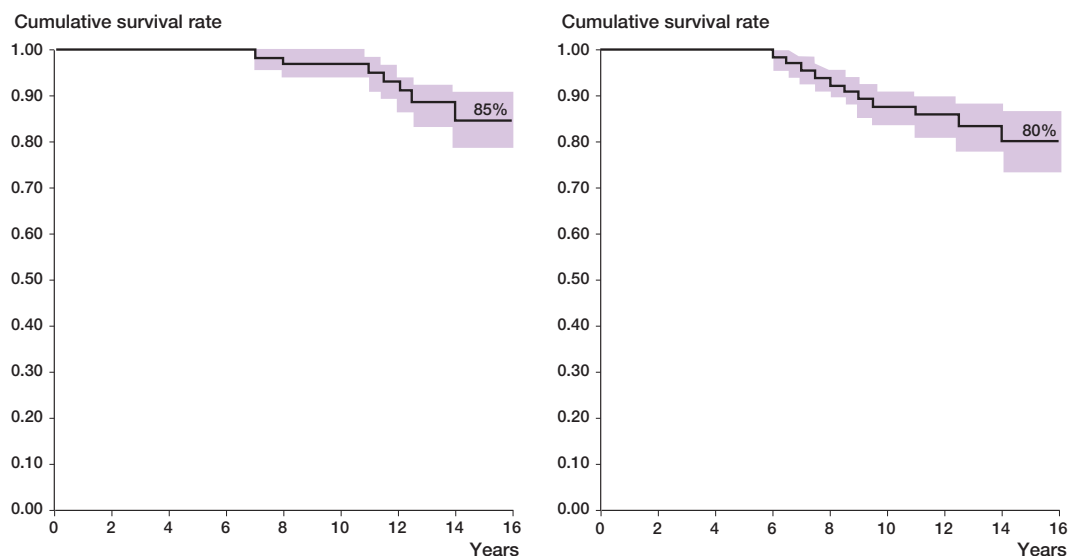


Figure 3. Kaplan-Meier survival curve for the acetabular component (left) and the femoral component (right), with failure defined as reoperation for any reason at the time of follow-up. 95%CI indicated.

loosening were found to have a well-fixed acetabular component.

There were 3 acetabular shell revisions. 2 were done after 12 and 14 years because of progressive retroacetabular osteolysis with metallosis caused by excessive wear, resulting in contact between the metallic head and the shell. 1 socket was revised due to superior migration and change of position after 8 years. At the index operation, the patient had received a bulk allograft because of a comminuted posterior wall fracture of the acetabulum. The locking mechanism (spikes) was broken in 3 revised cups.

2 polyethylene liners were exchanged after 11 and 12 years on average because of excessive wear. The locking mechanism was intact in both cups. The metallic shells were found to be well fixed at the operation.

Heterotopic ossification was observed in 11 hips (grade I in 6 hips and II in 5 hips; Brooker et al. 1973). Dislocation occurred in 2 hips (2 patients). They were successfully treated with a hip spica cast for 6 weeks without recurrence. 2 patients had venographic evidence of deep venous thrombosis, which was treated with unfractionated heparin and application of bilateral stockings.

Kaplan-Meier survivorship analysis revealed a 10-year survival rate of 97 (95% CI; 95–99)% for the acetabular components and 88 (83–92)% for

the femoral components. The survival rate at 15 years was 85 (79–91)% for the acetabular components and 80 (74–86)% for the femoral components (Figure 3). Including both the acetabular and femoral components, the overall survival rate was 89 (85–93)% at 10 years and 70 (64–78)% at 15 years.

#### *Clinical results in patients who did not have a reoperation*

15 patients who had a reoperation (16 hips) were excluded from the following detailed clinical analysis, leaving 49 hips in 44 patients available for review at an average of 12 years after the index operation. The average preoperative HHS of 42 (15–68) points improved to 91 (73–100) points at the final follow-up (Figure 4). At the final follow-up, 28 hips had an excellent rating, 16 hips had a good rating, and 5 hips had a fair rating. 6 patients (7 hips) had transitory pain in the thigh. 2 patients had thigh pain for more than 2 years after the operation, 3 patients had thigh pain for less than 1 year, and 1 patient required the aid of a stick (Table 2).

#### *Radiographic results in patients who did not have a reoperation*

3 cups showed radiolucent lines of more than 1 mm: 2 cups showed radiolucent lines in region I and one cup in region III, none of which was progressive.

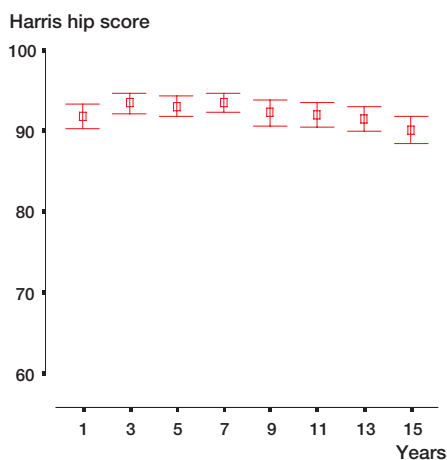


Figure 4. Error-bar graph showing the change in Harris hip score at every follow-up.

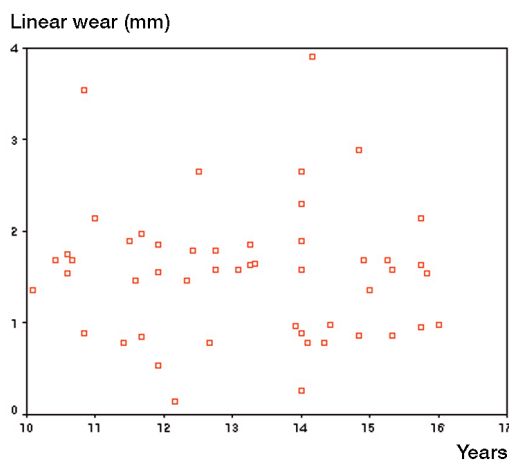


Figure 5. Scatter diagram showing wear data from unrevised hips.

Table 2. Clinical results

	Preoperative No. of hips	Postoperative No. of hips
<i>Pain</i>		
None	0	25
Slight (no medication)	0	17
Mild (over-the-counter medication)	0	5
Moderate (occasional narcotic medication)	31	2
Severe	18	0
<i>Limp</i>		
None	0	40
Slight	26	9
Moderate	15	0
Severe	8	0
<i>Support</i>		
None	28	45
Cane	14	4
Two supports	7	0
Unable to walk	0	0

Table 3. Results of radiography

	Mean (SD)	Range
Cup size (mm)	52.5 (3.3)	48–62
Thickness of liner (mm)	8.0 (1.6)	6.2–12.2
Abduction angle (°)	40.2 (5.2)	28–62
Anteversion of cup (°)	17.1 (8.5)	0–45
Amount of linear wear (mm)	1.36 (0.73)	0.1–3.9
Annual linear wear (mm)	0.13 (0.08)	0.01–0.31

Table 4. Relationship between polyethylene wear and variables

Variables	P-value
Cause of osteonecrosis	0.31 <sup>a</sup>
Weight	0.23 <sup>b</sup>
Age	0.07 <sup>b</sup>
Harris hip score	0.25 <sup>b</sup>
Amount of anteversion	0.33 <sup>b</sup>
Abduction angle	0.18 <sup>b</sup>
Thickness of polyethylene	0.09 <sup>b</sup>

<sup>a</sup> Analysis of variance  
<sup>b</sup> Linear regression test

47 acetabular components showed optimal stability and 2 showed suboptimal stability at the final follow-up evaluation. 40 femoral components were bone-ingrown, 9 were stable fibrous-ingrown, and no stems were loose or subsided more than 5 mm. 45 of the stems were in a neutral position, 2 were in varus, and 2 were in valgus. Partial pedestal (periosteal?) formation was found in 2 hips. 8 hips had distal cortical hypertrophy. Cup size, thickness of liner, abduction angle, anteversion of cup, and polyethylene wear are presented in Table 3. Polyethylene wear was less than 1 mm in 15 hips, between 1–2 mm in 28 hips, and greater than 2 mm in 6 hips (Figure 5). There was a significant association between wear and age (Table 4).

All unrevised hips with an osteolytic lesion had polyethylene wear greater than 1 mm. Focal osteolysis was found around the acetabulum in 3

hips: 2 were around the screw holes (zone II) and 1 was at the lateral acetabular margin (zone I). 18 hips had osteolytic lesions in the femur: 6 hips had proximal lesions, 8 hips had distal lesions, and 4 hips had both proximal and distal lesions. These osteolytic lesions had not affected cup and stem stability at the time of follow-up.

## Discussion

The results after THA in patients with osteonecrosis have not been as good as those in patients with primary osteoarthritis (Saito et al. 1989, Ortiguera et al. 1999). There have been a few reports regarding the long-term results of uncemented THAs in patients with osteonecrosis. Hartley et al. (2000) reported 10 revisions at a mean follow-up time of about 10 years in 39 patients (48 hips) who underwent THA using AML (anatomically medullary locking) prostheses for the treatment of osteonecrosis. Acetabular osteolysis occurred in 5 hips and femoral osteolysis in 6 hips of the 29 patients who did not have a reoperation. Kim et al. (1995) reported 15 femoral revisions and femoral osteolysis in 48 hips at a mean follow-up time of 7.2 years in 61 patients (78 hips) who underwent THA using PCA (porous coated anatomic) prostheses for the treatment of osteonecrosis. Xenakis et al. (2001) reported 4 revisions of the acetabular component at a mean follow-up time of 11 years (with a minimum of more than 10 years) in 28 patients (38 hips) who had undergone uncemented THA using PCA prostheses for the treatment of osteonecrosis. Half of the acetabular components had migrated, however.

Our study has shown better durability of the HGP-1 acetabular component compared with AML and PCA acetabular components in terms of lower prevalence of osteolysis and lower revision rate. Only 1 cup was revised because of aseptic loosening and 3 hips without a reoperation had pelvic osteolysis.

There have been many mid- and long-term follow-up reports indicating excellent durability of the HGP acetabular component and low prevalence of acetabular osteolysis in patients without osteonecrosis. Our results compare favorably with these studies of the HGP acetabular component

which have similar follow-up (Maloney et al. 1999, Crowther and Lachiewicz 2002). However, there have been a few long-term results of THA using the HGP femoral component in patients with or without osteonecrosis. Clohisy and Harris (1999) reported 19% femoral revision rate and 60% femoral osteolysis at a 10 year follow-up of HGP femoral component. Cruz-Pardos and Garcia-Cimbreno (2001) reported 2 unstable fixations and 1 femoral osteolysis at a mean follow-up of 10 years for HGP femoral component in 93 patients with primary osteoarthritis as the major diagnosis. Femoral problems were also high in our study. Thigh pain occurred in 7 hips, femoral osteolysis occurred in 18 hips without any reoperation, and femoral revision for any reason occurred in 9 hips. Today, the HGP-1 has been abandoned because of well-recognized flaws. The small proximal pads of the stem favored distal migration of the particle and subsequent development of distal femoral osteolysis, and poor femoral filling of the design resulted in the lower figures of bone ingrowth. The locking mechanism is weak (Gonzalez et al. 2001) and broken locking spikes may accelerate the polyethylene wear as a third-body mechanism (Orishimo et al. 2003).

Kim et al. (2003) have reported excellent durability in 50 hybrid THAs (Duraloc cup, Elite or Elite plus stem: Depuy, Leeds, UK) and 98 uncemented THAs (Duraloc cup: Depuy, Warsaw, IN, USA; Profile stem: Depuy, Leeds, England) in patients with femoral head necrosis at a mean follow-up time of 9 years. In this study, stems with 22-mm head (cemented stems with cobalt-chrome head and uncemented with zirconia head) were implanted in both groups, and cemented stems were implanted with the use of a third-generation cementing technique. There was no aseptic loosening. The annual wear averaged 0.22 mm in the group treated with cement and 0.14 mm in the group treated without cement. The prevalence of femoral osteolysis was 16% in the cemented group and 24% in the uncemented group. In contrast, Nich et al. (2003) reported long-term results of alumina-on-alumina cemented THAs (Ceraver, Osteal, Rossy, France) due to osteonecrosis in 52 hips (41 patients, mean age 41 years, follow-up 16 years).

16 alumina cups were revised, and the main cause of failure was aseptic loosening. No osteoly-

sis was observed and there was no wear. The survival rate was 89% for the socket and 100% for the stem after 10 years. Recently, the fixation problem is being solved and wear is reduced with the use of meta-on-metal or ceramic-on-ceramic articulation in THAs.

No competing interests declared.

- Brooker A F, Bowerman J W, Robinson R A, Riley L H, Jr. Ectopic ossification following total hip replacement. Incidence and a method of classification. *J Bone Joint Surg (Am)* 1973; 55: 1629-32.
- Clarke H J, Jinnah R H, Brooker A F, Michaelson J D. Total replacement of the hip for avascular necrosis in sickle cell disease. *J Bone Joint Surg (Br)* 1989; 71: 465-70.
- Clohisy J C, Harris W H. The Harris-Galante uncemented femoral component in primary total hip replacement at 10 years. *J Arthroplasty* 1999; 14: 915-7.
- Crowther J D, Lachiewicz P F. Survival and polyethylene wear of porous-coated acetabular components in patients less than fifty years old: results at nine to fourteen years. *J Bone Joint Surg (Am)* 2002; 84: 729-35.
- Cruz-Pardos A, Garcia-Cimbrelo E. The Harris-Galante total hip arthroplasty: a minimum 8-year follow-up study. *J Arthroplasty* 2001; 16: 586-97.
- D'Antonio J A, Capello W N, Manley M T, Feinberg J. Hydroxyapatite coated implants. Total hip arthroplasty in the young patient and patients with avascular necrosis. *Clin Orthop* 1997; (344): 124-38.
- DeLee J G, Charnley J. Radiological demarcation of cemented sockets in total hip replacement. *Clin Orthop* 1976; (121): 20-32.
- Engh C A, Massin P, Suthers K E. Roentgenographic assessment of the biologic fixation of porous-surfaced femoral components. *Clin Orthop* 1990; (257): 107-28.
- Ficat R P, Arlet J. Necrosis of the femoral head. In: *Ischemia and necrosis of bone* (ed Hungerford D S). Baltimore, Williams and Wilkins 1980: 53-74.
- Fye M A, Huo M H, Zatorski L E, Keggi K J. Total hip arthroplasty performed without cement in patients with femoral head osteonecrosis who are less than 50 years old. *J Arthroplasty* 1998; 13: 876-81.
- Gonzalez della Valle A, Ruzo P S, Li S, Pellicci P, Sculco TP, Salvati E A. Dislodgment of polyethylene liners in first and second-generation Harris-Galante acetabular components. A report of eighteen cases. *J Bone Joint Surg (Am)* 2001; 83: 553-9.
- Harris W H. Traumatic arthritis of the hip after dislocation and acetabular fractures: treatment by mold arthroplasty. An end-result study using a new method of result evaluation. *J Bone Joint Surg (Am)* 1969; 51: 737-55.
- Hartley W T, McAuley J P, Culpepper W J, Engh C A, Jr., Engh C A, Sr. Osteonecrosis of the femoral head treated with cementless total hip arthroplasty. *J Bone Joint Surg (Am)* 2000; 82: 1408-13.
- Isono S S, Woolson S T, Schurman D J. Total joint arthroplasty for steroid-induced osteonecrosis in cardiac transplant patients. *Clin Orthop* 1987; (217): 201-8.
- Kim Y H, Oh J H, Oh S H. Cementless total hip arthroplasty in patients with osteonecrosis of the femoral head. *Clin Orthop* 1995; (320): 73-84.
- Kim Y H, Oh S H, Kim J S, Koo K H. Contemporary total hip arthroplasty with and without cement in patients with osteonecrosis of the femoral head. *J Bone Joint Surg (Am)* 2003; 85: 675-81.
- Lins R E, Barnes B C, Callaghan J J, Mair S D, McCollum D E. Evaluation of uncemented total hip arthroplasty in patients with avascular necrosis of the femoral head. *Clin Orthop* 1993; (297): 168-73.
- Livermore J, Ilstrup D, Morrey B. Effect of femoral head size on wear of the polyethylene acetabular component. *J Bone Joint Surg (Am)* 1990; 72: 518-28.
- Maloney W J, Galante J O, Anderson M, Goldberg V, Harris W H, Jacobs J, Kraay M, Lachiewicz P, Rubash H E, Schutzer S, Woolson S T. Fixation, polyethylene wear, and pelvic osteolysis in primary total hip replacement. *Clin Orthop* 1999; (369): 157-64.
- Massin P, Schmidt L, Engh C A. Evaluation of cementless acetabular component migration. An experimental study. *J Arthroplasty* 1989; 4-3: 245-51.
- Nich C, Ali el H S, Hannouche D, Nizard R, Witvoet J, Sedel L, Bizot P. Long-term results of alumina-on-alumina hip arthroplasty for osteonecrosis. *Clin Orthop* 2003; (417): 102-11.
- Orishimo K F, Sychterz C J, Hopper R H Jr, Engh C A. Can component and patient factors account for the variance in wear rates among bilateral total hip arthroplasty patients. *J Arthroplasty* 2003; 18: 154-60.
- Ortiguera C J, Pulliam I T, Cabanela M E. Total hip arthroplasty for osteonecrosis: matched-pair analysis of 188 hips with long-term follow-up. *J Arthroplasty* 1999; 14: 21-8.
- Piston R W, Engh C A, De Carvalho P I, Suthers K. Osteonecrosis of the femoral head treated with total hip arthroplasty without cement. *J Bone Joint Surg (Am)* 1994; 76: 202-14.
- Saito S, Saito M, Nishina T, Ohzono K, Ono K. Long-term results of total hip arthroplasty for osteonecrosis of the femoral head. A comparison with osteoarthritis. *Clin Orthop* 1989; (244): 198-207.
- Senghas R E. Statistics in the Journal of Bone and Joint Surgery: suggestions for authors. *J Bone Joint Surg (Am)* 1992; 74: 319-20.
- Stulberg B N, Singer R, Goldner J, Stulberg J. Uncemented total hip arthroplasty in osteonecrosis: a 2- to 10-year evaluation. *Clin Orthop* 1997; (334): 116-23.
- Xenakis T A, Gelalis J, Koukoubis T A, Zaharis K C, Soucacos P N. Cementless hip arthroplasty in the treatment of patients with femoral head necrosis. *Clin Orthop* 2001; (386): 93-9.
- Zicat B, Engh C A, Gokcen E. Patterns of osteolysis around total hip components inserted with and without cement. *J Bone Joint Surg (Am)* 1995; 77: 432-9.